

Scoliosis and Uterine Torsion in a Pregnant Sea Otter (*Enhydra lutris*) from California

Authors: Rennie, Charles J., and Woodhouse, Charles D.

Source: Journal of Wildlife Diseases, 24(3) : 582-584

Published By: Wildlife Disease Association

URL: <https://doi.org/10.7589/0090-3558-24.3.582>

The BioOne Digital Library (<https://bioone.org/>) provides worldwide distribution for more than 580 journals and eBooks from BioOne's community of over 150 nonprofit societies, research institutions, and university presses in the biological, ecological, and environmental sciences. The BioOne Digital Library encompasses the flagship aggregation BioOne Complete (<https://bioone.org/subscribe>), the BioOne Complete Archive (<https://bioone.org/archive>), and the BioOne eBooks program offerings ESA eBook Collection (<https://bioone.org/esa-ebooks>) and CSIRO Publishing BioSelect Collection (<https://bioone.org/csiro-ebooks>).

Your use of this PDF, the BioOne Digital Library, and all posted and associated content indicates your acceptance of BioOne's Terms of Use, available at www.bioone.org/terms-of-use.

Usage of BioOne Digital Library content is strictly limited to personal, educational, and non-commercial use. Commercial inquiries or rights and permissions requests should be directed to the individual publisher as copyright holder.

BioOne is an innovative nonprofit that sees sustainable scholarly publishing as an inherently collaborative enterprise connecting authors, nonprofit publishers, academic institutions, research libraries, and research funders in the common goal of maximizing access to critical research.

Scoliosis and Uterine Torsion in a Pregnant Sea Otter (*Enhydra lutris*) from California

Charles J. Rennie III and Charles D. Woodhouse, Department of Vertebrate Zoology, Santa Barbara Museum of Natural History, 2559 Puesta del Sol Road, Santa Barbara, California 93105, USA

ABSTRACT: Scoliosis and uterine torsion are described in a pregnant adult sea otter (*Enhydra lutris*) tagged 3 yr prior to death. Apparently, severe scoliosis in sea otters can be compatible with good nutritional status and a life-span measured in years. No causal correlation of this condition with the animal's death was established.

Key words: Sea otter, *Enhydra lutris*, pathology, scoliosis, case history.

On 13 February 1983, a female sea otter (*Enhydra lutris*) was observed in distress on the beach at Port San Luis, San Luis Obispo County, California (35°10'N, 120°44'W). It was taken to nearby Morro Bay Aquarium (595 Embarcadero, Morro Bay, California 93442, USA) where it died the following day. The animal was frozen and transported to the Santa Barbara Museum of Natural History (2559 Puesta del Sol Road, Santa Barbara, California 93105, USA) for necropsy.

On 6 June 1978, the specimen was tagged at Cayucos Point, San Luis Obispo County, California (35°27'N, 120°57'W) by California Department of Fish and Game biologists. At the time of tagging, a major deformity that appeared to involve the spine was noted. The otter was observed thereafter on multiple occasions. When the specimen was found in distress, an ear tag allowed positive identification.

The carcass weighed 17.6 kg. Total length was 109 cm (straight line) or 113 cm (curvilinear). The animal appeared well nourished. Pelage was intact and no skin lesions were observed. Severe left lateral scoliosis was seen at the level of the mid-thoracic spine (Fig. 1). Spinal deviation was approximately 41 mm and extended from the 7th thoracic vertebra to the thoracolumbar junction. The angle of scoliosis was approximately 135°. The lower portion of the thoracic rib cage was likewise severely asymmetric. There was no evi-

dence of antecedent spinal or thoracic trauma. Paraspinous musculature was intact and well developed bilaterally.

The paraspinous musculature was dissected free of the intact vertebral column; no disc abnormalities were noted. After the sea otter was skeletonized, periartic-

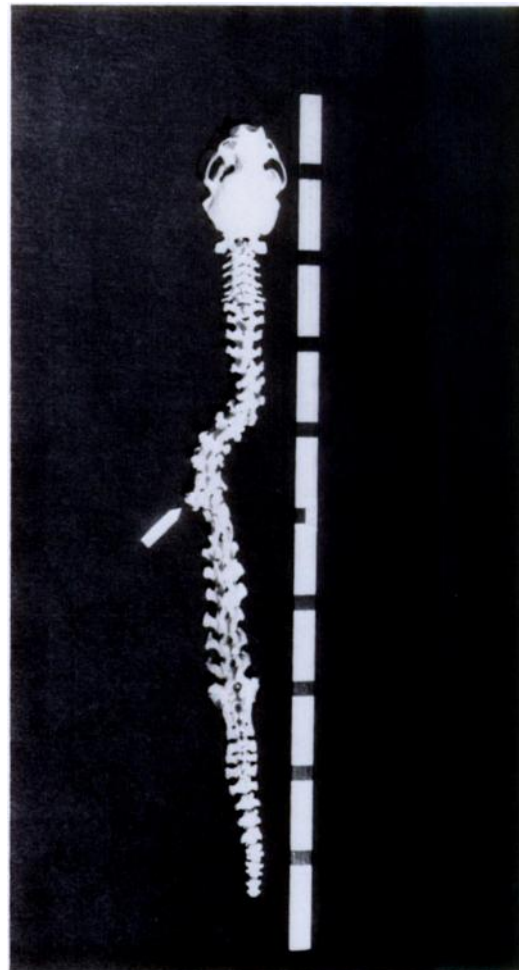


FIGURE 1. Rearticulated vertebral column of a sea otter showing left lateral deviation from T7 to the thoracolumbar junction. Arrow indicates pronounced exostoses fusing T12-T13. Scale marked in decimeters.

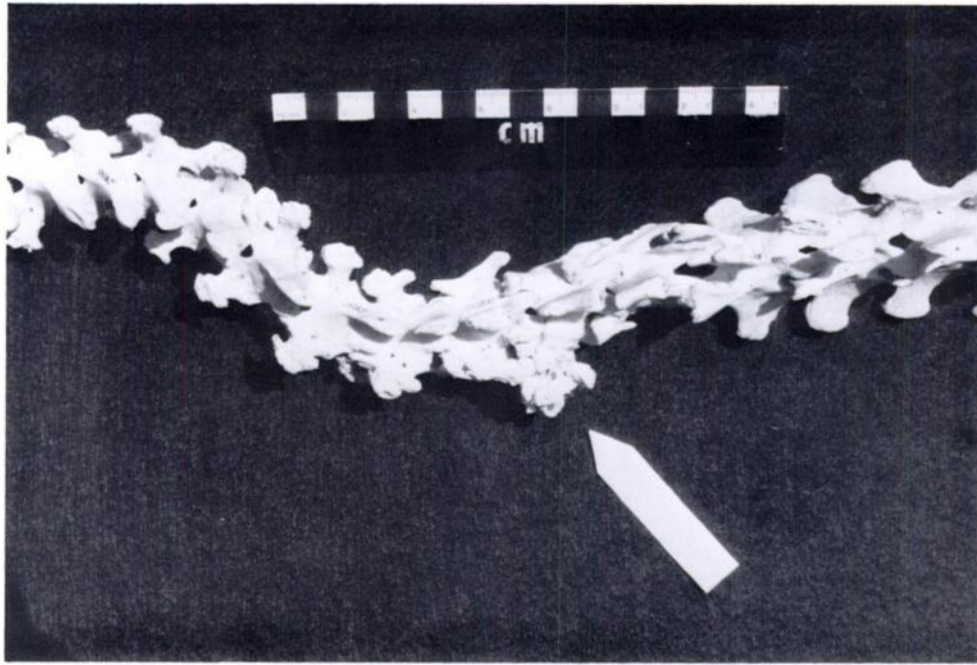


FIGURE 2. Detail of Figure 1 showing pronounced exostoses fusing T12–T13 on their left lateral surfaces (arrow).

ular periosteal exostoses were evident along the vertebral bodies. One ventro-lateral spur extended from the 10th thoracic vertebra to the 11th, but did not fuse with it. A pronounced exostosis fused the 12th and 13th thoracic vertebrae on their left lateral surfaces (Fig. 2).

The rib cage was asymmetric but otherwise grossly normal. The lungs were mildly atelectatic bilaterally, but without gross diffuse or focal pneumonitis. The gastrointestinal tract contained shell fragments and small numbers of helminths.

A 1.25 kg, 42.8 cm fetus was present within the uterus. Presentation was caudal. Attenuation and redundancy of the broad ligament were present, with torsion of the left uterine horn over the right horn. The uterus was without tears, vascular congestion or necrosis. There was no significant placental separation. A small amount of gross purulence (not vermix) surrounded the fetus in utero. The external appearance of the fetus was normal.

Scoliosis has been reported from a still-born sea otter whose mother was in cap-

tivity 6 yr (Giddens et al., 1984). The authors of that case report speculated that the scoliotic condition may have contributed significantly to the pup's death by complicating parturition.

The present sea otter is remarkable for two pathological features that have not been reported from necropsies of wild sea otters. The uterine torsion is apparently the first to be reported. Records made when the animal was tagged indicated severe scoliosis. Certainly, the condition was compatible with good nutritional status and a life span of years.

Scoliosis in vertebrates may be either congenital or acquired (Turek, 1984). In most models studied, congenital scoliosis is associated with a high incidence of both spinal and extra-spinal congenital defects including hemivertebrae, incomplete vertebral segmentation, supernumerary ribs or rib fusions (Keim, 1978). This animal exhibited no such defects. Acquired scoliosis may result from neurologic disease, environmental contamination or may be idiopathic (Cowell et al., 1972; Couch et

al., 1977; Keim, 1978). Available pathologic material does not permit differentiation between the etiologies in this case.

The fetus was near term or at term. Mean length and weight of four newborn male pups collected at Amchitka Island, Alaska are 1.75 kg and 55.25 cm, respectively (Kenyon, 1969). Caudal presentation of the fetus does not appear to be unusual in this marine mammal. Of a sample of 43 fetuses, Kenyon (1969) demonstrated nearly equal caudal to cephalic presentation.

Both specimens of these otters (female and fetus) are housed in the vertebrate zoology collections of the Santa Barbara Museum of Natural History. The adult's skeleton is catalogue number 2800 in the osteological collection. The fluid preserved fetus is number 83-62A.

We acknowledge the assistance of Robert Hardy, Frederick Wendell, and Jack

Ames of the California Department of Fish and Game for providing this specimen to the authors.

LITERATURE CITED

- COUCH, J. A., J. WINSTEAD, AND L. GOODMAN. 1977. Kepone induced scoliosis and its histological consequence in fish. *Science* 197: 585-587.
- COWELL, H. R., J. HALL, AND G. MACEWEN. 1972. Genetic aspects of idiopathic scoliosis. *Clinical Orthopedics* 86: 121-131.
- GIDDENS, W. E., M. RYLAND, AND C. J. CASSON. 1984. Idiopathic scoliosis in a newborn sea otter, *Enhydra lutris* (L.). *Journal of Wildlife Diseases* 20: 248-250.
- KEIM, H. 1978. Scoliosis. *CIBA Symposia* 30: 2-30.
- KENYON, K. W. 1969. The sea otter in the Eastern Pacific Ocean. U.S. Bureau of Sport Fisheries and Wildlife, North American Fauna, No. 68. Washington, D.C., 352 pp.
- TUREK, S. 1984. *Orthopedics*. J. B. Lippincott, Philadelphia, Pennsylvania, 765 pp.

Received for publication 14 July 1987.