



CRYPTOSPORIDIUM SPP. IN WILD AND CAPTIVE REPTILES

Authors: Upton, Steve J., McAllister, Chris T., Freed, Paul S., and Barnard, Susan M.

Source: Journal of Wildlife Diseases, 25(1) : 20-30

Published By: Wildlife Disease Association

URL: <https://doi.org/10.7589/0090-3558-25.1.20>

BioOne Complete (complete.BioOne.org) is a full-text database of 200 subscribed and open-access titles in the biological, ecological, and environmental sciences published by nonprofit societies, associations, museums, institutions, and presses.

Your use of this PDF, the BioOne Complete website, and all posted and associated content indicates your acceptance of BioOne's Terms of Use, available at www.bioone.org/terms-of-use.

Usage of BioOne Complete content is strictly limited to personal, educational, and non - commercial use. Commercial inquiries or rights and permissions requests should be directed to the individual publisher as copyright holder.

BioOne sees sustainable scholarly publishing as an inherently collaborative enterprise connecting authors, nonprofit publishers, academic institutions, research libraries, and research funders in the common goal of maximizing access to critical research.

CRYPTOSPORIDIUM SPP. IN WILD AND CAPTIVE REPTILES

Steve J. Upton,¹ Chris T. McAllister,² Paul S. Freed,³ and Susan M. Barnard⁴

¹ Division of Biology, Ackert Hall, Kansas State University, Manhattan, Kansas 66506, USA

² Department of Biological Sciences, University of North Texas, Denton, Texas 76203, USA

³ Department of Herpetology, Houston Zoological Gardens, 1513 Outer Belt Drive, Houston, Texas 77030, USA

⁴ Department of Herpetology, 800 Cherokee Avenue SE, Zoo Atlanta, Atlanta, Georgia 30315, USA

ABSTRACT: Between 1986 and 1988, 528 reptiles originating from three continents were examined for *Cryptosporidium* spp. Fifteen specimens representing eight genera and 11 species were infected. Statistical evaluation of oocyst structure suggests that multiple species of *Cryptosporidium* may exist among the reptiles examined.

Key words: *Cryptosporidium* spp., Cryptosporidiidae, Apicomplexa, coccidia, reptiles, snakes, turtles, lizards, prevalence, survey.

INTRODUCTION

Cryptosporidium spp. (Apicomplexa: Cryptosporidiidae) are small, 4–8 μm protozoa that infect the gastrointestinal and, occasionally, respiratory and biliary tract of a wide variety of vertebrates, including humans. In mammals, two distinct species of *Cryptosporidium* can be recognized. *Cryptosporidium muris*, the type species, was found originally to infect the gastric glands of laboratory mice (Tyzzer, 1907, 1910) and has since been reported in domestic cattle (Upton and Current, 1985; Anderson, 1987) and old world rats (*Rattus norvegicus*) (see Iseki, 1986; Uni et al., 1987). It is unknown whether this species is responsible for cases of gastric cryptosporidiosis in reptiles (see below), lower mammals (Yamini and Raju, 1986), or some immunosuppressed humans (Pitlik et al., 1983; Berk et al., 1984; Guarda et al., 1984; Garone et al., 1986; Soulen et al., 1986). Oocysts of *C. muris* measure 7.4×5.6 ($6.6\text{--}7.9 \times 5.3\text{--}6.5$) μm and have a shape index (length/width) of 1.3 (1.1–1.5) (Upton and Current, 1985).

Oocysts of *Cryptosporidium parvum* are small and more spherical than those of *C. muris*, measuring 5.0×4.5 ($4.5\text{--}5.4 \times 4.2\text{--}5.0$) μm and have a shape index of 1.1 (1.0–1.3) (Tyzzer, 1912; Upton and Current, 1985). This species primarily infects the ileum of mammals and appears to be the organism responsible for the majority of cases of cryptosporidiosis (for review see

Fayer and Unger, 1986). Although generally self-limiting, infection with *C. parvum* can become a life-threatening disease in immunoincompetent individuals.

In avian hosts, two of the named species of *Cryptosporidium* appear to be valid (see below), although the evidence suggests that the unnamed species infecting the small intestine of quail (*Colinus virginianus*) may also be a distinct species. *Cryptosporidium baileyi* infects the large intestine, cloaca, bursa and respiratory tract of domestic chickens (Current et al., 1986) and, to some extent, turkeys (Lindsay et al., 1987a, b) and ducks (Current et al., 1986). Oocysts are more elongate than the species found in mammals, measuring 6.2×4.6 ($6.3\text{--}5.6 \times 4.8\text{--}4.5$) μm and a shape index of 1.4 (1.2–1.4) (Current et al., 1986). Measurements of this species also have been reported to be 0.4–0.6 μm longer by Lindsay et al. (1986).

Cryptosporidium meleagridis infects the small intestine of domestic turkeys (*Meleagris gallopavo*) (Slavin, 1955). Its oocysts are smaller than those of *C. baileyi*, measuring 5.2×4.6 ($4.5\text{--}6.0 \times 4.2\text{--}5.3$) μm with a shape index of 1.13 (1.00–1.33) (D. S. Lindsay, pers. comm.). Moderate losses of poults have been attributed to the parasite (Slavin, 1955).

We are aware of only three reports of cryptosporidiosis in fish. Hoover et al. (1981) first reported the parasite from fish and gave the name *Cryptosporidium nasorum* for a member of the genus infecting

the intestinal tract of a naso tang (*Naso lituratus*) and a second, unnamed tropical fish. Pavlasek (1983) subsequently reported the genus from five of 35 *Cyprinus carpio* in Czechoslovakia, and Landsberg and Paperna (1986) described the ultrastructure of a *Cryptosporidium* sp. infecting the stomach of juvenile cichlids (hybrids of *Oreochromis aureus* and *O. niloticus*). Although it is unknown if these parasites represent the same species, the use of *C. nasorum* for the forms found in fish has been generally accepted until cross transmission studies can be performed (see Levine, 1984a, b; Fayer and Unger, 1986).

To our knowledge, no *Cryptosporidium* spp. have been reported in the Amphibia. Recently, we surveyed over 400 amphibians from Texas and Arkansas for coccidia, representing five genera and 12 species from Anura (Upton and McAllister, 1988) and two genera and four species from Caudata (Upton and McAllister, unpubl. data). In addition, 22 specimens representing six genera and eight species from Anura and one species from Caudata were sampled from the Ucayali district near Pucallpa, Peru (Upton and Freed, unpubl. data). Although we looked for *Cryptosporidium* spp., none were found. Further studies are certainly warranted; however, these data suggest that the prevalence of *Cryptosporidium* spp. in amphibians is probably low.

Early reports of *Cryptosporidium* spp. from reptiles have been dismissed as misidentifications of sporocysts of *Sarcocystis* spp. (see Upton and Current, 1985). *Cryptosporidium ameivae* nomen nudem described by Arcay de Peraza and Bastardo de San Jose (1969) probably represents oocysts of *Sarcocystis* sp., and *C. ctenosauris* described by Duszynski (1969), *C. lampropeltis* described by Anderson et al. (1968), and *C. crotali* described by Triffit (1925) are clearly so (see Levine and Tadros, 1980; Levine, 1984a, 1986; Upton and Current, 1985). The life cycle of the latter species was reported by Enzeroth et al. (1985) and the form described by Triffit

(1925) synonymized with it as *Sarcocystis crotali* by Enzeroth et al. (1985) (see Matuschka, 1987).

The first valid report of *Cryptosporidium* sp. in reptiles appears to be that of Brownstein et al. (1977) who reported infections in 14 snakes from three genera and four species. Clinical signs of infection included regurgitation and midbody swelling and pathologic changes included hypertrophic gastritis, atrophy of granular cells and focal mucosal necrosis. Levine (1980) assigned the name *Cryptosporidium serpentis* to these oocysts infecting the gastric mucosa of reptiles. Since that time, additional reports have shown the parasite to be a causative agent of gastritis in snakes (McKenzie et al., 1978; Szabo and Moore, 1984; Boylan et al., 1985; Godshalk et al., 1986; Heuschele et al., 1986), chameleons (Dillehay et al., 1986), and tortoises (Heuschele et al., 1986). The extent of clinical signs and pathology associated with cloacal infection of two of six geckos from Madagascar could not be determined by Upton and Barnard (1987). With the single exception of cloacal cryptosporidiosis in geckos, all previous reports suggest that the species of *Cryptosporidium* in reptiles infects the gastric mucosa and may represent a single species.

Between 1986 and 1988, we were able to examine oocysts of *Cryptosporidium* spp. from a variety of genera and species of reptiles from various localities on three continents. Although we were usually unable to examine hosts for the site of infection because many specimens were potential or existing zoo specimens, cursory measurements of oocysts suggested that more than one species of reptilian *Cryptosporidium* may be involved. Below is a summary of a morphologic and statistical study performed on the oocysts of nine of these isolates.

MATERIALS AND METHODS

Between March 1986 and August 1988, we examined feces or intestinal contents from 528 individual reptiles collected from three conti-

TABLE 1. Prevalence of *Cryptosporidium* spp. in reptiles collected from various geographic localities.

Geographic locality/host	Number infected/ number sampled (%)
Namibia, South West Africa ^a	
<i>Agama aculeata</i>	1/2 (50)
<i>Agama planiceps</i>	1/5 (20)
<i>Chamaeleo namaquensis</i>	0/4 (0)
<i>Chondrodactylus anguilifer</i>	1/4 (20)
<i>Cordylus polyzonus jordani</i>	0/1 (0)
<i>Cordylus polyzonus polyzonus</i>	0/1 (0)
<i>Cordylus subvittatus</i>	0/1 (0)
<i>Mabuya hoeschi</i>	0/2 (0)
<i>Pachydactylus bicolor</i>	0/3 (0)
<i>Psammophis jallae</i>	0/1 (0)
Republic of South Africa ^b	
<i>Cordylus niger</i>	0/1 (0)
Ucayali District near Pucallpa, Peru ^c	
<i>Anolis fuscoauratus</i>	0/5 (0)
<i>Anolis trachyderma</i>	0/11 (0)
<i>Chironius fuscus</i>	0/2 (0)
<i>Dipsas catesbyi</i>	0/3 (0)
<i>Enyaloides laticeps festae</i>	0/1 (0)
<i>Gonatodes humeralis</i>	0/3 (0)
<i>Imantodes cenchoa</i>	0/3 (0)
<i>Kentropyx altamazonica</i>	0/1 (0)
<i>Kentropyx pelviceps</i>	0/1 (0)
<i>Lepidoblepharis festae</i>	0/1 (0)
<i>Mabuya mabouya</i>	0/1 (0)
<i>Neusticurus ecleopus</i>	0/1 (0)
<i>Oxybelis argenteus</i>	0/3 (0)
<i>Prionodactylus argulus</i>	0/1 (0)
<i>Ptychoglossus brevifrontalis</i>	0/3 (0)
<i>Urocentron azureum</i>	0/1 (0)
<i>Xenopholis scalaris</i>	0/1 (0)
Madagascar ^d	
<i>Phelsuma madagascariensis grandis</i>	3/12 (25)
<i>Phelsuma laticauda</i>	0/5 (0)
Arkansas and Texas, USA ^e	
<i>Anolis carolinensis</i>	0/1 (0)
<i>Chelydra serpentina</i>	0/3 (0)
<i>Cnemidophorus gularis gularis</i>	0/14 (0)
<i>Coluber constrictor flaviventris</i>	0/7 (0)
<i>Cophosaurus texanus texanus</i>	0/23 (0)
<i>Crotalus atrox</i>	0/16 (0)
<i>Crotaphytus collaris collaris</i>	0/12 (0)
<i>Elaphe guttata emoryi</i>	0/9 (0)
<i>Elaphe obsoleta lindheimeri</i>	0/5 (0)
<i>Eumeces septentrionalis obtusirostris</i>	0/3 (0)
<i>Heterodon platyrhinos</i>	0/1 (0)
<i>Hypsiglena torquata jani</i>	0/1 (0)

TABLE 1. Continued.

Geographic locality/host	Number infected/ number sampled (%)
<i>Kinosternon flavescens</i>	
<i>flavescens</i>	0/6 (0)
<i>Lampropeltis calligaster</i>	
<i>calligaster</i>	0/1 (0)
<i>Lampropeltis getulus splendida</i>	0/1 (0)
<i>Leptotyphlops dulcis dulcis</i>	0/3 (0)
<i>Masticophis flagellum testaceus</i>	0/10 (0)
<i>Nerodia erythrogaster transversa</i>	0/20 (0)
<i>Nerodia harteri harteri</i>	1/1 (100)
<i>Nerodia rhombifera rhombifera</i>	1/17 (6)
<i>Opheodrys aestivus</i>	0/2 (0)
<i>Phrynosoma cornutum</i>	0/4 (0)
<i>Pituophis melanoleucus</i>	0/3 (0)
<i>Pseudemys texana</i>	0/7 (0)
<i>Salvadora grahamiae lineata</i>	0/4 (0)
<i>Sceloporus olivaceus</i>	0/5 (0)
<i>Sistrurus catenatus tergimimus</i>	0/1 (0)
<i>Sonora semiannulata</i>	0/35 (0)
<i>Terrapene carolina triunguis</i>	0/1 (0)
<i>Terrapene ornata ornata</i>	0/16 (0)
<i>Thamnophis proximus orarius</i>	0/1 (0)
<i>Thamnophis proximus proximus</i>	0/2 (0)
<i>Thamnophis proximus rubrilineatus</i>	0/14 (0)
<i>Thamnophis sirtalis annectans</i>	0/1 (0)
<i>Trachemys scripta elegans</i>	0/71 (0)
<i>Trionyx spiniferus pallidus</i>	0/1 (0)
<i>Tropidoclonion lineatum texanum</i>	0/12 (0)
<i>Virginia striatula</i>	0/13 (0)
Captive at Zoo Atlanta, Georgia, USA ^f	
<i>Agkistrodon contortrix contortrix</i>	0/1 (0)
<i>Crotalus adamanteus</i>	0/4 (0)
<i>Elaphe vulpina vulpina</i>	1/1 (100)
<i>Vipera palestinae</i>	0/4 (0)
Captive at Houston Zoo, Texas, USA ^g	
<i>Crotalus durissus culminatus</i>	1/1 (100)
<i>Lampropeltis triangulum arctifera</i>	1/2 (50)
<i>Elaphe obsoleta lindheimeri</i>	1/1 (100)
<i>Hemidactylus turcicus turcicus</i>	3/83 (4)

^a Collected in Namibia, South West Africa (25°38'S, 15°10'E) in June 1986 and returned to the Houston Zoological Gardens. Feces obtained between September 1986 and September 1987 (see Upton and Freed, 1988).

^b Table Mountain, Republic of South Africa (33°58'S, 18°25'E).
^c Collected from Peru (8°23'S, 74°32'W) between June and August 1987.

^d From an illegal shipment of animals imported into the United States from an unknown location in Madagascar (11°50'S to 25°31'S, 43°21'E to 50°28'E) in March 1986 (see Upton and Barnard, 1987).

^e 34°47'N to 32°15'N, 98°30'W to 91°53'W.

^f 33°44'N, 84°23'W.

^g 29°45'N, 95°21'W.

nents. Table 1 represents a list of the species examined, geographic localities where the animals were collected, and prevalence of *Cryptosporidium* spp. Feces or intestinal contents from all animals were placed into 2.5% (weight/volume) aqueous $K_2Cr_2O_7$, except for a few of the samples that were placed in 10% formalin. All samples were sent to Kansas State University (KSU; Manhattan, Kansas 66506, USA) where they were stored at 4 C until examined. Most samples were shipped within several days of collection, however, some were stored at 4 C for up to 2 mo prior to shipping. Samples collected in Peru were stored at environmental temperature for up to 1 mo prior to arrival at KSU. Samples were concentrated by centrifugation in a modified Sheather's sugar solution (sp. gr. 1.30) (Todd and Ernst, 1977) and examined, measured and photographed within 30 min of flotation using an Olympus BH-S photomicroscope equipped with a $\times 100$ SPlan objective, $\times 1.25$ optivar, Nomarski interference contrast optics and a calibrated ocular micrometer (Olympus Inc., Tokyo, Japan). Measurements only on those oocysts stored in 2.5% $K_2Cr_2O_7$ are reported and are expressed in micrometers (μm) as the mean of 30 oocysts, followed by the standard deviation of the mean and range in parentheses. Oocyst lengths and widths of the different isolates were compared statistically using the Wilcoxon Mann-Whitney *U*-test.

Because the walls of *Cryptosporidium* spp. in *Nerodia* spp. appeared to be thinner than all other isolates, we examined whether shrinkage during prolonged exposure to our sucrose solution is an important consideration in our study. Oocysts collected from *Nerodia harteri harteri* were measured under three separate conditions: (1) exposure to 2.5% $K_2Cr_2O_7$ only; (2) flotation in Sheather's sugar solution followed by measurements within 30 min; and (3) flotation followed by a 1 hr period prior to measuring. Oocyst lengths and widths were obtained on 30 specimens for each treatment and also compared using the Wilcoxon Mann-Whitney *U*-test.

RESULTS

Of 528 reptiles examined for cryptosporidiosis, only 15 (3%) specimens representing eight genera and 11 species were infected (Table 1): one of two *Agama aculeata* originally collected in Namibia, South West Africa; one of five *Agama planiceps* collected in Namibia; one of four *Chondrodactylus anguilifer* collected in Namibia; one of one *Crotalus durissus culminatus* born at the Houston Zoo (Texas,

USA); one of one *Elaphe obsoleta lindheimeri* housed at the Houston Zoo; one of one *Elaphe vulpina vulpina* housed at the Zoo Atlanta (Georgia, USA); three of 83 *Hemidactylus turcicus turcicus* collected in and around the Houston Zoo; one of two *Lampropeltis triangulum arcifera* housed at the Houston Zoo but originating from an unknown location in Mexico; one of one *Nerodia harteri harteri* collected from Palo Pinto County (Texas, USA; 32°50'N, 98°30'W); one of 17 *N. rhombifera rhombifera* collected in Denton County (Texas, USA; 33°15'N, 97°10'W); and three of 12 *Phelsuma madagascariensis grandis* from Madagascar.

Oocysts originating from *Agama aculeata* and *Chondrodactylus anguilifer* were, unfortunately, placed in formalin and were not measured. However, those from *A. aculeata* appeared similar to those from *A. planiceps* while oocysts recovered from *C. anguilifer* were obviously larger than specimens from *Agama* spp.

Table 2 represents the results of our measurements on nine of the isolates and Figures 1–9 are photomicrographs of oocysts of each isolate. Although visual evidence suggests only several morphologic types, statistical evaluation of the measurements suggests that oocysts can be placed into at least five separate groups. Oocysts recovered from *Agama planiceps* were both visually and statistically shorter in length ($P < 0.0005$) and width ($P < 0.01$ – 0.0005) from all other isolates and represent Group I. Group II oocysts were recovered from the terrestrial snakes *Crotalus* sp., *Elaphe obsoleta lindheimeri*, and *Lampropeltis* sp. Oocysts in this category are all larger in size than those in Group I and are smaller in length and/or width from oocysts recovered from gekkonids (*Hemidactylus* sp. and *Phelsuma* sp.), water snakes (*Nerodia* spp.), and the fox snake (*Elaphe vulpina vulpina*). Group III represents the next largest size category and, although some statistical variability seems to exist between oocyst widths, those recovered from *Phelsuma* sp. and *Hemi-*

TABLE 2. Measurements of oocysts of *Cryptosporidium* spp. isolated from reptiles.

Host	Geographic locality	Oocyst age (wk)	Oocyst size (μm) (SD) (range)	Shape index (length/width)	Diameter of residuum (μm)	Diameter of largest residual globule (μm)
Sauria						
Agamidae						
<i>Agama planiceps</i> "Damara rock agama"	Namibia, Africa	8	5.8 (0.32) \times 5.0 (0.30) ^a (5.2-6.4 \times 4.4-5.6)	1.15 (1.07-1.23)	2.1 (1.0-3.2)	1.4 (1.0-1.6)
Gekkonidae						
<i>Hemidactylus turcicus turcicus</i> "Mediterranean gecko"	Harris County, Texas	20	6.3 (0.32) \times 5.5 (0.23) ^b (5.6-7.0 \times 5.0-5.8)	1.14 (1.00-1.28)	2.9 (2.4-3.2)	1.2 (0.8-1.8)
<i>Phelesuma madagascariensis grandis</i> "Madagascar giant day gecko"	Madagascar	24	6.3 (0.27) \times 5.6 (0.23) ^c (5.6-6.8 \times 5.0-6.2)	1.13 (1.00-1.23)	3.2 (2.4-4.0)	1.4 (0.8-2.0)
Serpentes						
Colubridae						
<i>Elaphe obsoleta lindheimeri</i> "Texas rat snake"	Houston Zoo, Texas	8	6.2 (0.28) \times 5.3 (0.25) ^d (5.6-6.6 \times 4.8-5.8)	1.17 (1.04-1.29)	2.8 (2.4-3.2)	1.5 (1.0-1.8)
<i>Elaphe vulpina vulpina</i> "Western fox snake"	Zoo Atlanta, Georgia	36	8.0 (0.38) \times 5.6 (0.25) ^e (7.2-8.8 \times 5.0-6.2)	1.44 (1.29-1.69)	3.5 (2.4-4.2)	1.1 (0.8-1.6)
<i>Lampropeltis triangulum arctifera</i> "Jalisco milk snake"	Houston Zoo, Texas	20	6.2 (0.34) \times 5.3 (0.31) ^f (5.6-6.8 \times 4.8-5.6)	1.18 (1.07-1.38)	3.3 (2.6-4.0)	1.3 (0.8-1.8)
<i>Nerodia harteri harteri</i> "Brazos water snake"	Palo Pinto County, Texas	20	6.7 (0.31) \times 5.6 (0.23) ^g (6.4-7.2 \times 5.0-6.0)	1.20 (1.07-1.31)	3.9 (3.2-4.8)	1.1 (0.8-1.6)
<i>Nerodia rhombifera rhombifera</i> "Diamondback water snake"	Denton County, Texas	24	6.5 (0.23) \times 5.6 (0.20) ^h (5.8-7.0 \times 5.0-6.0)	1.16 (1.07-1.23)	3.3 (2.4-4.8)	1.6 (0.8-2.4)
Viperidae						
<i>Crotalus durissus culminatus</i> "Northwestern tropical rattlesnake"	Houston Zoo, Texas	16	6.1 (0.31) \times 5.3 (0.31) ⁱ (5.6-6.6 \times 4.8-5.6)	1.15 (1.00-1.33)	3.2 (2.6-4.0)	1.3 (0.6-2.4)

^a $P < 0.0005$ for lengths from all other isolates; $P < 0.01-0.0005$ for widths from all other isolates. Data not duplicated below.

^b For lengths, $P > 0.05$ when compared to isolates from *Phelesuma* sp., *Elaphe obsoleta* and *Lampropeltis* sp., $P < 0.025$ from *Crotalus* sp., and $P < 0.0005$ from *Nerodia* spp.; for widths, $P > 0.05$ from *Nerodia harteri*, $P < 0.05$ from *Crotalus* sp. and *Nerodia rhombifera*, $P < 0.25$ from *Phelesuma* sp., and $P < 0.01$ from *Elaphe obsoleta* and *Lampropeltis* sp.

^c For lengths, $P > 0.05$ from *Hemidactylus* sp., $P < 0.05$ from *Lampropeltis* sp., $P < 0.01$ from *Elaphe obsoleta* and *Nerodia rhombifera*, $P < 0.005$ from *Crotalus* sp., and $P < 0.0005$ from *Nerodia harteri*; for widths, $P > 0.05$ from *Nerodia* spp., $P < 0.25$ from *Hemidactylus* sp., and $P < 0.0005$ from *Crotalus* sp., *Elaphe obsoleta*, and *Lampropeltis* sp.

- ^a For lengths, $P > 0.05$ from *Lampropeltis* sp., *Crotalus* sp., and *Hemidactylus* sp., $P < 0.01$ from *Phelsuma* sp., and $P < 0.0005$ from *Nerodia* spp.; for widths, $P > 0.05$ from *Lampropeltis* sp. and *Crotalus* sp., $P < 0.01$ from *Hemidactylus* sp., and $P < 0.0005$ from *Phelsuma* sp. and *Nerodia* spp.
- ^b For lengths, $P < 0.0005$ from all other species. Data not duplicated under other footnotes.
- ^c For lengths, $P > 0.05$ for *Crotalus* sp., *Elaphe obsoleta*, and *Hemidactylus* sp., $P < 0.05$ from *Lampropeltis* sp., $P < 0.0005$ from *Nerodia* spp.; for width, $P > 0.05$ from *Crotalus* sp. and *Elaphe obsoleta*, $P < 0.01$ from *Hemidactylus* sp., and $P < 0.0005$ from *Phelsuma* sp. and *Nerodia* spp.
- ^d For lengths, $P < 0.025$ from *Nerodia rhombifera*, $P < 0.005$ from *Hemidactylus* sp., and $P < 0.0005$ from *Phelsuma* sp., *Crotalus* sp., *Elaphe obsoleta*, and *Lampropeltis* sp.; for widths, $P > 0.05$ from *Phelsuma* sp., *Hemidactylus* sp., and *Nerodia rhombifera*, $P < 0.005$ from *Crotalus* sp. and *Lampropeltis* sp., and $P < 0.0005$ from *Elaphe obsoleta*.
- ^e For lengths, $P < 0.025$ from *Nerodia harteri*, $P < 0.01$ from *Phelsuma* sp., $P < 0.005$ from *Hemidactylus* sp., and $P < 0.0005$ from *Crotalus* sp., *Elaphe obsoleta*, and *Lampropeltis* sp.; for widths, $P > 0.05$ from *Phelsuma* sp. and *Nerodia harteri*, $P < 0.05$ from *Hemidactylus* sp., $P < 0.0005$ from *Crotalus* sp., *Elaphe obsoleta*, and *Lampropeltis* sp.
- ^f For lengths, $P > 0.05$ from *Lampropeltis* sp. and *Elaphe obsoleta*, $P < 0.025$ from *Hemidactylus* sp., $P < 0.005$ from *Phelsuma* sp., and $P < 0.0005$ from *Nerodia* spp.; for widths, $P > 0.05$ from *Lampropeltis* sp. and *Elaphe obsoleta*, $P < 0.05$ from *Hemidactylus* sp., $P < 0.0005$ from *Phelsuma* sp. and *Nerodia* spp.

dactylus sp. appear similar. They are similar also in width to those recovered from water snakes. Oocysts in Group IV were found only in *Nerodia* spp. and are the second largest of the isolates. Although we noted oocysts of *N. harteri harteri* to be somewhat more elongate, both visually and statistically, than those of *N. rhombifera rhombifera*, we are reluctant to separate these until further samples can be recovered. Oocysts in Group V were recovered only from *Elaphe vulpina vulpina* and were much more elongate than all other isolates recovered ($P < 0.0005$), although width is similar to those found in water snakes.

Oocysts from *N. harteri harteri* were affected by prolonged exposure to sucrose solution. Oocysts exposed only to $K_2Cr_2O_7$ measured $6.8(0.35) \times 5.8(0.30)$ ($6.4-7.2 \times 5.6-6.6$); those immediately after flotation $6.7(0.31) \times 5.6(0.23)$ ($6.4-7.2 \times 5.0-6.0$); and those after remaining in Sheather's for 1 hr $6.5(0.19) \times 5.5(0.21)$ ($5.6-7.2 \times 4.8-5.8$). While the first and third methods were not significantly different from oocysts measured immediately after flotation, a comparison of methods one and three to each other revealed both lengths and widths to vary at $P < 0.05$.

DISCUSSION

Based on our interpretation of the statistical and visual results, it appears that more than one species of *Cryptosporidium* probably occurs in reptiles. However, until additional isolates can be examined, and sites of infection and life cycles established, we are reluctant to name any new species. For example, some oocyst variability may occur between different host species and more than one investigator has shown that oocyst size (but usually not shape index) may fluctuate significantly depending upon the time of patency (reviewed by Duszynski, 1971). It should be noted, however, that we observed that oocysts of *Cryptosporidium* spp. were shed over many months by most reptiles and it is possible that significant changes in oocyst

TABLE 3. Species of reptiles reported to be infected with *Cryptosporidium* sp.

Species	Site of infection	Clinical signs	Reference(s)
Sauria			
Agamidae			
<i>Agama aculeata</i> "Kalahari spiny agama"	unknown	none evident	this study
<i>Agama planiceps</i> "Damara rock agama"	unknown	none evident	this study
Chamaeleonidae			
<i>Chamaeleo senegalensis</i> "Senegal chameleon"	stomach	gastritis	Dillehay et al. (1986)
Gekkonidae			
<i>Chondrodactylus angulifer</i> "Sand gecko"	unknown	none evident	this study
<i>Hemidactylus t. turcicus</i> "Mediterranean gecko"	unknown	none evident	this study
<i>Phelsuma madagascariensis grandis</i> "Madagascar giant day gecko"	cloaca	unknown	Upton and Barnard (1987)
Testudines			
Testudinidae			
<i>Geochelone elegans</i> "Star tortoise"	stomach	gastritis	Heuschele et al. (1986)
Serpentes			
Boidae			
"Multicolored boa"	unknown	unknown	Szabo and Moore (1984)
<i>Sanzinia madagascariensis</i> "Madagascar tree boa"	stomach	gastritis	Brownstein et al. (1977)
Colubridae			
<i>Elaphe guttata guttata</i> "Corn snake"	stomach	gastritis	Boylan et al. (1985); Brownstein et al. (1977); Gillespie (1987)
<i>Elaphe obsoleta lindheimeri</i> "Texas rat snake"	unknown	none noted	this study
<i>Elaphe obsoleta obsoleta</i> "Black rat snake"	stomach	gastritis	Boylan et al. (1985); Brownstein et al. (1977)
<i>Elaphe subocularis</i> "Trans-Pecos rat snake"	stomach	gastritis	Brownstein et al. (1977); Gillespie (1987)
<i>Elaphe vulpina vulpina</i> "Western fox snake"	unknown	none noted	this study
<i>Lampropeltis triangulum arcifera</i> "Jalisco milk snake"	unknown	none noted	this study
<i>Nerodia harteri harteri</i> "Brazos water snake"	unknown	none noted	this study
<i>Nerodia rhombifera rhombifera</i> "Diamondback water snake"	unknown	none noted	this study
<i>Pituophis melanoleucus catenifer</i> "Pacific gopher snake"	stomach	gastritis	Godshalk et al. (1986)
Elapidae			
<i>Pseudechis porphyriacus</i> "Red-bellied black snake"	stomach	gastritis	McKenzie et al. (1978)
<i>Oxyuranus scutellatus</i> "Taipan"	unknown	unknown	Boylan et al. (1985)

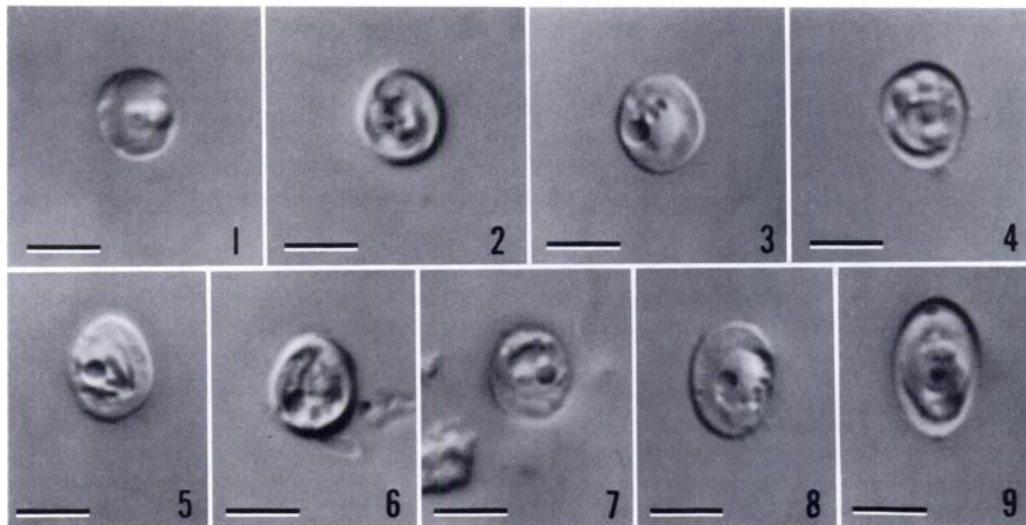
TABLE 3. Continued.

Species	Site of infection	Clinical signs	Reference(s)
Viperidae			
<i>Bitis gabonica</i> "Gaboon viper"	stomach	gastritis	Boylan et al. (1985)
<i>Crotalus durissus culminatus</i> "Northwestern tropical rattlesnake"	unknown	none noted	this study
<i>Crotalus horridus horridus</i> "Timber rattlesnake"	stomach	gastritis	Brownstein et al. (1977); Heuschele et al. (1986)

size may not occur with *Cryptosporidium* spp. Continual or prolonged shedding of *Cryptosporidium* spp. by snakes also has been observed previously by others (Brownstein et al., 1977; Boylan et al., 1985). Another reason for our reluctance to name new species is that although the wavelength of light allows for a 0.2 μm resolution, it is improbable that this resolution is actually achieved by most conventional light microscopy optics. Therefore, a certain amount of inherent variability exists in this study that prompts caution when interpreting the data.

The above data support several hypoth-

eses. First, oocysts recovered from *Agama* spp. are smaller than all other isolates and the measurements suggest that this is a separate species. The site of infection and effect of the parasite on the host remain to be determined. Second, oocysts found in *Crotalus* sp., *Elaphe obsoleta lindheimeri*, and *Lampropeltis* sp. are similar in size and probably represent a second distinct species. This is probably the same organism that infects the gastric mucosa of a variety of snakes, a chameleon, and a tortoise (see Table 3) and is a serious pathogen, responsible for regurgitation, gastritis and death of captive snakes (Brownstein



Figures 1–9. Nomarski interference contrast photomicrographs of oocysts of nine isolates of *Cryptosporidium* spp. from reptiles. Scale bars represent 4 μm . 1. From *Agama planiceps*. 2. From *Crotalus durissus culminatus*. 3. From *Elaphe obsoleta lindheimeri*. 4. From *Lampropeltis triangulum arcifera*. 5. From *Hemidactylus turcicus*. 6. From *Phelsuma madagascariensis grandis*. 7. From *Nerodia rhombifera rhombifera*. 8. From *N. harteri harteri*. 9. From *Elaphe vulpina vulpina*.

et al., 1977; McKenzie et al., 1978; Szabo and Moore, 1984; Boylan et al., 1985; Dillehay et al., 1986; Heuschele et al., 1986; Gillespie, 1987). Levine (1980) has named this organism *C. serpentis* and we believe that it is a valid species. Third, the oocysts infecting *Phelsuma* sp. and *Hemidactylus* sp. also may represent a separate species, based both on oocyst size and site of infection in *Phelsuma* sp. Although less elongate, these oocysts are similar to those of *C. baileyi*, the species responsible for losses in domestic chickens. The species in *Nerodia* spp. may represent a fourth species of *Cryptosporidium*, which is somewhat larger than most other isolates. Although it is possible that oocysts found in *N. harteri* and *N. rhombifera* are distinct species, additional specimens from each host species should be examined before reaching a definitive conclusion. Finally, the species in *E. vulpina vulpina*, obviously more elongate than any of the other isolates, probably represents a distinct species.

It appears important to measure oocysts of *Cryptosporidium* spp. from aquatic hosts relatively quickly following flotation. Although our sucrose solution did not significantly affect oocyst measurements immediately after flotation, prolonged exposure would probably have resulted in significant changes among some isolates. Therefore, all measurements used in Table 1 were based on ≤ 30 min exposure to the flotation medium.

ACKNOWLEDGMENTS

Animals from Namibia were collected under permit Number 39088P issued to PSF by the Department of Agriculture and Nature Conservation, Namibia (South-West Africa). Animals from Texas were collected under permit Number SPO44-1 issued to CTM by the Texas Parks and Wildlife Department. The expedition to Peru by PSF was financed, in part, by funds from the National Geographic Society Committee for Research and Exploration (Grant #3460-86) and by funds donated to the Louisiana State University Museum of Natural Science through the LSU Foundation. We also thank members of the Georges Creek Ranch for allowing CTM to collect reptiles on their properties.

LITERATURE CITED

- ANDERSON, B. C. 1987. Abomasal cryptosporidiosis in cattle. *Veterinary Pathology* 24: 235-238.
- ANDERSON, D. R., D. W. DUSZYNSKI, AND W. L. MARQUARDT. 1968. Three new coccidia (Protozoa: Telosporea) from kingsnakes, *Lampropeltis* spp., in Illinois, with a redescription of *Eimeria zamenis* Phisalix, 1921. *The Journal of Parasitology* 54: 577-581.
- ARCAY DE PERAZA, L., AND T. BASTARDO DE SAN JOSE. 1969. *Cryptosporidium ameivae* sp. nov. coccidia Cryptosporidiidae del intestino delgado de *Ameiva ameiva* de Venezuela. *Acta Cientifica Venezolana*. 20: 125.
- BERK, R. N., S. D. WALL, C. B. MCCARDLE, J. A. MCCUTCHAN, A. R. CLEMETT, J. S. ROSENBLUM, A. PREMKUMER, AND A. J. MEGIBOW. 1984. Cryptosporidiosis of the stomach and small intestine in patients with AIDS. *American Journal of Roentgenology* 143: 549-554.
- BOYLAN, T., M. CUNNINGHAM, AND G. REDDA CLIFF. 1985. Cryptosporidiosis in snakes at Taronga Zoo. *Thylacinus* 10: 20-21.
- BROWNSTEIN, D. G., J. D. STRANDBERG, R. J. MONTALL, M. BUSH, AND J. FORTNER. 1977. *Cryptosporidium* in snakes with hypertrophic gastritis. *Veterinary Pathology* 14: 606-617.
- CURRENT, W. L., S. J. UPTON, AND T. B. HAYNES. 1986. The life cycle of *Cryptosporidium baileyi* n. sp. (Apicomplexa, Cryptosporidiidae) infecting chickens. *Journal of Protozoology* 33: 289-296.
- DILLEHAY, D. L., T. R. BOOSINGER, AND S. MACKENZIE. 1986. Gastric cryptosporidiosis in a chameleon. *Journal of the American Veterinary Medical Association* 189: 1139-1140.
- DUSZYNSKI, D. W. 1969. Two new coccidia (Protozoa: Eimeriidae) from Costa Rican lizards with a review of the *Eimeria* from lizards. *Journal of Protozoology* 16: 581-585.
- . 1971. Increase in size of *Eimeria separata* oocysts during patency. *The Journal of Parasitology* 57: 948-952.
- ENZEROTH, R., B. CHOBOTAR, AND E. SCHOLTYSECK. 1985. *Sarcocystis crotali* sp. n. with the Mojave rattlesnake (*Crotalus scutulatus scutulatus*)-mouse (*Mus musculus*) cycle. *Archiv für Protistenkunde* 129: 19-23.
- FAYER, R., AND B. L. P. UNGER. 1986. *Cryptosporidium* spp. and cryptosporidiosis. *Microbiological Reviews* 50: 458-483.
- GARONE, M. A., B. J. WINSTON, AND J. H. LEWIS. 1986. Cryptosporidiosis of the stomach. *American Journal of Gastroenterology* 81: 465-470.
- GILLESPIE, D. 1987. Cryptosporidiosis in reptiles. *Current Veterinary Therapy* 9: 748-749.
- GODSHALK, C. P., D. M. MACCOY, J. S. PATTERSON, AND B. C. MCKIERNAN. 1986. Gastric hypertrophy associated with cryptosporidiosis in a

- snake. *Journal of the American Veterinary Medical Association* 189: 1126–1128.
- GUARDA, L. A., M. A. LUNA, J. L. SMITH, P. W. A. MANSELL, F. GYORKEY, AND A. N. ROCA. 1984. Acquired immune deficiency syndrome: Post-mortem findings. *American Journal of Clinical Pathology* 81: 549–557.
- HEUSCHELE, W. P., J. OOSTERHUIS, D. JANSSEN, P. T. ROBINSON, P. K. ENSLEY, J. E. MEIER, T. OLSON, M. P. ANDERSON, AND K. BENIRSCHKE. 1986. Cryptosporidial infections in captive wild animals. *Journal of Wildlife Diseases* 22: 493–496.
- HOOVER, D. M., F. J. HOERR, W. W. CARLTON, E. J. HINSMAN, AND H. W. FERGUSON. 1981. Enteric cryptosporidiosis in a naso tang, *Naso lituratus* Bloch and Schneider. *Journal of Fish Diseases* 4: 425–428.
- ISEKI, M. 1986. Two species of *Cryptosporidium* naturally infecting house rats, *Rattus norvegicus*. *Japanese Journal of Parasitology* 35: 521–526.
- LANDSBERG, J. H., AND I. PAPERNA. 1986. Ultrastructural study of the coccidian *Cryptosporidium* sp. from stomachs of juvenile cichlid fish. *Diseases of Aquatic Organisms* 2: 13–20.
- LEVINE, N. D. 1980. Some corrections of coccidian (Apicomplexa: Protozoa) nomenclature. *The Journal of Parasitology* 66: 830–834.
- . 1984a. Taxonomy and review of the coccidian genus *Cryptosporidium* (Protozoa, Apicomplexa). *Journal of Protozoology* 31: 94–98.
- . 1984b. The genera *Cryptosporidium* and *Epiimeria* in the coccidian family Cryptosporidiidae (Protozoa: Apicomplexa). *Transactions of the American Microscopical Society* 103: 205–206.
- . 1986. The taxonomy of *Sarcocystis* (Protozoa, Apicomplexa) species. *The Journal of Parasitology* 72: 372–382.
- , AND W. TADROS. 1980. Named species and hosts of *Sarcocystis* (Protozoa: Apicomplexa: Sarcocystidae). *Systematic Parasitology* 2: 41–59.
- LINDSAY, D. S., B. L. BLAGBURN, AND F. J. HOERR. 1987a. Experimentally induced infections in turkeys with *Cryptosporidium baileyi* isolated from chickens. *American Journal of Veterinary Research* 48: 104–108.
- , ———, ———, AND J. J. GIAMBRONE. 1987b. Experimental *Cryptosporidium baileyi* infections in chickens and turkeys produced by ocular inoculation of oocysts. *Avian Diseases* 31: 355–357.
- , ———, C. A. SUNDERMANN, F. J. HOERR, AND J. A. ERNEST. 1986. Experimental *Cryptosporidium* infections in chickens: Oocyst structure and tissue specificity. *American Journal of Veterinary Research* 47: 876–879.
- MATUSCHKA, F.-R. 1987. Reptiles as intermediate and/or final hosts for sarcosporidia. *Parasitology Research* 73: 22–32.
- MCKENZIE, R. A., P. E. GREEN, W. J. HARTLEY, AND C. C. POLLITT. 1978. *Cryptosporidium* in a red-bellied black snake (*Pseudechis porphyriacus*). *Australian Veterinary Journal* 54: 365.
- PAVLASEK, I. 1983. *Cryptosporidium* sp. in *Cyprinus carpio* Linne. 1758 in Czechoslovakia. *Folia Parasitologica* 30: 248.
- PITLIK, S. D., V. FAINSTEIN, D. GARZA, L. GUARDA, R. BOLIVAR, A. RIOS, R. L. HOPFER, AND P. A. MANSELL. 1983. Human cryptosporidiosis: Spectrum of disease. *Archives of Internal Medicine* 143: 2269–2275.
- SLAVIN, D. 1955. *Cryptosporidium meleagridis* (sp. nov.). *Journal of Comparative Pathology* 65: 262–266.
- SOULEN, M. C., E. K. FISHMAN, J. C. SCATARIGE, D. HUTCHINS, AND E. A. ZERHOUNI. 1986. Cryptosporidiosis of the gastric antrum: Detection using CT. *Radiology* 159: 705–706.
- SZABO, J. R., AND K. MOORE. 1984. Cryptosporidiosis in a snake. *Veterinary Medicine* 79: 96–98.
- TODD, K. S., AND J. V. ERNST. 1977. Coccidia of mammals except man. In *Parasitic protozoa*, Vol. 3, J. P. Krier (ed.). Academic Press, New York, New York, pp. 71–99.
- TRIFFIT, M. J. 1925. Observations on two new species of coccidia parasitic in snakes. *Protozoology* 1: 19–26.
- TYZZER, E. E. 1907. A sporozoan found in the peptic glands of the common mouse. *Proceedings of the Society for Experimental Biology and Medicine* 5: 12–13.
- . 1910. An extracellular coccidium, *Cryptosporidium muris* (gen. et sp. nov.), of the gastric glands of the common mouse. *Journal of Medical Research* 23: 487–510.
- . 1912. *Cryptosporidium parvum* (sp. nov.), a coccidium found in the small intestine of the common mouse. *Archiv für Protistenkunde* 26: 394–412.
- UNI, S., M. ISEKI, T. MAEKAWA, K. MORIYA, AND S. TAKADA. 1987. Ultrastructure of *Cryptosporidium muris* (strain RN 66) parasitizing the murine stomach. *Parasitology Research* 74: 123–132.
- UPTON, S. J., AND S. M. BARNARD. 1987. Two new species of coccidia (Apicomplexa: Eimeriidae) from Madagascar gekkonids. *Journal of Protozoology* 34: 452–454.
- , AND W. L. CURRENT. 1985. The species of *Cryptosporidium* (Apicomplexa: Cryptosporidiidae) infecting mammals. *The Journal of Parasitology* 71: 625–629.
- , AND P. S. FREED. 1988. Description of the oocysts of *Isospora pachydactyli* sp. nov. (Apicomplexa: Eimeriidae) from Bibron's gecko, *Pachydactylus bibroni* (Reptilia: Gekkonidae). *Canadian Journal of Zoology* 66: 597–598.

- , AND C. T. MCALLISTER. 1988. The coccidia (Apicomplexa: Eimeriidae) of Anura, with descriptions of four new species. *Canadian Journal of Zoology* 66: 1822–1830.
- YAMINI, B., AND N. R. RAJU. 1986. Gastroenteritis associated with a *Cryptosporidium* sp. in a chinchilla. *Journal of the American Veterinary Medical Association* 189: 1158–1159.
- Received for publication 6 June 1988.

ADDENDUM

While this manuscript was in press, we became aware of two additional articles pertinent to the introductory remarks in this paper. Pospischil et al. (1987, *The Veterinary Record* 121: 379–380) reported what appears to be *Cryptosporidium muris* from the abomasum of four mountain gazelles (*Gazella gazella cuvieri*) captive at the Munich Zoo (Federal Republic of Germany). The infections resulted in a wasting disease unreported previously in cattle. Rush et al. (1987, *The Lancet* 2(8559): 632–633) reported *Cryptosporidium* sp. from the intestinal contents of five brown trout (*Salmo trutta*) near Sheffield, United Kingdom.