



Fatal Lungworm Infection in an Opossum

Authors: Duncan, Robert B., Reinemeyer, Craig R., and Funk, Richard S.

Source: Journal of Wildlife Diseases, 25(2) : 266-269

Published By: Wildlife Disease Association

URL: <https://doi.org/10.7589/0090-3558-25.2.266>

BioOne Complete (complete.BioOne.org) is a full-text database of 200 subscribed and open-access titles in the biological, ecological, and environmental sciences published by nonprofit societies, associations, museums, institutions, and presses.

Your use of this PDF, the BioOne Complete website, and all posted and associated content indicates your acceptance of BioOne's Terms of Use, available at www.bioone.org/terms-of-use.

Usage of BioOne Complete content is strictly limited to personal, educational, and non - commercial use. Commercial inquiries or rights and permissions requests should be directed to the individual publisher as copyright holder.

BioOne sees sustainable scholarly publishing as an inherently collaborative enterprise connecting authors, nonprofit publishers, academic institutions, research libraries, and research funders in the common goal of maximizing access to critical research.

Fatal Lungworm Infection in an Opossum

Robert B. Duncan, Jr.,¹ Craig R. Reinemeyer,¹ and Richard S. Funk,² ¹ Department of Pathobiology; ² Department of Environmental Practice, University of Tennessee College of Veterinary Medicine, Knoxville, Tennessee 37901, USA

ABSTRACT: A 3-mo-old male, feral opossum (*Didelphis virginiana*) was presented to the University of Tennessee College of Veterinary Medicine (USA) for evaluation of prolonged dyspnea. The animal died shortly after examination and a necropsy was performed. The cause of death was attributed to a verminous pneumonia, associated with numerous intrabronchial and intrabronchiolar nematodes, subsequently identified as *Didelphostrongylus hayesi*.

Key words: *Didelphis virginiana*, *Didelphostrongylus hayesi*, lungworms, Metastrongyloidea, opossum, verminous pneumonia, case report.

A 3-mo-old male, wild-caught (Maryville, Blount County, Tennessee; 35°44'N, 83°59'W) opossum (*Didelphis virginiana*) was presented to the Veterinary Teaching Hospital, University of Tennessee (Knoxville, Tennessee 37901, USA) for evaluation of depression and dyspnea of 2 wk duration. For 1 wk prior to presentation, the opossum had been treated twice daily with amoxicillin (Beecham Laboratories, Bristol, Tennessee 37620, USA) with no clinical response.

Physical examination revealed cachexia (470 g), an elevated temperature of 36.5 C (normal 34.3 C) (Wallach and Boever, 1983), extreme bradycardia (heart rate 36; normal 120 to 240) (Wallach and Boever, 1983), and severe dyspnea. Respirations were labored, and heart sounds could not be heard because of the increased lung sounds.

The opossum was depressed and did not resist physical restraint; a jugular blood sample was taken for a hemogram. A complete blood count revealed leukopenia [total white blood count (WBC), 8,660/mm³; normal 14,000 to 22,900/mm³] (Mays and Loew, 1968; Timmons and Marques, 1969) and morphological changes in erythro-

cytes indicating a regenerative response (86 nucleated red cells/100 WBC, polychromasia, anisocytosis, schistocytosis and acanthocytosis).

The opossum expired shortly after the venipuncture, and the body was submitted for necropsy. At necropsy, the lungs were moderately firm and failed to collapse when the thorax was opened. The cranio-ventral lung lobes were consolidated and homogeneously greyish-red, and the remaining lung tissue was mottled red and yellow. Several black foci <1 mm in diameter were visible through the visceral pleura. Numerous nematodes, up to 18 mm in length, could be expressed from transected bronchi and bronchioles of all lung lobes. The nematodes subsequently were identified as *Didelphostrongylus hayesi*. The conspicuous digestive tracts of these worms accounted for the black foci. Representative specimens have been deposited in the U.S. National Parasite Collection (Beltsville, Maryland 20705, USA; accession number 80533).

Small white foci, approximately 1 mm in diameter, were present on the surface and in sections of the liver and kidneys. The spleen was firm, enlarged, and the cut surfaces were dark red. The stomach contained several nematodes (*Physaloptera* sp.); no associated mucosal changes were observed.

Specimens of lung, liver, kidney, spleen, bone marrow, heart, stomach and intestine were fixed in 10% buffered neutral formalin and sectioned for histopathology. Histopathological examination of the lungs revealed several cross sections of nematodes in expanded bronchi and bronchioles, and markedly hyperplastic bronchiolar epithelium (Fig. 1). The uteri of

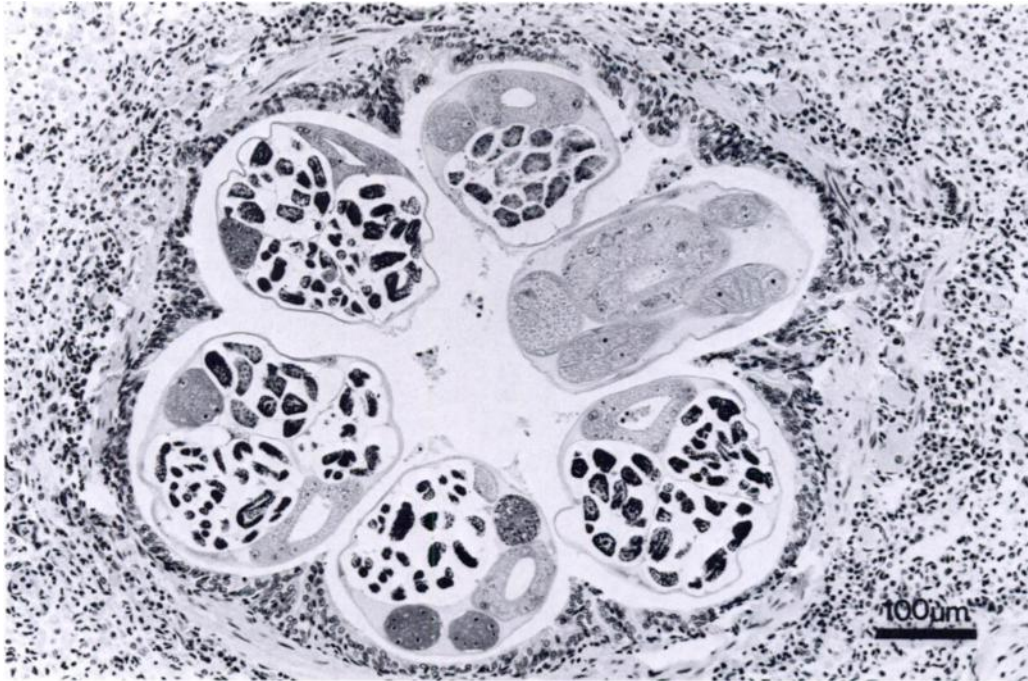


FIGURE 1. Lung of an opossum exhibiting cross sections of nematodes (*Didelphostrongylus hayesi*) in an expanded bronchiole, and marked epithelial hyperplasia. H&E stain.

many female nematodes were filled with embryonated ova. Free larvae also were observed within bronchioles and random alveoli. Severe granulomatous pneumonia was characterized by the accumulation of histiocytes, multinucleated giant cells, neutrophils, and eosinophils in the interstitium and alveoli (Fig. 2). Granulomatous inflammation was associated with necrotic adults in airways and with larvae in the peripheral lung, but live adult worms apparently evoked little inflammatory response.

The renal lesions were typical of embolic nephritis and were characterized by focal cortical necrosis and neutrophilic infiltrates. The liver exhibited multifocal, coalescing areas of coagulative necrosis with moderate infiltration of neutrophils. The spleen exhibited marked plasmacytosis, reticuloendothelial cell hyperplasia and extramedullary hematopoiesis. The bone marrow was hypercellular and contained many erythropoietic foci. No remarkable

histopathologic changes were noted in the stomach, heart or intestines.

The most significant pathologic findings were the obstruction of airways by adult nematodes, combined with the severe inflammatory changes associated with larvae in the peripheral lung. These pulmonary lesions easily accounted for protracted dyspnea that was unresponsive to antibacterial therapy. Although organisms could not be demonstrated in tissue sections, histopathologic changes in the liver and kidneys were attributed to secondary bacterial septicemia. Death resulted from severe granulomatous pneumonia due to an overwhelming lungworm infection.

A very active regenerative response was indicated by the altered red blood cell morphology and by the medullary and extramedullary hematopoiesis, and may have been due to chronic hypoxia associated with obstructed airways and granulomatous pneumonia. Nucleated red blood cells are not considered to be a normal com-

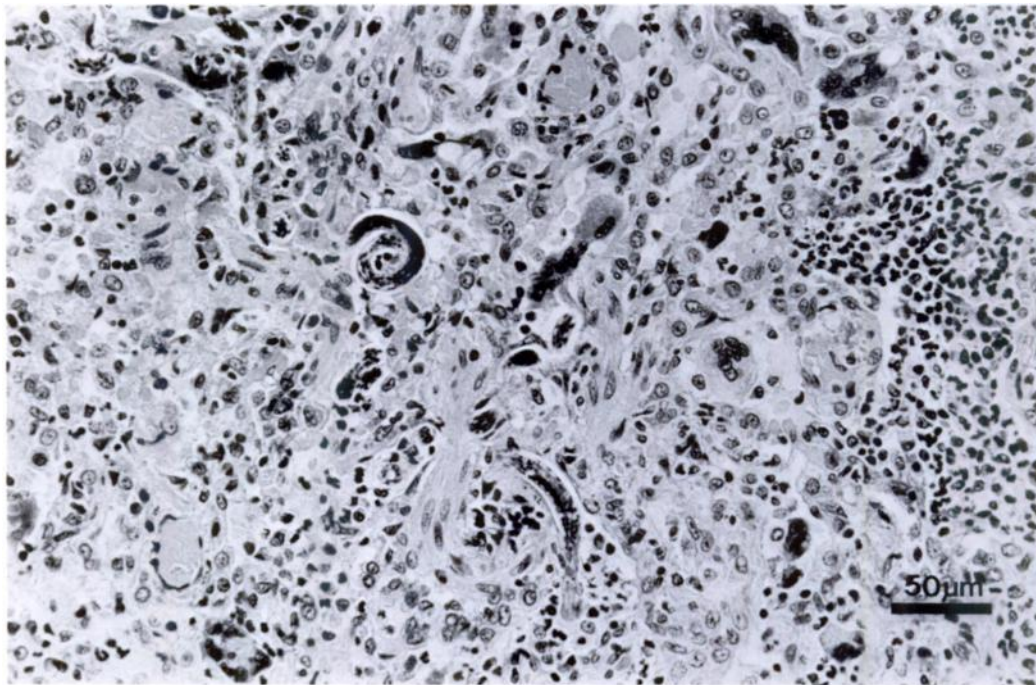


FIGURE 2. Lung of an opossum exhibiting sections of larvae (*Didelphostrongylus hayesi*) and interstitial and alveolar accumulation of histiocytes, multinucleated giant cells and neutrophils. H&E stain.

ponent of hemograms of laboratory-confined opossums (Mays and Loew, 1968; Timmons and Marques, 1969), but they have been reported in association with lungworm infections. Nucleated red cells were observed in the first opossum found infected with *D. hayesi* (Nettles et al., 1975), and cats infected with *Aelurostrongylus abstrusus* had significantly more nucleated red cells than uninfected cats (Willard et al., 1988). It is unknown whether the increased numbers of nucleated red blood cells in these animals resulted from hypoxia or from direct stimulus by the lungworms.

Didelphostrongylus hayesi is a metastrongyloid nematode that has been reported only in the opossum from the southeastern United States. The holotype was isolated from a debilitated opossum in Georgia (Nettles et al., 1975), and additional specimens were found in a second opossum from a nearby location (Prestwood, 1976). The opossum from which the

holotypes of *D. hayesi* were recovered also exhibited cachexia and an altered hemogram, but these were attributed to a concurrent *Physaloptera* sp. infection (Nettles et al., 1975). Although *Physaloptera* sp. was found in the present case, it was not associated with gross or histopathologic lesions.

Didelphostrongylus hayesi has an indirect life cycle typical of most metastrongyloid nematodes. Intermediate hosts include terrestrial snails of the genera *Triodopsis* and *Mesodon*; alternate routes of transmission are unknown. The prepatent period of *D. hayesi* is approximately 3 wk (Prestwood, 1976).

Opossums can be infected by at least two species of lungworms which are reported to occur in different anatomic locations. *Heterostrongylus heterostrongylus* occurs intrabronchially, and, prior to the present report, *D. hayesi* had been recovered exclusively from expanded alveoli (Prestwood, 1976), subpleural sites (Nettles

et al., 1975; Anderson et al., 1980), or respiratory bronchioles (Prestwood et al., 1977). The intrabronchial and intrabronchiolar location of *D. hayesi* (Fig. 1) is a previously unreported feature of this infection, as is the association with severe clinical signs and a fatal outcome.

The authors are grateful to R. C. Anderson, Guelph, Ontario for confirming the identification of specimens of *D. hayesi*.

LITERATURE CITED

- ANDERSON, R. C., M. D. LITTLE, AND U. R. STRELIVE. 1980. The unique lungworms (Nematoda: Metastrongyloidea) of the opossum (*Didelphis marsupialis* Linnaeus). *Systematic Parasitology* 2: 1-8.
- MAYS, A., AND F. M. LOEW. 1968. Hemograms of laboratory-confined opossums (*Didelphis virginiana*). *Journal of the American Veterinary Medical Association* 153: 800-802.
- NETTLES, V. F., A. K. PRESTWOOD, AND W. R. DAVIDSON. 1975. Severe parasitism in an opossum. *Journal of Wildlife Diseases* 11: 419-420.
- PRESTWOOD, A. K. 1976. *Didelphostrongylus hayesi* gen. et sp. n. (Metastrongyloidea: Filarioidea) from the opossum, *Didelphis marsupialis*. *The Journal of Parasitology* 62: 272-275.
- , V. F. NETTLES, AND R. L. FARRELL. 1977. Pathologic manifestations of experimentally and naturally acquired lungworm infections in opossums. *American Journal of Veterinary Research* 38: 529-532.
- TIMMONS, E. H., AND P. A. MARQUES. 1969. Blood chemical and hematological studies in the laboratory-confined, unanesthetized opossum, *Didelphis virginiana*. *Laboratory Animal Care* 19: 342-344.
- WALLACH, J. D., AND W. J. BOEVER. 1983. Diseases of exotic animals. Medical and surgical management. W. B. Saunders Co., Philadelphia, Pennsylvania, 1,159 pp.
- WILLARD, M. D., R. E. ROBERTS, N. ALLISON, R. B. GRIEVE, AND K. ESCHER. 1988. Diagnosis of *Aelurostrongylus abstrusus* and *Dirofilaria immitis* infections in cats from a humane shelter. *Journal of the American Veterinary Medical Association* 192: 913-916.

Received for publication 30 August 1988.