



Leukoencephalomalacia in a White-tailed Deer from North Carolina

Authors: Howerth, E. W., Wyatt, R. D., and Hayes, D. A.

Source: Journal of Wildlife Diseases, 25(3) : 384-387

Published By: Wildlife Disease Association

URL: <https://doi.org/10.7589/0090-3558-25.3.384>

BioOne Complete (complete.BioOne.org) is a full-text database of 200 subscribed and open-access titles in the biological, ecological, and environmental sciences published by nonprofit societies, associations, museums, institutions, and presses.

Your use of this PDF, the BioOne Complete website, and all posted and associated content indicates your acceptance of BioOne's Terms of Use, available at www.bioone.org/terms-of-use.

Usage of BioOne Complete content is strictly limited to personal, educational, and non - commercial use. Commercial inquiries or rights and permissions requests should be directed to the individual publisher as copyright holder.

BioOne sees sustainable scholarly publishing as an inherently collaborative enterprise connecting authors, nonprofit publishers, academic institutions, research libraries, and research funders in the common goal of maximizing access to critical research.

SHORT COMMUNICATIONS

Journal of Wildlife Diseases, 25(3), 1989, pp. 384-387
© Wildlife Disease Association 1989

Leukoencephalomalacia in a White-tailed Deer from North Carolina

E. W. Howerth,^{1,2} R. D. Wyatt,³ and D. A. Hayes⁴ ¹ Southeastern Cooperative Wildlife Disease Study, Department of Parasitology, College of Veterinary Medicine, The University of Georgia, Athens, Georgia 30602, USA; ² Present address: Louisiana Veterinary Medical Diagnostic Laboratory, School of Veterinary Medicine, Louisiana State University, Baton Rouge, Louisiana 70894, USA; ³ Department of Poultry Science, The University of Georgia, Athens, Georgia 30602, USA; ⁴ North Carolina Wildlife Resources Commission, 512 North Salisbury Street, Raleigh, North Carolina 27611, USA

ABSTRACT: Leukoencephalomalacia similar to equine leukoencephalomalacia occurred in a white-tailed deer (*Odocoileus virginianus*) from North Carolina. The deer was recumbent and stuporous when presented for examination. It was believed that the disease resulted from ingestion of moldy field corn, infected with *Fusarium moniliforme*.

Key words: White-tailed deer, *Odocoileus virginianus*, leukoencephalomalacia, *Fusarium moniliforme*, mycotoxin, nervous system disease, case history.

In early March 1985, a wildlife biologist was called to investigate an adult male white-tailed deer (*Odocoileus virginianus*) which was acting abnormally in Stony Fork Community, Wilkes County, North Carolina (USA; 36°12'N, 81°29'W). The deer was unafraid of humans and exhibited incoordination and constant twitching of the head and neck. The animal was captured and submitted to the Southeastern Cooperative Wildlife Disease Study (College of Veterinary Medicine, The University of Georgia, Athens, Georgia 30602, USA) for examination. On arrival, the deer was in sternal recumbency and stuporous, and there was trembling of the head. Blood was collected and the deer was euthanized (T-61® Euthanasia Solution, Hoechst-Roussel Agri-Vet Company, Somerville, New Jersey 08876, USA).

At necropsy, the deer was estimated to be 2.5-yr-old based on tooth replacement and wear (Severinghaus, 1949). The animal weighed 54.5 kg and was in poor con-

dition, with minimal body fat. The rumen was filled with green plant material and a small amount of corn. Gross lesions were confined to the brain and consisted of severe edema characterized by swelling and flattening of the gyri, narrowing of sulci and herniation of the cerebellum through the foramen magnum. Multiple petechial and ecchymotic hemorrhages were present in the white matter of the brain. These hemorrhages were bilateral but were most severe in the subcortical white matter of the two most dorsal cerebral gyri. A few hemorrhages were present in the mid-brain. Hemorrhages were most numerous on the left side, especially at the level of the internal capsule. Malacia and cavitation accompanied the hemorrhages in the subcortical white matter and were most severe on the left side at the level of the internal capsule (Fig. 1).

Hematologic values (red blood cell count $9.6 \times 10^6/\mu\text{l}$; white blood cell count 3,000/ μl with 78% neutrophils, 6% bands, 13% lymphocytes and 3% monocytes; packed cell volume 40%; total plasma protein 7.1 g/dl; and hemoglobin 16.2 g/dl) were within the normal ranges (Seal et al., 1981). A reagent strip (Multistix®, Ames Company, Box 70, Elkhart, Indiana 46515, USA) revealed no significant alterations in the urine. Aerobic culture of the brain yielded *Escherichia coli* and *Streptococcus salivarius*; these organisms were considered contaminants.

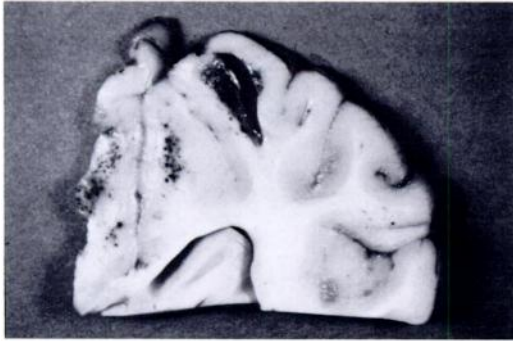


FIGURE 1. Cerebrum of white-tailed deer at level of internal capsule. Notice multiple hemorrhages, malacia and cavitation in subcortical white matter.

Histopathological examination of the cerebrum revealed rarefaction of the subcortical white matter, with multiple parenchymal and perivascular hemorrhages. In some rarefied areas marked disintegration and disruption of the neuropil resulted in large cavitations (Fig. 2). Rarefied white matter gradually changed to more normal white matter with mild gliosis. Diffuse areas with perivascular edema, satellitosis, neuronal necrosis and microcavitation were present in the overlying cortical gray matter. Endothelial hypertrophy and hyperplasia were present in these areas. A few blood vessels contained minimal numbers of eosinophils and mononuclear cells in their walls and in the perivascular space. Additional findings were centrilobular hepatic fatty change characterized by large lipid vacuoles in hepatocytes, and sinusoidal histiocytosis in lymph nodes.

A field inspection of the area in which the deer was found was conducted within 1 wk of necropsy. Local residents were unaware of anyone feeding grain to wildlife, and grain being fed to cattle and horses was fed in barns that would not normally be utilized by deer. There were no other reports of sick or dead animals in the area. Most of the fresh corn had been harvested during early winter, but three small fields of corn stubble containing some grain were located. Samples of corn from each of these sites were collected and examined for total

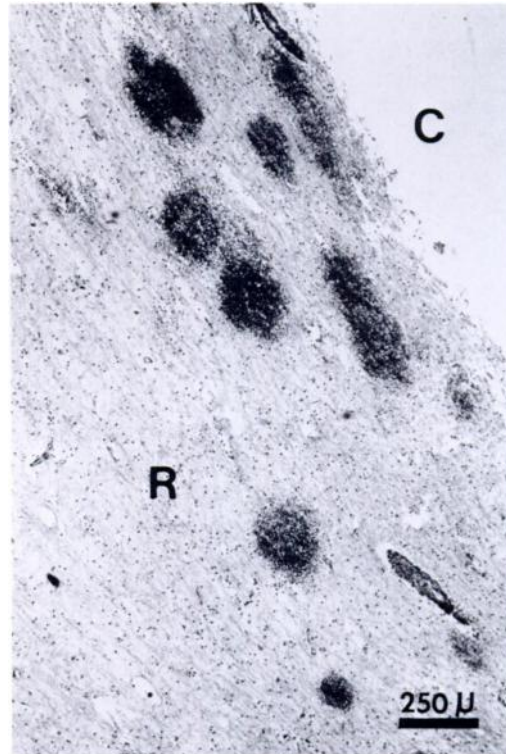


FIGURE 2. Cerebrum of white-tailed deer with cavitation (C), parenchymal and perivascular hemorrhages, and rarefaction (R) in the subcortical white matter. H&E.

mold spores, types of molds present and specific mycotoxin contamination.

All ears of corn had evidence of insect damage and were heavily infected with fungi (Fig. 3). Six ears of corn were shelled and examined separately. The total mold spore counts were determined by standard methodology (Jarvis, 1978) using 0.005% Triton X-100 in 0.85% saline as the diluent and Sabouraud dextrose agar containing 40 μ g chloramphenicol/ml as the culture medium. The total mold spore counts on these samples were high and ranged from 3.4×10^4 to 1.4×10^6 spores/g. Approximately 60% of the total molds isolated was *Fusarium* spp., including *F. moniliforme*, *F. graminearum* and an unidentified *Fusarium* sp. (Booth, 1971). Aflatoxin, zearalenone, T-2 toxin and deoxynivalenol concentrations were determined by thin layer chromatography in all samples of

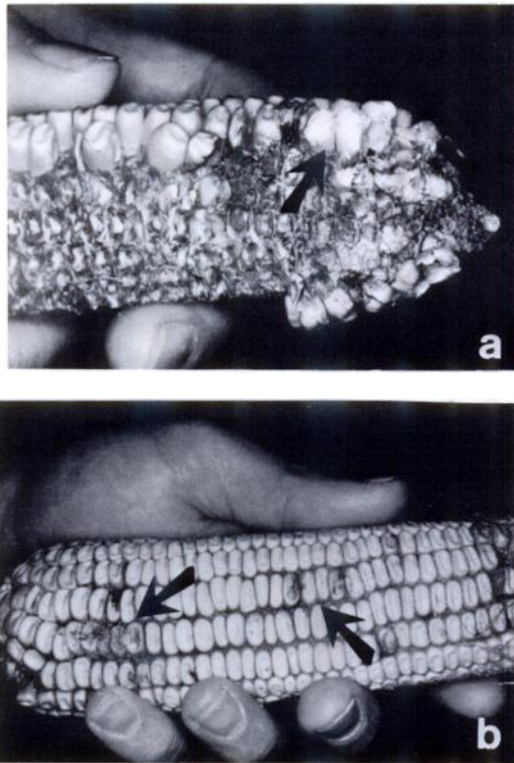


FIGURE 3. Ears of field corn; notice (a) evidence of insect damage (arrow), (b) moldy kernels (arrows).

corn (Scott et al., 1970; Pons et al., 1973; Vesonder et al., 1973; Eppley, 1975). Zearalenone levels were high in three cases (1,800 ppb, 3,600 ppb and 7,000 ppb). One ear, found to be contaminated with zearalenone, also had 60 to 80 ppb aflatoxin, but all other ears were negative for aflatoxins. Analysis for T-2 toxin and deoxynivalenol were negative.

The clinical, gross and histopathological findings in this deer were similar to those which have been reported in leukoencephalomalacia of horses and other Equidae (Buck et al., 1979; Haliburton et al., 1979). Equine encephalomalacia, also known as moldy corn disease, is seasonal in the United States, occurring from late fall through early spring (Buck et al., 1979). The natural disease is most often characterized by an acute and severe central nervous system disorder (Buck et al., 1979; Haliburton et al., 1979), but a hepatic syn-

drome manifested by icterus, systemic hemorrhage and edema has been reported in experimental trials (Kellerman et al., 1972; Marasas et al., 1976). The pathognomonic gross lesion of equine encephalomalacia is liquefactive necrosis in the subcortical white matter of the cerebral hemispheres (Buck et al., 1979; Haliburton et al., 1979; Marasas and Nelson, 1987). The pathogenesis of this lesion is unknown.

Equine leukoencephalomalacia is associated with the feeding of corn or commercial rations infected with the fungus, *Fusarium moniliforme* (Buck et al., 1979; Haliburton et al., 1979; Wilson et al., 1985). Insect damage, as seen in this case, is thought to enhance the growth of *F. moniliforme* on corn ears (Pienaar et al., 1981). The causative mycotoxin(s) has not been identified (Marasas and Nelson, 1987). A strictly comparable condition has not been authenticated in any species other than Equidae. Attempts to reproduce the characteristic brain lesion in other species, including sheep, goats, baboons, pigs, rats and monkeys, have been unsuccessful (Wilson et al., 1973; Kriek et al., 1981).

We postulate that leukoencephalomalacia in this deer was associated with the ingestion of moldy corn. Corn was present in the rumen of the deer, and field investigation revealed unharvested corn in a nearby field that contained *F. moniliforme*, the causative agent of equine leukoencephalomalacia. The corn was visibly moldy and *Fusarium* spp. were the predominant molds proliferating on the corn. Unfortunately, an adequate amount of corn was not collected to conduct a feeding trial to prove that the corn was toxic and could produce disease.

This study was supported by an appropriation from the Congress of the United States to the Southeastern Cooperative Wildlife Disease Study, Department of Parasitology, College of Veterinary Medicine, The University of Georgia. Funds were administered and research was coordinated under the Federal Aid to Wildlife Restoration Act (50 Stat. 917) and

through Contract Number 14-16-0004-85-007, Fish and Wildlife Service, U.S. Department of the Interior.

LITERATURE CITED

- BOOTH, C. 1971. The genus *Fusarium*. Commonwealth Mycological Institute. Kew, Surrey, England, 237 pp.
- BUCK, W. B., J. C. HALIBURTON, J. P. THILSTED, T. F. LOCK, AND R. F. VESONDER. 1979. Equine leukoencephalomalacia: Comparative pathology of naturally occurring and experimental cases. Proceedings American Association of Veterinary Laboratory Diagnosticians 22: 239-258.
- EPPLEY, R. M. 1975. Methods for the detection of trichothecenes. Journal of the Association of Official Analytical Chemists 58: 906-908.
- HALIBURTON, J. C., R. F. VESONDER, T. F. LOCK, AND W. B. BUCK. 1979. Equine leukoencephalomalacia (ELEM): A study of *Fusarium moniliforme* as an etiologic agent. Veterinary and Human Toxicology 21: 348-351.
- JARVIS, B. 1978. Methods for detecting fungi in foods and beverages. In Food and beverage mycology, L. R. Beuchat (ed.). A.V.I. Publishing Company, Inc., Westport, Connecticut, pp. 471-504.
- KELLERMAN, T. S., W. F. O. MARASAS, J. G. PIENAAR, AND T. W. NAUDE. 1972. A mycotoxicosis of Equidae caused by *Fusarium moniliforme* Sheldon. A preliminary communication. Onderstepoort Journal of Veterinary Research 39: 205-208.
- KRIEK, N. P. J., T. S. KELLERMAN, AND W. F. O. MARASAS. 1981. A comparative study of the toxicity of *Fusarium verticillioides* (= *F. moniliforme*) to horses, primates, pigs, sheep, and rats. Onderstepoort Journal of Veterinary Research 48: 129-131.
- MARASAS, W. F. O., T. S. KELLERMAN, J. G. PIENAAR, AND T. W. NAUDE. 1976. Leukoencephalomalacia: A mycotoxicosis of Equidae caused by *Fusarium moniliforme* Sheldon. Onderstepoort Journal of Veterinary Research 43: 113-122.
- , AND P. E. NELSON. 1987. Mycotoxicology. The Pennsylvania State University Press, University Park, Pennsylvania, 102 pp.
- PIENAAR, J. G., T. S. KELLERMAN, AND W. F. O. MARASAS. 1981. Field outbreaks of leukoencephalomalacia in horses consuming maize infected by *Fusarium verticillioides* in South Africa. Journal of the South African Veterinary Association 52: 21-24.
- PONS, W. A., A. F. CUCULLU, A. O. FRANZ, L. S. LEE, AND L. A. GOLDBLATT. 1973. Rapid detection of aflatoxin contamination in agricultural products. Journal of the Association of Official Analytical Chemists 56: 803-807.
- SCOTT, P. M., J. W. LAWRENCE, AND W. VAN WALLEBEEK. 1970. Detection of mycotoxins by thin-layer chromatography: Application to screening fungal extracts. Applied Microbiology 20: 839-842.
- SEAL, U. S., L. J. VERME, AND J. J. OZOGA. 1981. Physiologic values. In Diseases and parasites of white-tailed deer, W. R. Davidson, F. A. Hayes, V. F. Nettles, and F. E. Kellogg (eds.). Tall Timbers Research Station, Tallahassee, Florida, Miscellaneous Publication Number 7, pp. 17-34.
- SEVERINGHAUS, C. W. 1949. Tooth development and wear as criteria of age in white-tailed deer. The Journal of Wildlife Management 13: 195-216.
- VESONDER, R. F., A. CIEGLER, AND A. H. JENSEN. 1973. Isolation of the emetic principle from *Fusarium*-infected corn. Applied Microbiology 26: 1008-1010.
- WILSON, B. J., R. R. MARONPOT, AND P. K. HILDEBRANDT. 1973. Equine leukoencephalomalacia. Journal of the American Veterinary Medical Association 163: 1293-1295.
- WILSON, T. M., P. E. NELSON, T. B. RYAN, C. D. ROUSE, C. W. PITTMAN, T. P. NEAL, M. L. PORTFIELD, AND G. K. SAUNDERS. 1985. Linking leukoencephalomalacia to commercial horse rations. Veterinary Medicine 80: 63-64, 66, 68-69.

Received for publication 17 August 1988.