

## **Larval Nematodes (*Ascarops* sp.) in Stomach Granulomas of the Sagebrush Lizard, *Sceloporus graciosus***

Authors: Goldberg, Stephen R., and Bursey, Charles R.

Source: Journal of Wildlife Diseases, 25(4) : 630-633

Published By: Wildlife Disease Association

URL: <https://doi.org/10.7589/0090-3558-25.4.630>

---

BioOne Complete ([complete.BioOne.org](https://complete.BioOne.org)) is a full-text database of 200 subscribed and open-access titles in the biological, ecological, and environmental sciences published by nonprofit societies, associations, museums, institutions, and presses.

Your use of this PDF, the BioOne Complete website, and all posted and associated content indicates your acceptance of BioOne's Terms of Use, available at [www.bioone.org/terms-of-use](http://www.bioone.org/terms-of-use).

Usage of BioOne Complete content is strictly limited to personal, educational, and non - commercial use. Commercial inquiries or rights and permissions requests should be directed to the individual publisher as copyright holder.

---

BioOne sees sustainable scholarly publishing as an inherently collaborative enterprise connecting authors, nonprofit publishers, academic institutions, research libraries, and research funders in the common goal of maximizing access to critical research.

## Larval Nematodes (*Ascarops* sp.) in Stomach Granulomas of the Sagebrush Lizard, *Sceloporus graciosus*

Stephen R. Goldberg<sup>1</sup> and Charles R. Bursey,<sup>2</sup> <sup>1</sup> Department of Biology, Whittier College, Whittier, California 90608, USA; <sup>2</sup> Department of Biology, Pennsylvania State University, Shenango Valley Campus, Sharon, Pennsylvania 16146, USA

**ABSTRACT:** Wild populations of the sagebrush lizard (*Sceloporus graciosus*) are reported as paratenic hosts for third stage larvae of *Ascarops* sp. Larvae were found in stomach submucosal granulomas which averaged 350  $\mu$ m in diameter and consisted of histiocytes and layers of fibrocytes. Prevalence of infection was 16% (27 of 170 infected); mean intensity was 3 (1 to 8 nematodes/host). Prevalence was significantly higher in male than female lizards.

**Key words:** Larval nematode, *Ascarops* sp., *Sceloporus graciosus*, sagebrush lizard, granuloma, stomach, pathology.

Animals from all vertebrate classes can be paratenic hosts, especially those that habitually feed on insects (Alicata, 1935; Olsen, 1974). Unfortunately, most of the information about paratenic hosts is limited to a discussion of occurrence. The purpose of this note is to report, for the first time, the occurrence of larvae of the nematode *Ascarops* sp. (Spirurida, Spirocercidae) in the sagebrush lizard (*Sceloporus graciosus*, Iguanidae). Data on prevalence and histopathology of lesions associated with the infection also are described.

One hundred seventy adult sagebrush lizards were collected by noosing during May 1988 on the Windy Gap Trail (elevation 1,889 m; 34°21'N, 117°48'W) in the Crystal Lake area of the San Gabriel Mountains, Los Angeles County, California. Infected stomachs were fixed in neutral buffered 10% formalin, embedded in paraffin, sectioned at 5  $\mu$ m and stained with hematoxylin and eosin. Individual nematode larvae were dissected from formalin fixed granulomas and mounted in Hoyer's solution for taxonomic identification. A specimen was deposited in the U.S. National Parasite Collection (Beltsville, Maryland 20705, USA; accession number 80564). In addition, livers of 86

adult sagebrush lizards collected in 1986 and 36 adults from the 1987 and 1988 samples were examined for the presence of larval *Ascarops* sp.

At necropsy, granulomas containing encysted nematode larvae were grossly visible as whitish nodules embedded in the stomach wall. The granulomas (Fig. 1) were thin-walled and consisted of fibrocytes and histiocytes. They were approximately 350  $\mu$ m in diameter and were located in the stomach submucosa. An inflammatory response was not seen. Occasional masses of cellular debris, cells with pyknotic nuclei, histiocytes with foamy cytoplasm and heterophils were observed within the granulomas. Some, presumably older, granulomas were undergoing mineralization.

Each granuloma contained a third stage *Ascarops* sp. Larvae were approximately 1.9 mm long and 80  $\mu$ m wide. The distinguishing differential features of the third stage larva of *Ascarops* sp. are (1) the right and left anterolateral body walls are prolonged into dorsoventral liplike projections and (2) the tip of the tail possesses a smooth knoblike process. We observed both features in larvae taken from stomach granulomas of sagebrush lizards. Fourth stage larvae or mature worms were not found.

Prevalence of *Ascarops* sp. larvae was 16% (27 infected of 170 hosts examined). Mean intensity was 2.9 (1 to 8 nematodes/host). There was a significant difference in prevalence between males and females (21 of 91 and 6 of 79, respectively;  $\chi^2 = 7.9$ , 1 df,  $P < 0.001$ ). Mean intensity for males was 3.3 (1 to 8); it was 2.3 (1 to 4) for females. We found no externally visible characteristics that would allow detection of living lizards with granulomas.

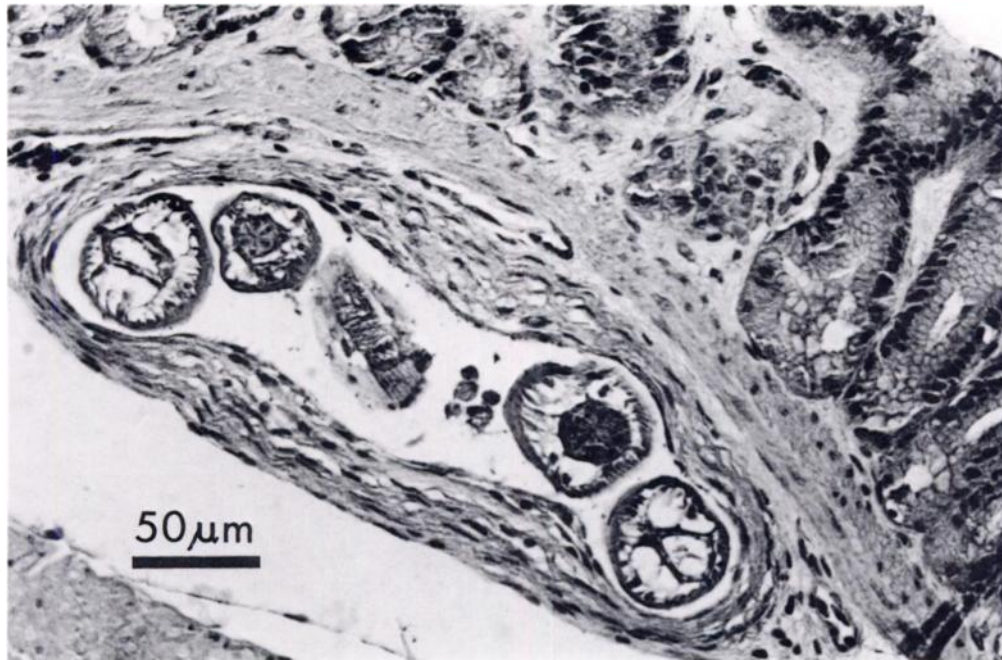


FIGURE 1. Larval *Ascarops* sp. within a granuloma in the submucosa of a sagebrush lizard. H&E.

Two of the 86 lizards collected in 1986 had larval *Ascarops* sp. in liver granulomas (prevalence of 2%, one granuloma in each of two livers). Liver granulomas were not found in sagebrush lizards collected in 1987 or 1988. Liver granulomas containing *Ascarops* sp. have been observed in the western fence lizard (*Sceloporus occidentalis*)

where prevalence may reach 37% (Goldberg and Bursey, 1988). It is not known why larval *Ascarops* sp. establish in the stomach wall of sagebrush lizards, but only rarely invade the liver.

Seven species of North American vertebrates have previously been reported as paratenic hosts of *Ascarops* sp. (Table 1).

TABLE 1. Paratenic hosts of *Ascarops* sp.

Species	Location in host	Collection site	Reference
Reptilia: Squamata			
<i>Sceloporus graciosus</i>	stomach wall	California	This study
<i>Sceloporus occidentalis</i>	liver	California	Goldberg and Bursey, 1988
Aves: Passeriformes			
<i>Cyanocitta cristata</i>	gastrointestinal wall	Alabama	Krahwinkel and McCue, 1967
<i>Richmondia cardinalis</i>	gastrointestinal wall	Alabama	Krahwinkel and McCue, 1967
<i>Pipilo erythrophthalmus</i>	gastrointestinal wall	Alabama	Krahwinkel and McCue, 1967
<i>Molothrus ater</i>	gastrointestinal wall	Alabama	Krahwinkel and McCue, 1967
Mammalia: Chiroptera			
<i>Lasiurus borealis</i>	stomach wall and mesentery	Washington, D.C.	Alicata and McIntosh, 1933
Mammalia: Edentata			
<i>Dasypus novemcinctus</i>	mesentery and cecal wall	Texas	Chandler, 1946

TABLE 2. North American beetle intermediate hosts of *Ascarops* sp.

Species	Reference
<i>Anomala flavipennis</i>	Fincher et al., 1969
<i>Aphodius granarius</i>	Alicata, 1935
<i>Aphodius lividus</i>	Porter, 1939; Stewart and Kent, 1963; Fincher et al., 1969
<i>Ateuchus lecontei</i>	Fincher, 1979
<i>Boreocanthon depressipennis</i>	Fincher, 1979
<i>Canthon chalcites</i>	Fincher, 1979
<i>Canthon pilularius</i>	Stewart and Kent, 1963
<i>Continus nitida</i>	Stewart and Kent, 1963; Fincher et al., 1969
<i>Copris minutus</i>	Stewart and Kent, 1963; Fincher et al., 1969
<i>Deltochilum gibbosum</i>	Fincher, 1979; Fincher and Marti, 1982
<i>Dyscinetus morator</i>	Fincher et al., 1969
<i>Hybosorus illigeri</i>	Fincher et al., 1969
<i>Onthophagus gazella</i>	Fincher and Marti, 1982
<i>Onthophagus hecate</i>	Stewart and Kent, 1963; Fincher et al., 1969; Fincher, 1979
<i>Onthophagus oklahomensis</i>	Fincher, 1979
<i>Onthophagus pennsylvanicus</i>	Stewart and Kent, 1963; Fincher, 1979; Fincher and Marti, 1982
<i>Onthophagus taurus</i>	Fincher and Marti, 1982
<i>Phanaeus vindex</i>	Stewart and Kent, 1963; Fincher et al., 1969
<i>Phyllophaga ephilida</i>	Fincher et al., 1969
<i>Trox suberosus</i>	Stewart and Kent, 1963; Fincher et al., 1969

These insectivorous vertebrates presumably acquire *Ascarops* sp. through their diets. Within the insect intermediate host, first stage larvae are enclosed in thin-walled cysts and development to third stage takes place within the cyst (Olsen, 1974). In a paratenic host, a freed third stage larva migrates through the stomach wall and re-encysts. No further development of the larval nematode occurs; although, normal development could resume should a paratenic host be eaten by a proper definitive host. Larvae have been found to survive as long as 1 yr in mice (Olsen, 1974), but survival time in the sagebrush lizard is not known.

About 20 species from 14 genera of beetles have been identified as intermediate hosts of *Ascarops* sp. (Table 2). The introduction of exotic species of dung beetles to the United States has increased the number of potential intermediate and paratenic hosts. Exotic beetles have become widespread since the initial releases in Texas in 1972 (Blume and Aga, 1978) and can now be found throughout most of Texas and in Louisiana (Fincher and Marti, 1982). Ex-

otic dung beetles are also established in California (Anderson and Loomis, 1978). The specific insect host of *Ascarops* sp. eaten by the sagebrush lizard has not been determined.

We thank H. J. Holshuh (Comparative Medical and Veterinary Services, County of Los Angeles) for discussions on histopathology. T. A. Bienz assisted with fieldwork.

#### LITERATURE CITED

- ALICATA, J. E. 1935. Early developmental stages of nematodes occurring in swine. U.S. Department of Agriculture Technical Bulletin No. 489, Washington, D.C., 96 pp.
- , AND A. MCINTOSH. 1933. *Ascarops strongylina* (Rudolphi, 1819), the correct name for *Arduenna strongylina* (Rudolphi, 1819) Railliet and Henry, 1911, and *Ascarops minuta* Beneden, 1873. *The Journal of Parasitology* 20: 62.
- ANDERSON, J. R., AND E. C. LOOMIS. 1978. Exotic dung beetles in pasture and range land ecosystems. *California Agriculture* 32: 31-32.
- BLUME, R. R., AND A. AGA. 1978. *Onthophagus gazella*: Progress of experimental releases in south Texas. *Folia Entomologica Mexicana* 39, 40: 190-191.
- CHANDLER, A. C. 1946. Helminths of armadillos,

- Dasytus novemcinctus*, in eastern Texas. The Journal of Parasitology 32: 237-241.
- FINCHER, G. T. 1979. Dung beetles of Ossabaw Island, Georgia. Journal of the Georgia Entomological Society 14: 330-334.
- , AND O. G. MARTI. 1982. *Onthophagus gazella* as an intermediate host for spiruroids in Georgia and Texas. The Southwestern Entomologist 7: 125-129.
- , T. B. STEWART, AND R. DAVIS. 1969. Beetle intermediate hosts for swine spirurids in southern Georgia. The Journal of Parasitology 55: 355-358.
- GOLDBERG, S. R., AND C. R. BURSEY. 1988. Larval nematodes (*Ascarops* sp., Spirurida, Spirocercidae) in liver granulomata of the western fence lizard, *Sceloporus occidentalis* (Iguanidae). Journal of Wildlife Diseases 24: 568-571.
- KRAHWINKEL, D. J., AND J. F. MCCUE. 1967. Wild birds as transport hosts of *Spirocerca lupi* in the southeastern United States. The Journal of Parasitology 53: 650-651.
- OLSEN, O. W. 1974. Animal parasites: Their life cycles and ecology. University Park Press, Baltimore, Maryland, 562 pp.
- PORTER, D. A. 1939. Some new intermediate hosts of the swine stomach worms, *Ascarops strongylina* and *Physocephalus sexalatus*. Proceedings of the Helminthological Society of Washington 6: 79-80.
- STEWART, T. B., AND K. M. KENT. 1963. Beetles serving as intermediate hosts of swine nematodes in southern Georgia. The Journal of Parasitology 49: 158-159.

Received for publication 13 February 1989.