

OCCURRENCE AND SEASONAL TRANSMISSION OF HEMATOZOA IN WILD TURKEYS

Authors: Stacey, L. M., Couvillion, C. E., Siefker, C., and HURST, G. A.

Source: Journal of Wildlife Diseases, 26(4) : 442-446

Published By: Wildlife Disease Association

URL: <https://doi.org/10.7589/0090-3558-26.4.442>

The BioOne Digital Library (<https://bioone.org/>) provides worldwide distribution for more than 580 journals and eBooks from BioOne's community of over 150 nonprofit societies, research institutions, and university presses in the biological, ecological, and environmental sciences. The BioOne Digital Library encompasses the flagship aggregation BioOne Complete (<https://bioone.org/subscribe>), the BioOne Complete Archive (<https://bioone.org/archive>), and the BioOne eBooks program offerings ESA eBook Collection (<https://bioone.org/esa-ebooks>) and CSIRO Publishing BioSelect Collection (<https://bioone.org/csiro-ebooks>).

Your use of this PDF, the BioOne Digital Library, and all posted and associated content indicates your acceptance of BioOne's Terms of Use, available at www.bioone.org/terms-of-use.

Usage of BioOne Digital Library content is strictly limited to personal, educational, and non-commercial use. Commercial inquiries or rights and permissions requests should be directed to the individual publisher as copyright holder.

BioOne is an innovative nonprofit that sees sustainable scholarly publishing as an inherently collaborative enterprise connecting authors, nonprofit publishers, academic institutions, research libraries, and research funders in the common goal of maximizing access to critical research.

OCCURRENCE AND SEASONAL TRANSMISSION OF HEMATOZOA IN WILD TURKEYS

L. M. Stacey,¹ C. E. Couvillion,² C. Siefker,² and G. A. Hurst¹

¹ Department of Wildlife and Fisheries, Mississippi State University,
Mississippi State, Mississippi 39762, USA

² College of Veterinary Medicine, Mississippi State University,
Mississippi State, Mississippi 39762, USA

ABSTRACT: The occurrence and seasonal patterns of transmission of the blood protozoa of wild turkeys (*Meleagris gallopavo silvestris*) were studied at Tallahala Wildlife Management Area (TWMA) (Jasper County, Mississippi, USA). Blood smears obtained from wild turkeys in winter, spring and summer, and from sentinel domestic turkeys throughout the year were examined for *Haemoproteus meleagridis* and *Leucocytozoon smithi*. Whole blood from wild turkeys captured in summer was subinoculated into malaria-free domestic turkey poults and recipient birds were examined for *Plasmodium* spp. The prevalence of *H. meleagridis* and *L. smithi* were not different ($P > 0.05$) between adults and juveniles or between male and female turkeys in any season. *Leucocytozoon smithi* was not detected in poults in summer or in juveniles examined in winter. Sentinel studies and information from wild birds revealed that transmission of *H. meleagridis* and *L. smithi* did not overlap. *Haemoproteus meleagridis* was transmitted from May through November, while *L. smithi* was transmitted only from January through April. The onset of transmission of *H. meleagridis* coincided with peak hatching (mid-May) and brood-rearing (May–November) of turkey poults. *Plasmodium* spp. were not found in turkeys from TWMA ($n = 27$) nor in birds from three widely separated counties ($n = 28$) in Mississippi.

Key words: Avian hematozoa, blood protozoa, *Haemoproteus meleagridis*, *Leucocytozoon smithi*, *Meleagris gallopavo*, *Plasmodium* spp., wild turkey, pattern of transmission.

INTRODUCTION

Three species of hematozoans (*Haemoproteus meleagridis*, *Leucocytozoon smithi*, and *Plasmodium* spp.) are recognized from wild turkeys (*Meleagris gallopavo silvestris*) in the United States (Eve et al., 1972a; Forrester et al., 1974; Telford and Forrester, 1975; Castle et al., 1988; Christensen et al., 1983). These species are hyperendemic in most adult wild turkey populations (Cook et al., 1966; Eve et al., 1972b; Forrester et al., 1974). Although there is only a single case of disease ostensibly due to *H. meleagridis* reported in adult wild turkeys (Atkinson and Forrester, 1987), all three of these species occur in young wild turkeys (Goggans, 1966; Eve et al., 1972a, b; Forrester et al., 1974) and both *P. hermani* (Forrester et al., 1980) and *H. meleagridis* (Atkinson et al., 1988b) are pathogenic in laboratory infected 1-wk-old domestic turkey poults. These organisms could affect productivity of wild turkey populations if transmission occurs to poults. Despite the numerous reports of

hematozoa in wild turkeys, there is little or no information on transmission, and the potential for disease in poults is unknown. This study was conducted to determine the occurrence and seasonal patterns of transmission of hematozoa in central Mississippi.

MATERIALS AND METHODS

The study was conducted at Tallahala Wildlife Management Area (TWMA) (32°12'N, 89°12'W) which consists of 14,140 ha in the Strong River District, Bienville National Forest and is located 56 km west of Meridian, Mississippi (USA). Blood samples were examined from wild turkeys trapped during winter (January to March) and summer (July to August) from 1985 through 1988, and from spring harvested males brought by hunters to a central checking station. For *Plasmodium* spp., whole blood was obtained from wild turkeys trapped in July and August 1987. At least 1.0 ml was subinoculated intravenously or intraperitoneally into malaria-free domestic turkey poults (1 to 2-wk-old broad-breasted white; Thaxton's Turkeys, Inc., Watkinsville, Georgia 30677, USA); blood smears from recipients were examined three times weekly for 5 wk after subinoculation (Forrester

et al., 1974). At the time of trapping or harvest, wild turkeys were classed as juveniles or adults based on plumage characteristics (Williams, 1981). Birds captured in their first summer after hatching were classed as poults. Chi-square analysis was used to determine if there were differences in the prevalence of infection with *H. meleagridis* and *L. smithi* between ages, sexes, and seasons.

Malaria-free domestic turkey poults (2-wk-old broad-breasted white) were used as sentinels to determine seasonal patterns of transmission of *H. meleagridis* and *L. smithi*. At regular intervals, sentinels were delivered to the study area and placed in cages (91 cm width × 91 cm length × 60 cm height) covered with wire mesh (1 cm × 1 cm) and which allowed access by biting flies. Following exposure periods of 7 to 14 days, sentinels were moved to insect-proof quarters. Three times weekly for 4 wk following the return of the sentinels from the field, a single blood smear from each bird was examined for hematozoa. Blood smears were stained with Wright's stain and on each smear at least 10,000 red blood cells were examined. Representative specimens of *H. meleagridis* and *L. smithi* are deposited in the U.S. National Parasite collection (Beltsville, Maryland 20705, USA; Accession numbers 81133–35), and in the International Reference Centre for Avian Hematozoa (St. John's, Newfoundland, Canada A1C5S7; Accession numbers 108,753a & b and 108,754–57).

During 1987, sentinel birds were exposed in five locations (three birds/cage) for 14 consecutive days each month from 15 July through 6 November 1987 (four exposure periods). In 1988–1989, sentinels were placed at a single site in two cages (three birds/cage), that were suspended 10 m and 1 m above ground, respectively. Birds were exposed for seven consecutive days every 2 wk from 5 April 1988 through 13 April 1989 (18 exposure periods). In 1987 the gap between the end of one exposure period and the beginning of the subsequent exposure period was about 21 days, but in 1988–1989 this gap was 14 days.

RESULTS

One hundred eighty wild turkeys captured on TWMA during winters of 1985 and 1988 ($n = 68$) and summers of 1985 through 1988 ($n = 112$) were examined for *H. meleagridis* and *L. smithi*. In addition, 24 male turkeys harvested during the spring (19 March to 1 May) 1988 turkey season were examined (Table 1).

Comparisons of the prevalence of *H. meleagridis* and *L. smithi* were made among three seasons (winter, spring and summer) for male turkeys and between two seasons (winter and summer) for females. Of the 204 birds that were examined, 172 (84%) were infected with *H. meleagridis* (Table 1). There was no significant difference ($P > 0.05$) in the prevalence of *H. meleagridis* between juvenile and adult or between male and female turkeys during any season. In winter and summer, there was no significant difference ($P > 0.05$) in the prevalence of *H. meleagridis* between juveniles and adults or between males and females. Spring prevalence was not significantly different ($P > 0.05$) between juvenile and adult male turkeys. In male turkeys the prevalence of infection with *H. meleagridis* was significantly greater ($P \leq 0.05$) in spring than in winter. For females the prevalence of infection was significantly greater in summer than in winter ($P \leq 0.05$).

For *L. smithi* the overall prevalence of infected birds was 33%. There was no significant difference ($P < 0.05$) in the prevalence of *L. smithi* between juvenile and adult or between male and female wild turkeys during any season. Winter and summer prevalences of *L. smithi* were not significantly different ($P > 0.05$) between juveniles and adults or between males and females. There was no significant difference ($P > 0.05$) in the spring prevalence between juvenile and adult male turkeys. Prevalence of *L. smithi* in males was significantly greater ($P \leq 0.05$) in spring and in summer than in winter. In females, summer prevalence of *L. smithi* was greater ($P \leq 0.05$) than winter prevalence. *Leucocytozoon smithi* was not detected in poults ($n = 51$) examined in summer. In winter, juvenile birds were not infected with *L. smithi*; however, only eight birds were examined. All juvenile males harvested in spring 1988 were infected with *L. smithi* (Table 1).

Based on sentinel studies in 1987, *H. meleagridis* was found in all five locations

TABLE 1. Numbers of wild turkeys examined and prevalence* of infection with *Haemoproteus meleagridis* and *Leucocytozoon smithi* on Tallahala Wildlife Management Area (Mississippi, USA), 1985–1988.

	Winter				Spring				Summer			
	Num- ber exam- ined	H ^b	L ^c	HL ^d	Num- ber exam- ined	H	L	HL	Num- ber exam- ined	H	L	HL
Poult	0	NA ^e	NA	NA	0	NA	NA	NA	51	100	0	0
Juvenile												
Female	4	50 ^h	0 ⁱ	0	0	NA	NA	NA	9	89 ^M	67 ^S	55
Male	4	50 ^h	0 ⁱ	0	6	100 ^M	100 ^S	100	18	94 ^M	61 ^S	61
Subtotal	8	50	0	0	6	100	100	100	27	92	63	59
Adult												
Female	35	57 ^h	17 ⁱ	3	0	NA	NA	NA	26	81 ^M	38 ^S	31
Male	25	80 ^h	20 ⁱ	20	18	100 ^M	100 ^S	100	8	87 ^M	62 ^S	50
Subtotal	60	67	18	10	18	100	100	100	34	82	44	35
Total	68	63	16	9	24	100	100	100	112	93	29	25

* Prevalences in a column or row followed by the same superscript are not significantly different ($P > 0.05$); superscripts, H and M, pertain to *H. meleagridis* only whereas superscripts L and S, pertain to *L. smithi* only.

^b H = *Haemoproteus meleagridis*.

^c L = *Leucocytozoon smithi*.

^d H&L = *Haemoproteus meleagridis* and *Leucocytozoon smithi*.

^e NA = not applicable.

during each exposure period from 15 July through 6 November. The prevalence of infection of sentinel birds was greatest in August (92%) and lowest in October and November (45%). In 1988–1989, sentinels were infected (40 to 100%) with *H. meleagridis* during all exposure periods from May through November; however, none of the sentinels exposed from December 1988 through April 1989 were infected.

None of the sentinel birds exposed from

July through November 1987 were infected with *L. smithi*. All of the sentinels exposed from 5 to 12 April 1988 were infected. Infections were not detected in any of the birds exposed from May through December 1988, but *L. smithi* was detected in birds exposed from January through March 1989. Transmission of both *H. meleagridis* and *L. smithi* were similar in sentinels located at the 1 and 10 m levels of the forest canopy. None of the 27 birds examined for *Plasmodium* spp. were infected 5 wk after subinoculation (Fig. 1).

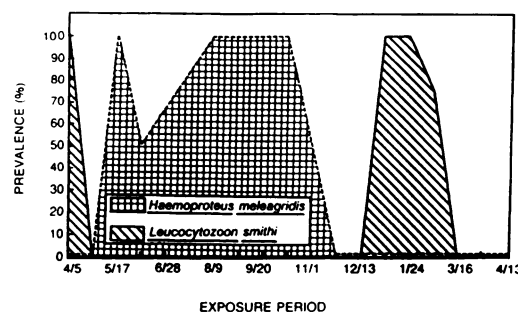


FIGURE 1. Temporal prevalence of *Haemoproteus meleagridis* and *Leucocytozoon smithi* in sentinel turkeys exposed to biting flies on Tallahala Wildlife Management Area (Jasper County, Mississippi, USA) from 5 April 1988 through 13 April 1989.

DISCUSSION

Haemoproteus meleagridis and *L. smithi* previously were reported only in the delta region of Mississippi (Eve et al., 1972b). Our data and unpublished information (C. E. Couvillion, unpubl.) indicate that these organisms are widespread in wild turkeys in the state and occur at prevalences comparable to other areas of the southeastern United States (Cook et al., 1966; Goggans, 1966; Eve et al., 1972a, b; Forrester et al., 1974).

TABLE 1. Extended.

Num- ber exam- ined	Total		
	H	L	HL
51	100	0	0
13	77	46	38
28	89	64	61
41	80	56	56
61	67	26	15
51	82	55	53
112	76	40	32
204	84	33	28

Both *H. meleagridis* and *L. smithi* occur in high prevalence in wild turkeys and were detected during all sampling periods. The 100% prevalence of both species in male birds during spring may be due to cyclical changes in parasitemias; lower, less detectable, levels in winter would be followed by recrudescence in spring coincident with increased vector populations (Chernin, 1952; Hawking, 1962; Alverson and Noblet, 1977). The prevalences of infection could be affected by the method of capture (cannon net versus shooting) but the effect of capture method on parasitemia is unknown. Failure to detect differences in the prevalences of *H. meleagridis* and *L. smithi* between juveniles and adults or between male and female turkeys in any season could be due to varied sample sizes (Table 1).

Transmission of *H. meleagridis* and *L. smithi* on TWMA do not overlap. *Haemoproteus meleagridis* is not transmitted in winter and early spring (December through April), probably due to the absence of vectors at that time. Atkinson et al. (1988a) attributed lack of winter (January through April) transmission in north-

ern Florida to inhibited sporogony in the vector induced by cooler temperatures. As described by Atkinson et al. (1988a) for northern Florida, earliest transmission on TWMA occurs in mid-May coinciding with peak hatching and brood rearing (Seiss, 1989) of turkey poults. Data from infected wild poults trapped in mid-July indicate that infection occurs soon after hatching on TWMA. Because young domestic turkey poults can develop severe disease following infection (Atkinson et al., 1986, 1988b), *H. meleagridis* may be an important limiting factor for wild poults.

Sentinel studies revealed that transmission of *L. smithi* occurred only from January through early April as described in Virginia (Byrd, 1959). Lack of transmission to young wild turkey poults in spring and summer was demonstrated by absence of infection in poults ($n = 51$) trapped in August. *Leucocytozoon smithi* was readily transmitted to sentinel turkeys in winter. Failure to detect *L. smithi* in juvenile wild turkeys in winter could be due to inadequate sample size or low prevalence of infection in this segment of the population. In contrast to *H. meleagridis*, transmission of *L. smithi* on TWMA occurs well before hatching and brood rearing when wild turkeys are older and probably less susceptible to any pathologic effects.

The absence of avian malaria in Mississippi was surprising since the organism has been found in wild turkeys in Florida, Texas and Iowa (Forrester et al., 1974; Telford and Forrester, 1975; Castle et al., 1988; Christensen et al., 1983). Efforts to demonstrate malaria in four other widely separated locations in Mississippi, i.e. Kemper ($n = 3$), Marion ($n = 13$), and Washington ($n = 12$) counties (C. E. Couvillion, unpubl.), and one area in Kentucky (Castle and Christensen, 1984) also have been negative. Failure to find malaria probably is due to absence of suitable vectors (Young et al., 1977; Forrester et al., 1980) and demonstrates that the organism is not a mortality factor for wild turkeys in this region.

ACKNOWLEDGMENTS

The authors thank the following agencies for cooperative support: Mississippi Department of Wildlife Conservation (Federal Aid in Wildlife Restoration), National Wild Turkey Federation, National Rifle Association, Anderson Tully Corporation, Walker Wildlife Foundation, Izaak Walton League of America Endowment, U.S. Forest Service, and the Max McGraw Wildlife Foundation.

LITERATURE CITED

- ALVERSON, D. R., AND R. NOBLET. 1977. Spring relapse of *Leucocytozoon smithi* (Sporozoa: Leucocytozoidae) in turkeys. *Journal of Medical Entomology* 14: 132-133.
- ATKINSON, C. T., AND D. J. FORRESTER. 1987. Myopathy associated with megaloschizonts of *Haemoproteus meleagridis* in a wild turkey from Florida. *Journal of Wildlife Diseases* 23: 495-498.
- , ———, AND E. C. GREINER. 1988a. Epizootiology of *Haemoproteus meleagridis* (Protozoa: Haemosporina) in Florida: Seasonal transmission and vector abundance. *Journal of Medical Entomology* 25: 45-51.
- , ———, AND ———. 1988b. Pathogenicity of *Haemoproteus meleagridis* (Haemosporina: Haemoproteidae) in experimentally infected domestic turkeys. *The Journal of Parasitology* 74: 228-239.
- , E. C. GREINER, AND D. J. FORRESTER. 1986. Pre-erythrocytic development and associated host responses to *Haemoproteus meleagridis* (Haemosporina: Haemoproteidae) in experimentally infected domestic turkeys. *Journal of Protozoology* 33: 375-381.
- BYRD, M. A. 1959. Observations on *Leucocytozoon* in pen-raised and free ranging wild turkeys. *Journal of Wildlife Management* 23: 145-156.
- CASTLE, M. D., AND B. M. CHRISTENSEN. 1984. Blood and gastrointestinal parasites of eastern wild turkeys from Kentucky and Tennessee. *Journal of Wildlife Diseases* 20: 190-196.
- , B. M. CHRISTENSEN, AND T. E. ROCKE. 1988. Hematozoan parasites of Rio Grande wild turkeys from southern Texas. *Journal of Wildlife Diseases* 24: 88-96.
- CHERNIN, E. 1952. The relapse phenomenon in *Leucocytozoon* infection in the domestic duck. *American Journal of Hygiene* 56: 101-118.
- CHRISTENSEN, B. M., H. J. BARNES, AND W. A. ROWLEY. 1983. Vertebrate host specificity and experimental vectors of *Plasmodium* (Novyella) *kemp* sp. n. from the eastern wild turkey in Iowa. *Journal of Wildlife Diseases* 19: 204-213.
- COOK, R. S., D. O. TRAINER, AND W. C. GLAZENER. 1966. *Haemoproteus* in wild turkeys from the coastal bend of South Texas. *Journal of Protozoology* 13: 588-590.
- EVE, J. H., F. E. KELLOGG, AND R. W. BAILEY. 1972a. Blood parasites in wild turkeys of eastern West Virginia. *The Journal of Wildlife Management* 36: 624-627.
- , ———, AND F. A. HAYES. 1972b. Blood parasitisms of wild turkeys in the southeastern United States. *Journal of the American Veterinary Medical Association* 161: 638-640.
- FORRESTER, D. J., L. T. HON, L. E. WILLIAMS, JR., AND D. H. AUSTIN. 1974. Blood protozoa of the wild turkey in Florida. *Journal of Protozoology* 21: 494-497.
- , P. P. HUMPHREY, S. R. TELFORD, JR., AND L. E. WILLIAMS, JR. 1980. Effects of blood-induced infection of *Plasmodium hermani* on domestic and wild turkey poults. *Journal of Wildlife Diseases* 16: 237-244.
- , J. K. NAYER, AND G. W. FOSTER. 1980. *Culex nigripalpus*: A natural vector of wild turkey malaria (*Plasmodium hermani*) in Florida. *Journal of Wildlife Diseases* 16: 391-394.
- GOGGANS, J. G. 1966. A survey of blood parasites in the wild turkey of Alabama. M.S. Thesis. Auburn University, Auburn, Alabama, 35 pp.
- HAWKING, F. 1962. Microfilaria infestation as an instance of periodic phenomena seen in host-parasite relationships. *Annals of the New York Academy of Sciences* 98: 940-953.
- SEISS, R. S. 1989. Reproductive parameters and survival rates of wild turkey hens in east-central Mississippi. M.S. Thesis. Mississippi State University, Mississippi State, Mississippi, 99 pp.
- TELFORD, S. R., JR., AND D. J. FORRESTER. 1975. *Plasmodium* (Huffia) *hermani* sp. n. from wild turkeys (*Meleagris gallopavo*) in Florida. *Journal of Protozoology* 22: 324-328.
- WILLIAMS, L. E. 1981. *The book of the wild turkey*. Winchester Press, Tulsa, Oklahoma, 181 pp.
- YOUNG, M. D., J. K. NAYER, AND D. J. FORRESTER. 1977. Mosquito transmission of wild turkey malaria, *Plasmodium hermani*. *Journal of Wildlife Diseases* 13: 168-169.

Received for publication 8 September 1989.