



## **Lesions Associated with Pulmonary Parasites in Bobcats (*Felis rufus*) from Arkansas**

Authors: Snyder, Daniel E., Hamir, Amir N., Nettles, Victor F., and Rupprecht, Charles E.

Source: Journal of Wildlife Diseases, 27(1) : 170-174

Published By: Wildlife Disease Association

URL: <https://doi.org/10.7589/0090-3558-27.1.170>

---

BioOne Complete ([complete.BioOne.org](https://complete.BioOne.org)) is a full-text database of 200 subscribed and open-access titles in the biological, ecological, and environmental sciences published by nonprofit societies, associations, museums, institutions, and presses.

Your use of this PDF, the BioOne Complete website, and all posted and associated content indicates your acceptance of BioOne's Terms of Use, available at [www.bioone.org/terms-of-use](https://www.bioone.org/terms-of-use).

Usage of BioOne Complete content is strictly limited to personal, educational, and non - commercial use. Commercial inquiries or rights and permissions requests should be directed to the individual publisher as copyright holder.

---

BioOne sees sustainable scholarly publishing as an inherently collaborative enterprise connecting authors, nonprofit publishers, academic institutions, research libraries, and research funders in the common goal of maximizing access to critical research.

## Lesions Associated with Pulmonary Parasites in Bobcats (*Felis rufus*) from Arkansas

Daniel E. Snyder,<sup>1</sup> Amir N. Hamir,<sup>2</sup> Victor F. Nettles,<sup>3</sup> and Charles E. Rupprecht,<sup>4</sup> <sup>1</sup> U.S. Department of Agriculture, Agricultural Research Service, Animal Parasite Research Laboratory, POB 952, Auburn, Alabama 36831, USA; <sup>2</sup> University of Pennsylvania, School of Veterinary Medicine, New Bolton Center, 382 West Street Road, Kennett Square, Pennsylvania 19348, USA; <sup>3</sup> Southeastern Cooperative Wildlife Disease Study, Athens, Georgia 30602, USA; <sup>4</sup> The Wistar Institute of Anatomy and Biology, 3601 Spruce St., Philadelphia, Pennsylvania 19104, USA

**ABSTRACT:** Two of five bobcats (*Felis rufus*) from southwestern Arkansas had natural pulmonary infections of *Paragonimus kellicotti* and *Filaroides rostratus*. Pairs of *P. kellicotti* were found in spherical cyst-like structures approximately 1 cm in diameter. *Filaroides rostratus* were seen as serpentine pale white areas on the pleural surface and also firmly embedded in fibrous capsules in the pulmonary parenchyma. Histologic lesions associated with the presence of these parasites consisted primarily of a verminous bronchitis. Clinical signs or compromised pulmonary function were not associated with these infections.

**Key words:** *Paragonimus kellicotti*, trematode, *Filaroides rostratus*, nematode, bobcat, *Felis rufus*, pulmonary pathology, case report.

Five adult bobcats (*Felis rufus*) were live-trapped in the autumn of 1988 near Norman, Arkansas (34°27'N, 93°41'W) and transported to the Lawrenceville Animal Facility of the Centers for Disease Control (Atlanta, Georgia, USA). These animals were used as part of baseline data collection and experimental safety evaluation of an oral vaccinia-rabies glycoprotein recombinant virus vaccine (Rupprecht et al., 1986). Upon arrival the animals were examined, housed individually in raised stainless steel cages and observed for 10 days. During this quarantine period all five animals remained healthy and vigorous. The bobcats received water ad libitum and fresh chicken parts twice daily throughout the experiment. Each animal was immobilized with 10 mg/kg of ketamine hydrochloride (Ketaset®, Bristol Veterinary Products, Syracuse, New York, 13221, USA) administered intramuscularly, bled via the femoral vein and examined. The

vaccine was administered orally to all five bobcats which were then maintained in isolation and observed for 30 days. All five bobcats remained in good health and, at the end of 30 days, were humanely killed and complete necropsies were performed.

On gross examination, the lungs of two of the bobcats (a male and a female) had several spherical cyst-like structures approximately 1 cm in diameter and firm on palpation (Fig. 1). The pulmonary pleura overlying the cysts was smooth, opaque and white to gray in color. One of these same animals also had three serpentine-like pale white areas on the pleural surface (Fig. 2). On cut surface, there were focal areas of necrosis. A dark brown exudate was present in the cysts, bronchi and bronchioles. Representative tissue samples of all major organs were fixed in 10% neutral buffered formalin, embedded in paraffin, cut at 6 µm and stained with hematoxylin and eosin for light microscopy. Selected sections of lung were also stained with silver stain (GMS) for detection of fungal organisms.

Blunt dissection of several cysts revealed two mature *Paragonimus kellicotti* per cyst in the lungs of both bobcats (Fig. 1). Dissection and extraction of the serpentine areas on the pleural surface (Fig. 2) were extremely difficult because they were firmly embedded in a fibrous capsule within the lung parenchyma. Pieces dissected from the lung were identified as nematodes; the females were white in color and contained large numbers of embryos in all stages of development. In the distal por-

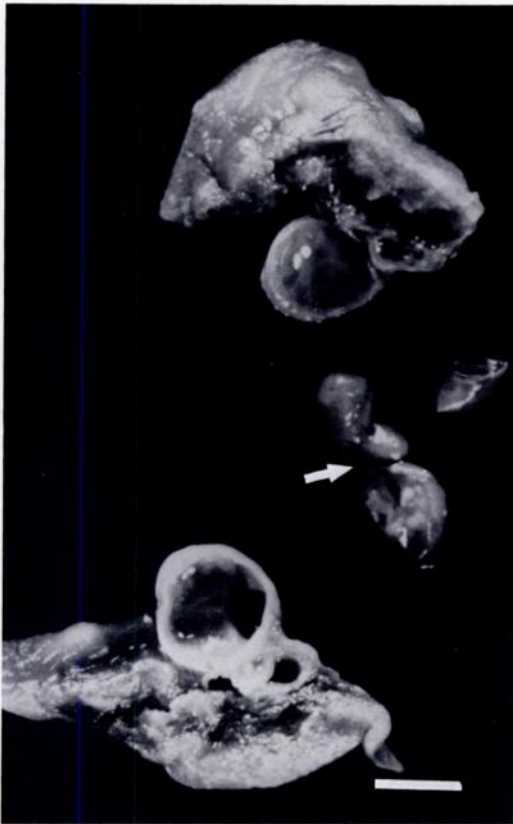

FIGURE 1. Cross section through a cyst in lung of bobcat infected with *Paragonimus kellicotti*; note the pair of flukes (arrow) that were in the cyst. Bar = 0.5 cm.



FIGURE 2. *Filaroides rostratus* seen as serpentine areas on pleural surface of lung of infected bobcat. Bar = 0.5 cm.

tions of each female worm, fully developed larvae were surrounded by a thin vitelline membrane. These nematodes were identified as *Filaroides rostratus* (= *Oslerus rostratus*; = *Anafilaroides rostratus*) based on the descriptions given by Gerichter (1949), Seneviratna (1959), and Kontrimavichus and Delyamure (1979). Representative specimens of *P. kellicotti* and *F. rostratus* are deposited in the U.S. National Parasite Collection (Beltsville, Maryland 20705, USA; Accession numbers 80815 and 80816).

Microscopically, the lesions were confined to the lungs of both bobcats. The necrotic and cystic lesions appeared similar in both animals and were limited to the bronchi and peribronchial tissue. These

lesions consisted of moderate to severe dilations of the lumina with marked hypertrophy of mucosal epithelial cells in all the air passages (Figs. 3, 4). Within the lumina there were variable amounts of exudate that contained moderate numbers of inflammatory cells (predominantly neutrophils with lesser numbers of macrophages), copious amounts of mucus and red blood cells. Occasionally thick-shelled embryonated fluke eggs were seen within the lumina of air passages and in the pulmonary parenchyma. In a number of areas the lumina of air passages were extremely dilated and distorted. In such areas the mucosal lining revealed moderate to severe diffuse squamous metaplasia (Figs. 5, 6). Within a few of such severely dilated lumina, cross-sections of flukes (sometimes

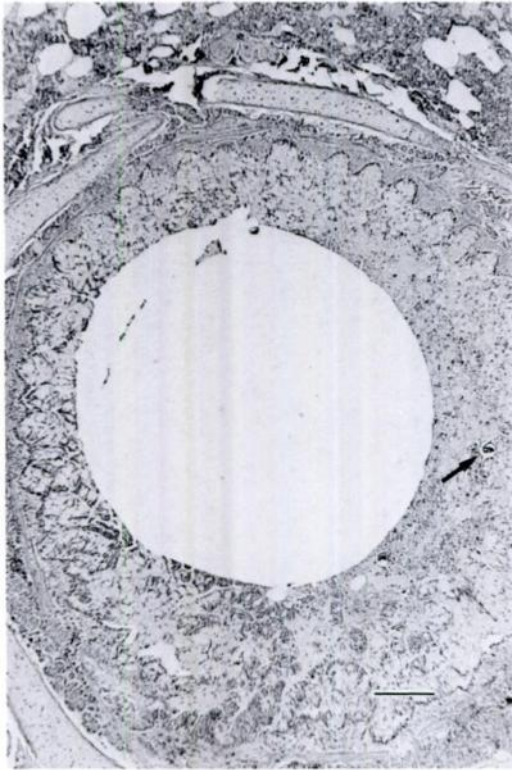


FIGURE 3. Dilated lumen of bronchus with marked hypertrophy of mucosal cells. Note trematode eggs (arrow). H&E. Bar = 100  $\mu$ m.

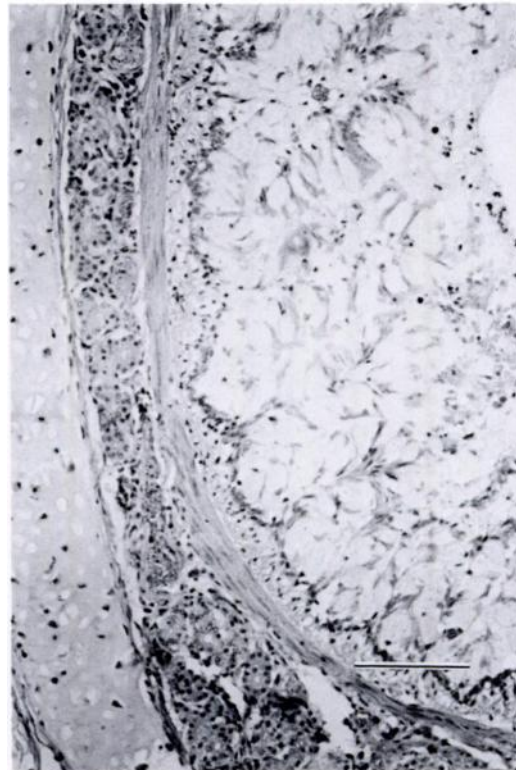


FIGURE 4. Higher magnification of Fig. 3 showing marked hypertrophy of mucosal cells. H&E. Bar = 50  $\mu$ m.

seen in pairs) were present (Fig. 6). There were multifocal ulcerations of the metaplastic squamous mucosa in these areas. The peribronchiolar tissue associated with the more severely affected air passages was moderately to severely infiltrated with inflammatory cells in which macrophages and lymphocytes predominated. The latter also formed prominent lymphoid follicles around the air passages. The arteries around most of the airways revealed moderate to severe medial hypertrophy. Elsewhere in the lung the alveolar tissue appeared moderately thickened and there was marked hypertrophy of the smooth muscle. Additionally, the bobcat with *F. rostratus* revealed multifocal areas of mild fibrosis and a moderate inflammatory infiltrate in the alveolar parenchyma. The alveolar parenchyma contained sections of adult nematodes and within females larvae

were present (Fig. 7). Larvae were seen also within the pulmonary parenchyma and in alveolar spaces. In general, the inflammatory cellular reaction associated with this parasite was less severe than with *P. kellicotti*. The GMS stained preparations were negative for fungi.

Both of these parasites have been reported from bobcats in the United States (Jordan and Byrd, 1958; McKeever, 1958; Klewer, 1958; Miller and Harkema, 1968; Watson et al., 1981); however, this is the first report for both parasites from this host species in Arkansas and for their presence in bobcats west of the Mississippi River. Histologic lesions associated with these parasites in the bobcat have not been described previously and only the report of Watson et al. (1981) briefly described gross lesions without accompanying figures. Descriptions of gross and histologic lesions in

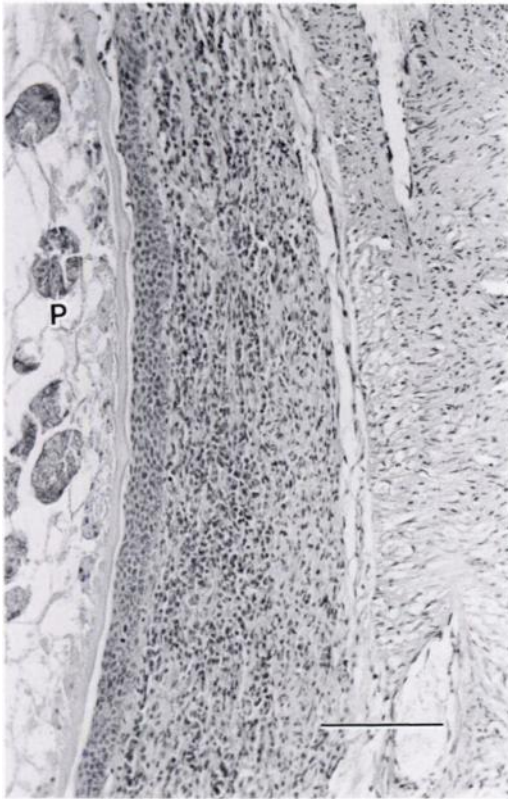


FIGURE 5. Portion of airway showing smooth muscle hyperplasia, diffuse inflammatory cellular infiltrate and moderate squamous metaplasia of epithelial lining adjacent to *Paragonimus kellicotti* (P). H&E. Bar = 50  $\mu$ m.

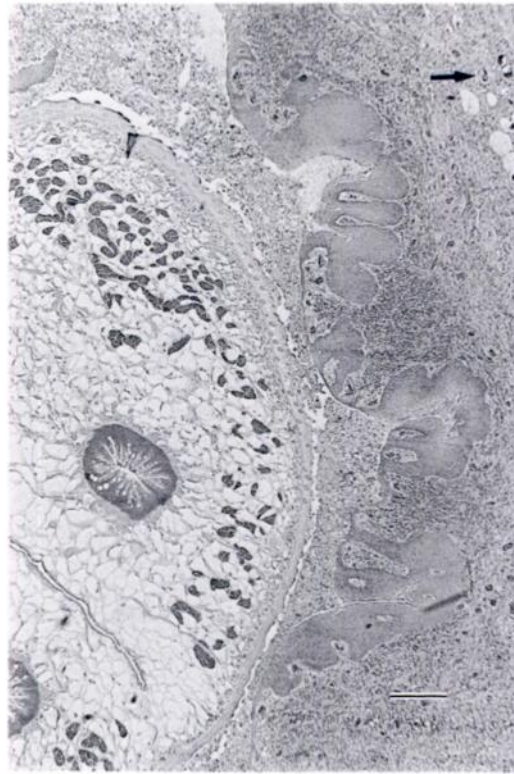


FIGURE 6. Section through *Paragonimus kellicotti* within dilated lumen of air passage. Note severe squamous metaplasia of epithelial lining and trematode eggs (arrow) in surrounding lung tissue. H&E. Bar = 100  $\mu$ m.

other wildlife infected with *P. kellicotti* (Presidente and Ramsden, 1975; Ramsden and Presidente, 1975) indicate that the host reaction associated with the presence of this parasite in the pulmonary system of different definitive hosts is quite variable. In addition, differences in the numbers of flukes recovered and the average size of flukes vary with the species of definitive host that is infected (McKeever, 1958). Gross and histopathologic lesions have been described in the domestic cat (*Felis catus*) infected with *P. kellicotti* and are similar to those found in the bobcats described herein (Herman and Helland, 1966). Based on the prevalence, size of flukes recovered and the minimal host reaction in the pulmonary tissue, it is thought that mink are

the normal definitive hosts for *P. kellicotti* in North America.

While the lesions found in these two bobcats undoubtedly affected pulmonary function, clinically they appeared normal. Previous reports in the literature have not indicated any compromised pulmonary function or clinical signs associated with the presence of these parasites in bobcats. Most animals with paragonimiasis are asymptomatic; however, there may be a variety of clinical signs referable to the respiratory tract.

The authors gratefully acknowledge the assistance of G. Baer, Centers for Disease Control. This work was supported in part by the Pennsylvania Department of Agriculture, Ametek Corporation and the Rockefeller Foundation.

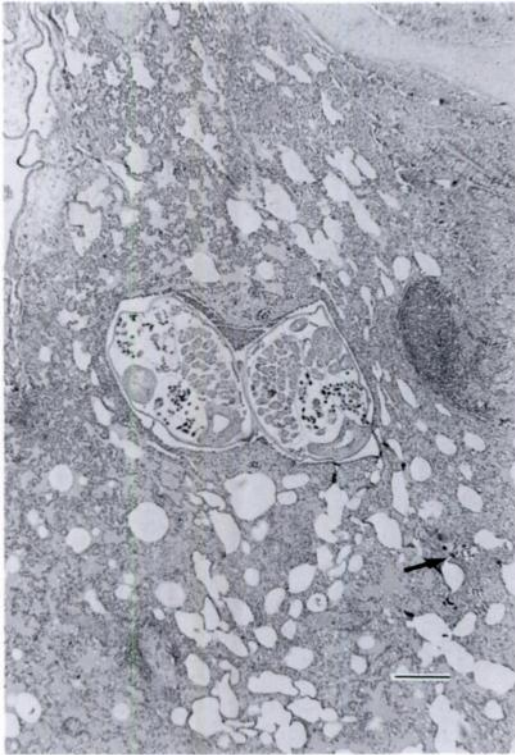

FIGURE 7. Section through female *Filaroides rostratus* within pulmonary parenchyma. Note larvae (arrow) in pulmonary parenchyma. H&E. Bar = 100  $\mu$ m.

#### LITERATURE CITED

- GERICHTER, C. B. 1949. Studies on the nematodes parasitic in the lungs of Felidae in Palestine. *Parasitology* 39: 251-262.
- HERMAN, L. H., AND D. R. HELLAND. 1966. Paragonimiasis in a cat. *Journal of the American Veterinary Medical Association* 149: 753-759.
- JORDAN, H. E., AND E. E. BYRD. 1958. *Paragonimus* in wild and domesticated animals in Georgia. *The Journal of Parasitology* 44: 470.
- KLEWER, H. L. 1958. The incidence of helminth lung parasites of *Lynx rufus rufus* (Shreber) and the life cycle of *Anafilaroides rostratus* Gerichter, 1949. *The Journal of Parasitology* 44(suppl): 29.
- KONTRIMAVICHUS, V. L., AND S. L. DELYAMURE. 1979. Filaroids of domestic and wild animals. In *Fundamentals of nematology*, Vol. 29. Nauka Publishers, Moscow, U.S.S.R., pp. 30-36.
- MCKEEVER, S. 1958. Observations on *Paragonimus kellicotti* Ward from Georgia. *The Journal of Parasitology* 44: 324-327.
- MILLER, G. C., AND R. HARKEMA. 1968. Helminths of some wild mammals in the southeastern United States. *Proceedings of the Helminthological Society of Washington* 35: 118-125.
- PRESIDENTE, P. J. A., AND R. O. RAMSDEN. 1975. *Paragonimus kellicotti* infection in wild carnivores in southwestern Ontario: II. Histopathologic features. *Journal of Wildlife Diseases* 11: 364-375.
- RAMSDEN, R. O., AND P. J. A. PRESIDENTE. 1975. *Paragonimus kellicotti* infection in wild carnivores in southwestern Ontario: I. Prevalence and gross pathologic features. *Journal of Wildlife Diseases* 11: 136-141.
- RUPPRECHT, C. E., T. J. WIKTOR, D. H. JOHNSON, A. N. HAMIR, B. DIETZSCHOLD, W. H. WUNNER, L. T. GLICKMAN, AND H. KOPROWSKI. 1986. Oral immunization and protection of raccoons (*Procyon lotor*) with a vaccinia-rabies glycoprotein recombinant virus vaccine. *Proceedings National Academy of Sciences, USA* 83: 7947-7950.
- SENEVIRATNA, P. 1959. Studies on *Anafilaroides rostratus* Gerichter, 1949 in cats. I. The adult and its first stage larva. *Journal of Helminthology* 33: 99-108.
- WATSON, T. G., V. F. NETTLES, AND W. R. DAVIDSON. 1981. Endoparasites and selected infectious agents in bobcats (*Felis rufus*) from West Virginia and Georgia. *Journal of Wildlife Diseases* 17: 547-554.

Received for publication 22 September 1989.