

Coccidiosis in Common Wombats (*Vombatus ursinus*)

Authors: Hum, S., Barton, N. J., Obendorf, David, and Barker, Ian K.

Source: Journal of Wildlife Diseases, 27(4) : 697-700

Published By: Wildlife Disease Association

URL: <https://doi.org/10.7589/0090-3558-27.4.697>

BioOne Complete (complete.BioOne.org) is a full-text database of 200 subscribed and open-access titles in the biological, ecological, and environmental sciences published by nonprofit societies, associations, museums, institutions, and presses.

Your use of this PDF, the BioOne Complete website, and all posted and associated content indicates your acceptance of BioOne's Terms of Use, available at www.bioone.org/terms-of-use.

Usage of BioOne Complete content is strictly limited to personal, educational, and non - commercial use. Commercial inquiries or rights and permissions requests should be directed to the individual publisher as copyright holder.

BioOne sees sustainable scholarly publishing as an inherently collaborative enterprise connecting authors, nonprofit publishers, academic institutions, research libraries, and research funders in the common goal of maximizing access to critical research.

Coccidiosis in Common Wombats (*Vombatus ursinus*)

S. Hum,^{1,2} N. J. Barton,¹ David Obendorf,³ and Ian K. Barker,⁴ ¹ Department of Agriculture and Rural Affairs, Regional Veterinary Laboratory, P.O. Box 483, Bairnsdale, Victoria 3875, Australia; ² Department of Agriculture, Regional Veterinary Laboratory, Private Mail Bag, Armidale, New South Wales 2351, Australia; ³ Mount Pleasant Laboratories, Dept. of Primary Industry, P.O. Box 46, Kings Meadows, Tasmania 7249, Australia; ⁴ Department of Pathology, Ontario Veterinary College, University of Guelph, Guelph, Ontario, Canada N1G 2W1

ABSTRACT: *Eimeria arundeli* is a widespread coccidian parasite of the common wombat (*Vombatus ursinus*), and has been considered to be nonpathogenic. We describe disease in two captive juvenile wombats ascribed to infection with *E. arundeli*. One animal had diarrhea, the second had mucoid soft feces and lost weight over several weeks prior to death. Masses of coccidial gametocytes in hypertrophic cells in the lamina propria distended villi, causing grossly visible raised pale thickened regions over extensive areas of the mucosa of the small intestine in both animals. Neutrophils infiltrated affected mucosa, and there was an inflammatory exudate into the intestinal lumen in case one. In case two, neutrophils infiltrated the lamina propria of villi focally, crypts were distended by necrotic debris, and epithelium on villi was extremely attenuated. No bacterial pathogens were isolated from lung and intestine in case one; case two was not cultured. Oocysts consistent with *E. arundeli* were present in large numbers in flotations of diarrheic feces in both cases.

Key words: Common wombat, *Vombatus ursinus*, coccidiosis, *Eimeria arundeli*, case reports.

Eimeria arundeli is an intestinal coccidian of the common wombat (*Vombatus ursinus*), a large, burrowing, herbivorous Australian marsupial. Oocysts are encountered occasionally in fecal flotations, and endogenous stages may be found in the lamina propria of the intestinal mucosa of clinically normal, free-ranging, wild animals (Barker et al., 1979; Presidente, 1982). Although the infection may be associated with mild chronic inflammation (Presidente, 1982) and hypertrophy of infected villi (Barker et al., 1979), these authors did not observe diarrhea in infected animals and concluded that *E. arundeli* was of little pathogenic significance. Herein, we report findings in two common wombats in which severe intestinal coccidiosis was the only demonstrable explanation for disease.

Case one was a 12-mo-old female found dead in a wildlife park in southeastern Victoria (37°04'S, 149°55'E), following 2 days of slight diarrhea. At necropsy the animal was in good body condition, but was moderately dehydrated and had fecal staining of the perineum, indicating diarrhea. Apart from pulmonary congestion, gross abnormalities were confined to the intestine. A 1.4 m section of the proximal small intestine was markedly thickened, and the mucosa had a reticular mottled appearance, caused by yellow-white areas raised above surrounding more normal mucosa, as observed in wombats with coccidial infection by Gilruth and Bull (1911) and Barker et al. (1979). The intestinal villi were so hypertrophic that they could be recognised with the naked eye, and they resembled the "thick grey fur" described by Gilruth and Bull (1911). Both small and large intestines contained brown mucoid liquid digesta.

Case two was a 9-mo-old female held in a wildlife park in northern Tasmania (41°23'S, 147°10'E). The animal had suffered a gradual deterioration in body condition over a 4 week period, and had soft mucoid feces which lacked the normal "brick" shape characteristic of wombats. It was euthanatized by barbiturate overdose (Euthatal®, May and Baker Australia, West Foostcray, Victoria 3012, Australia). At necropsy, significant findings were limited to the small intestine, in which gross lesions similar to those seen in case one, and involving the entire distal half of the small intestine, were present.

Brain and tissues from all major visceral organs were collected for histology from case one; from case two, major parenchyma-

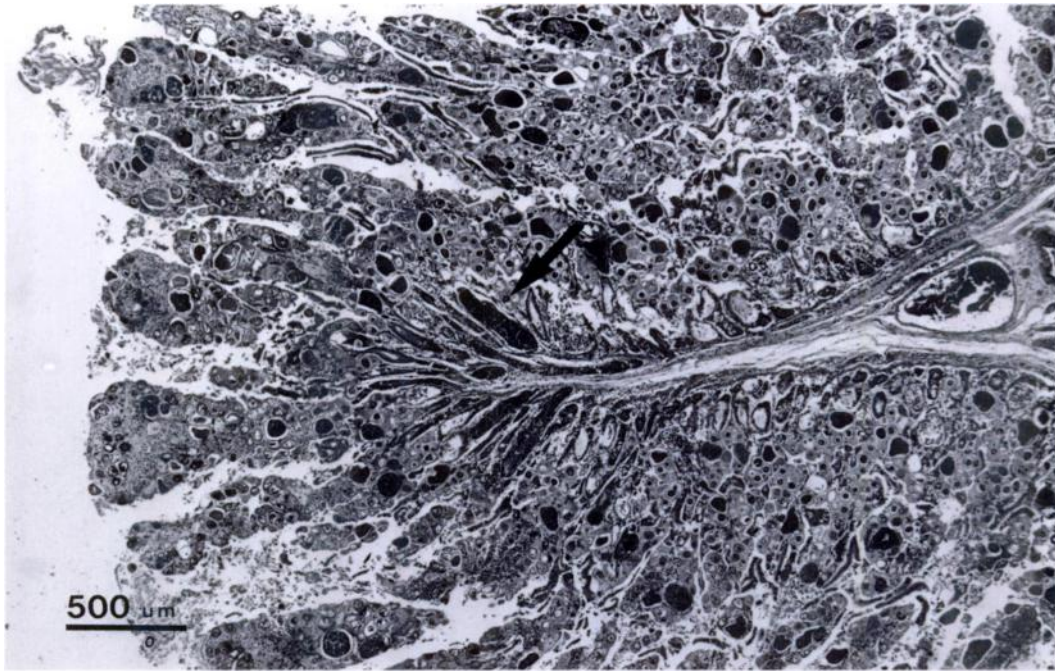


FIGURE 1. Hypertrophic villi in thickened small intestinal mucosa of a common wombat (case one) infected with massive numbers of gametocytes of *Eimeria arundeli*. Congested mucosal blood vessels (arrow).

matous organs and intestine were retained. These tissues were fixed in 10% neutral buffered formalin, embedded in paraffin, sectioned at 6 μm and stained with hematoxylin and eosin. Tissue sections from case one have been deposited in the National Registry of Zoo Animal Pathology (Taronga Park Zoological Gardens, P.O. Box 20, Mosman, NSW 2066, Australia; accession number C 0086).

Moderate autolysis was evident in tissues from case one examined microscopically, but interpretation of lesions was still possible. The mucosa was congested, and the lamina propria from the muscularis mucosae to the tips of villi was heavily parasitized by masses of coccidial gametocytes in hypertrophic host cells, resulting in thickening of the mucosa and distention and hypertrophy of villi (Fig. 1). Microgametocytes formed cysts up to 190 μm in diameter, similar to those described by Barker et al. (1979). Macrogametes were recognized by the development of large deeply eosinophilic wall-forming bodies

(Barker et al., 1979). Nearly-mature oocysts were observed only occasionally (Fig. 2). Crypts of Lieberkuhn deep in the mucosa adjacent to the muscularis mucosae often were dilated, and lined by cuboidal or squamous epithelium, probably the result of compression by coccidial gametocytes in the more superficial lamina propria. Neutrophils and exfoliated epithelial cells were in the lumina of dilated crypts. The lamina propria of affected villi was edematous, with dilated lymphatics, and was infiltrated by moderate numbers of mononuclear cells, eosinophils and large numbers of neutrophils (Fig 2). In some sections, proteinaceous exudate containing neutrophils, epithelial cells and necrotic debris was present in the lumen of the small intestine.

Microscopic lesions in case two were fundamentally similar, but no neutrophilic exudate into the intestinal lumen was recognized. There was marked attenuation of epithelial cells on the surface of villi distended by coccidial gamonts.

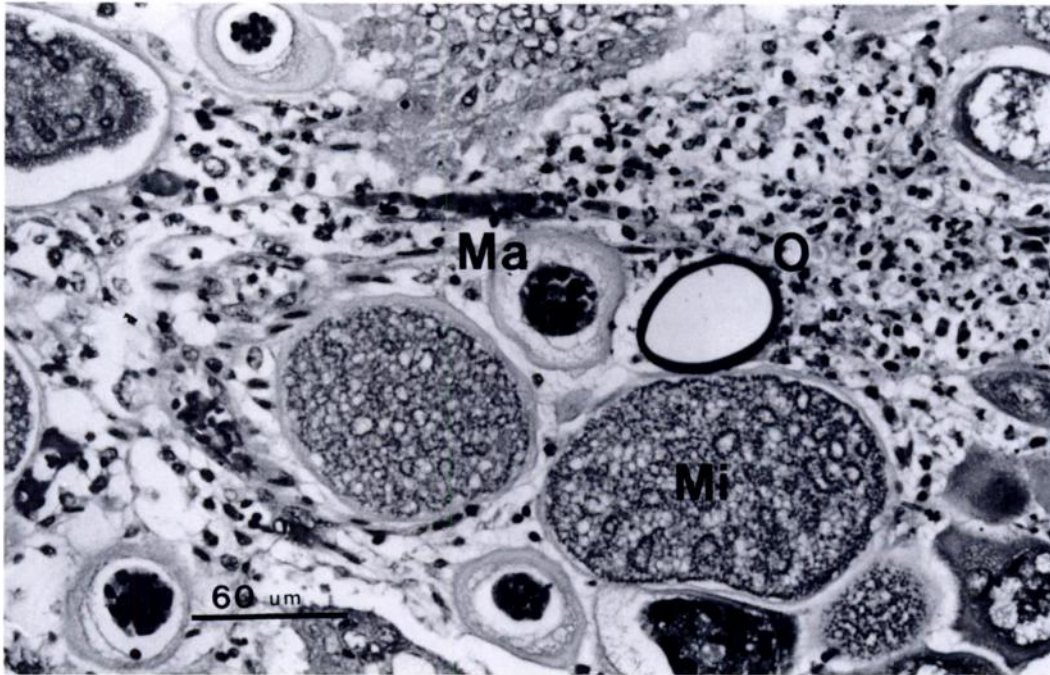

FIGURE 2. H&E. 2. Microgametocytes (Mi), macrogametes (Ma) and oocyst (O) of *Eimeria arundeli* from a common wombat. The contents of the oocyst are missing (artefact). Fibrinopurulent exudate in the lamina propria of the mucosa above the oocyst. H&E.

In case one, scattered gametocytes were detected in the lamina propria of the colon, a location where they have not been observed previously. Schizonts are unknown in this species (Barker et al., 1979) and a search for them in the gastrointestinal tract, liver and biliary epithelium of this animal was unrewarding. Sections of the lung were congested, and occasionally alveoli contained some proteinaceous fluid, and a few neutrophils. In both cases, lesions were not present in other tissues. Lymphoid involution in splenic white pulp was not marked.

No pathogenic bacteria were found on aerobic culture of the lung and portions of small and large intestines of case one. Selective culture for *Salmonella* sp. and *Yersinia* sp. was negative. Flotation of the liquid faeces collected from the distal colon of case one yielded 19,000 coccidial oocysts/g; case two had 50,000 coccidial oocysts/g of feces. The large, thick walled, brown oocysts were morphologically con-

sistent with those of *Eimeria arundeli* (Barker et al., 1979).

We conclude that coccidiosis was the cause of death in case one, on the basis of severe infection of the small intestine with *E. arundeli*, associated with neutrophil infiltrates into the lamina propria and exudation into the lumen of the gut. The absence of a recognized bacterial pathogen supports this conclusion. The similarity of the lesions in case two suggests a similar diagnosis, though an exudative enteritis was not present. Cells on the surface of villi in affected intestine were essentially squamous, and malabsorption may have contributed to the chronic course of wasting and soft mucoid feces seen in this animal.

Coccidiosis is well recognised as a disease of immunologically compromised or naive animals, in many species. The cases reported here were juveniles held in wildlife parks occupied by older wombats. Wombats begin grazing at about 10 mo of age (Presidente, 1982), so infection prob-

ably resulted from exposure of naive animals to oocysts in what may have been a heavily contaminated environment. There were no lesions or intercurrent infections to suggest immunologic compromise beyond that associated with the severe illness experienced by these animals.

It is noteworthy that these animals were shedding large numbers of oocysts in their feces. Usually, the number of oocysts in feces is relatively low, and gametocytes are more commonly encountered in tissue than oocysts in feces (Barker et al., 1979). In wombats in which *E. arundeli* is encountered as an incidental finding, the number of gametocytes in tissue generally is lower than that observed in these cases, and/or the distribution of thickened infected mucosa is less extensive. In well-fixed material from such cases, the epithelium on villi is intact and columnar, crypts are not dilated, and there is no acute inflammatory infiltrate or exudate (Barker et al., 1979; S. Hum, unpubl. observations).

The findings reported here suggest that heavy infections with *E. arundeli* may be pathogenic under some circumstances. Clinical coccidiosis has not been reported previously in captive or wild common wombats. Gilruth and Bull (1911) described a captive hairy-nosed wombat, (*Lasiorhinus latifrons*) in which the entire length of the small intestine had developing stages of a coccidian resembling *E. arundeli*, subsequently described as *E. wombati* (Barker et al., 1979). However, they were equivocal about attributing death of that animal to the protozoan infection.

Some of the habitat occupied by these animals is relatively inaccessible to people;

thus cases of coccidiosis in wild animals could go unreported. However, orphaned juvenile wombats are reared commonly in sanctuaries and zoos in south-eastern Australia, and animals are held in a number of zoos and wildlife parks. Hence, if coccidiosis were frequent in this species, as it is in captive juvenile kangaroos (Munday, 1988), it might have been observed more often than the two isolated cases reported here suggest is the prevalence. Although rare, it would appear that coccidiosis may occur in naive or immunologically compromised wombats exposed to heavily contaminated environments.

We thank F. G. Best and P. De Boer for submitting these cases. Photographs were prepared by J. J. Fields.

LITERATURE CITED

- BARKER, I. K., B. L. MUNDAY, AND P. J. A. PRESIDENTE. 1979. Coccidia of wombats: Correction of host-parasite relationships. *Eimeria wombati* (Gilruth and Bull, 1912) comb. nov. and *Eimeria urstini* Supperer, 1957 from the hairy-nosed wombat and *Eimeria arundeli* sp.n. from the common wombat. *The Journal of Parasitology* 65: 451-456.
- GILRUTH, J. A., AND L. B. BULL. 1911. Enteritis, associated with infection of the intestinal wall by cyst-forming protozoa (Neosporidia), occurring in certain native animals (wallaby, kangaroo and wombat). *Proceedings of the Royal Society of Victoria* 24 (New Series): 432-450.
- MUNDAY, B. L. 1988. Marsupial diseases. In *Australian wildlife*, Proceedings 104. Post Graduate Committee in Veterinary Science, University of Sydney, Sydney, New South Wales, Australia, pp. 299-365.
- PRESIDENTE, P. J. A. 1982. Common wombat *Vombatus ursinus*: Maintenance in captivity, blood values, infectious and parasitic diseases. In *The management of Australian mammals in captivity*, D. D. Evans (ed.). The Zoological Board of Victoria, Melbourne, Australia, pp. 133-143.

Received for publication 10 October 1990.