



## **Sarcocysts in the Florida Bobcat (*Felis rufus floridanus*)**

Authors: Anderson, Andrena J., Greiner, Ellis C., Atkinson, Carter T., and Roelke, Melody E.

Source: Journal of Wildlife Diseases, 28(1) : 116-120

Published By: Wildlife Disease Association

URL: <https://doi.org/10.7589/0090-3558-28.1.116>

---

BioOne Complete ([complete.BioOne.org](https://complete.BioOne.org)) is a full-text database of 200 subscribed and open-access titles in the biological, ecological, and environmental sciences published by nonprofit societies, associations, museums, institutions, and presses.

Your use of this PDF, the BioOne Complete website, and all posted and associated content indicates your acceptance of BioOne's Terms of Use, available at [www.bioone.org/terms-of-use](https://www.bioone.org/terms-of-use).

Usage of BioOne Complete content is strictly limited to personal, educational, and non - commercial use. Commercial inquiries or rights and permissions requests should be directed to the individual publisher as copyright holder.

---

BioOne sees sustainable scholarly publishing as an inherently collaborative enterprise connecting authors, nonprofit publishers, academic institutions, research libraries, and research funders in the common goal of maximizing access to critical research.

## Sarcocysts in the Florida Bobcat (*Felis rufus floridanus*)

Andrena J. Anderson<sup>1</sup>, Ellis C. Greiner<sup>2</sup>, Carter T. Atkinson<sup>3</sup> and Melody E. Roelke<sup>1</sup> <sup>1</sup> Florida Game and Fresh Water Fish Commission, Wildlife Research Laboratory, 4005 S. Main St., Gainesville, Florida 32601, USA; <sup>2</sup> Department of Infectious Diseases, College of Veterinary Medicine, University of Florida, Gainesville, Florida 32610, USA; <sup>3</sup> Institute of Pathology, Case Western Reserve University, Cleveland, Ohio 44106, USA

**ABSTRACT:** Sarcocysts were found in the tongue, diaphragm, heart, intestinal tunica muscularis, and skeletal muscle of bobcats (*Felis rufus floridanus*) collected in Florida (USA). The tongue was found to be the best indicator tissue for sarcocysts ( $P < 0.005$ ). Thirty of 60 bobcats screened were found to contain sarcocysts in at least one of the muscle tissues examined. Of the positive bobcats, 28 of 28 tongues contained sarcocysts, while only 10 of 27 (37%), and 8 of 26 (31%) contained sarcocysts in the diaphragm or cardiac muscle, respectively. Although immune suppression has been suggested as a possible reason for formation of sarcocysts in some carnivores, no such correlation was evident in the bobcats. Comparisons of prey species taken by the panther and bobcat, and overlap of geographical range by the two species leave questions as to the source of infection, and the species of *Sarcocystis* that is infecting both felids.

**Key words:** *Sarcocystis* sp., sarcocysts, muscle, bobcats, *Felis rufus floridanus*, survey.

The genus *Sarcocystis* consists of protozoan parasites that typically have a two-host life cycle. The intermediate host is usually an herbivore, and the initial site of asexual reproduction (merogony) occurs within the endothelium of the blood vessels producing merozoites that ultimately lead to sarcocyst formation in the musculature. The definitive host is generally a carnivore, and, following consumption of the sarcocysts in the muscles of prey species, sexual reproduction of the protozoan occurs in the enterocytes in the intestines, leading to the production of fully developed oocysts. Subsequently, oocysts and/or sporocysts are released in the feces of the carnivore, and ingested by herbivores and omnivores (Dubey et al., 1989). Sarcocyst formation typically does not occur in the carnivore host. Recently, however, the presence of the sarcocysts has been reported in animals that would normally

be classified as definitive hosts. Fiori and Lowndes (1988) and Everitt et al. (1987) described sarcocysts in apparently healthy domestic cats. Edwards et al. (1988) reported *Sarcocystis* spp. in cardiac and striated muscle of a domestic cat with lymphosarcoma. Kirkpatrick et al. (1986) found sarcocysts in the musculature of three domestic cats and Hill et al. (1988) found them in the muscles of two cats and a dog, all of which were severely compromised by diseases other than sarcocystosis. Immune suppression was suggested as the cause for the abnormal presence of the sarcocysts in each case.

More relevant to this study is the recent discovery of *Sarcocystis* spp. in 11 of 14 free-ranging Florida panthers (*Felis concolor coryi*) and 4 of 4 other cougars (*F. concolor*) (Greiner et al., 1989). It was speculated that their presence, in some cases, could have been associated with previous immunocompromise from feline parvovirus (FPV) or feline immunodeficiency virus infection (FIV). *Sarcocystis* spp. in the panther was most often found in the tongue, whereas in the domestic cats the sarcocysts were more common in the skeletal and cardiac muscles. Objectives developed to study these findings include (1) determining the prevalence of sarcocysts in other free-ranging carnivores and (2) ascertaining the host site preference in which the sarcocysts reside, if they were present. We chose the Florida bobcat (*Felis rufus floridanus*) to examine these questions due to the availability of tissues from a series of bobcats collected from nine counties in Florida, the bobcats' presence within the outside the present range of the Florida panther, and because the

panther and bobcat share prey species, the presumed source of the infection for *Sarcocystis* sp.

Previous interest in the bobcat as a sentinel and reservoir host for diseases and parasites important to the endangered Florida panthers resulted in the collection of tissue samples from the necropsy of 60 bobcats over a period of 4 yr from 1985 to 1988 (road-killed and hunter-killed). Although the bobcats had been collected from nine different counties in Florida (USA), the majority of them came from southern Florida ( $n = 55$ ) with the greatest proportion from Collier County ( $n = 41$ ). A smaller proportion ( $n = 5$ ) were from northern Florida and other areas considered currently to be non-panther habitat. There were 38 males, 21 females, and one bobcat of unrecorded sex included in this survey. The age of the bobcats ranged from 1 to 7 yr, with the majority between 2 and 5 yr of age. Sections of tongue, cardiac muscle, diaphragm, kidney, liver, spleen, pancreas, lung, and occasionally intestine and skeletal muscle were fixed in 10% buffered formalin, embedded in paraffin, sectioned, stained with hematoxylin and eosin stain, and examined by light microscopy for the presence of sarcocysts. Using an H&E stained tissue section for a guide, two sarcocysts were prepared for electron microscopy. They were located under a dissecting microscope on the cut surface of a formalin-fixed/paraffin-embedded piece of bobcat tongue. Tissue containing the sarcocysts was processed for electron microscopy as described by Greiner et al. (1989). The data derived from examination of the histological sections were then analyzed using Fisher's Exact method of Chi square analysis to determine the significance between the presence of sarcocysts and geographic distribution, sex and tissue distribution in individual bobcats.

Of the 60 bobcats screened, 30 (53% of the males and 47% of the females) were found to have sarcocysts in one or more of the tissues examined. Sarcocysts were found in the tongue, cardiac muscle, diaphragm,

tunica muscularis of the intestine, and skeletal muscle (Table 1). The sarcocysts were of various sizes, with the largest forms located in the tongue, ranging up to  $577 \mu\text{m} \times 185 \mu\text{m}$ . Mature sarcocysts contained obvious septae (Fig. 1) which are characteristic of the muscle inhabiting cysts of *Sarcocystis* sp. Immature sarcocysts filled with metrocytes (Fig. 2) were seen.

By transmission electron microscopy, the primary sarcocyst wall from bobcats was similar to that seen in the Florida panthers (Greiner et al., 1989). Short, irregularly spaced villi were present on the outside of the primary wall (Fig. 3), although they were not evident by light microscopy (Fig. 2). The "hobnail"-like bumps were present in the wall at the bases of the villi (Fig. 3), as they appeared in the sarcocysts from Florida panthers (Greiner et al., 1989).

There was an uneven distribution of the sarcocysts by organ site (Table 1). Of the 30 positive bobcats, 28 of 28 contained sarcocysts in the tongue (tongue was not available for the other two), while 10 of 27 (37%) and 8 of 26 (31%) were detected harboring sarcocysts in cardiac muscle and

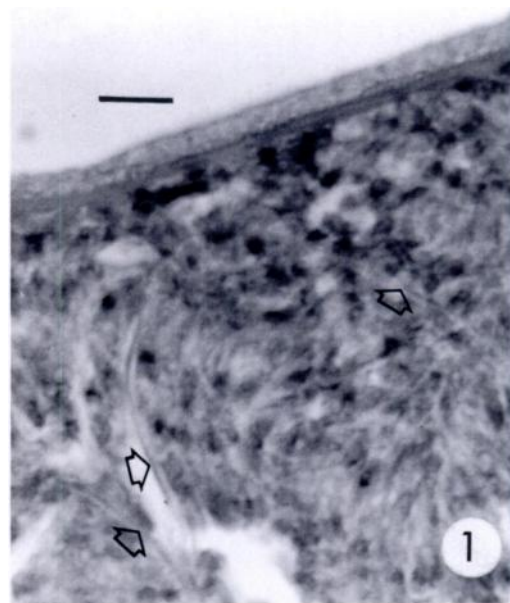


FIGURE 1. Section of mature sarcocyst showing septae (arrows) H&E. Bar =  $6 \mu\text{m}$ .

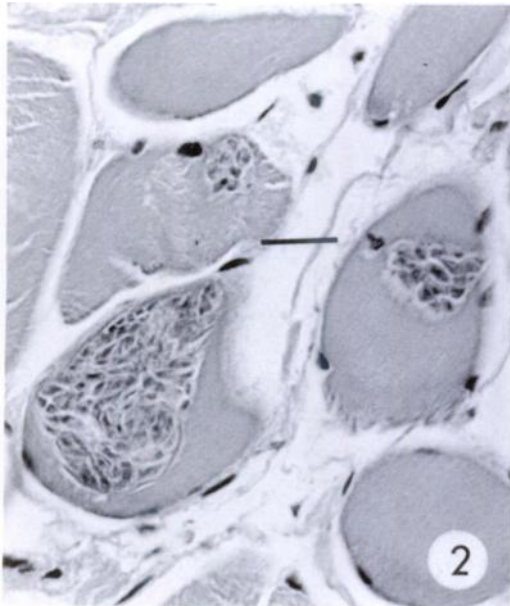


FIGURE 2. Section of young sarcocyst filled with merozoites H&E. Bar = 15  $\mu$ m.

diaphragm. Sample sizes for intestinal tunica muscularis and skeletal muscle were smaller, yet results showed one of five and one of four of the positive bobcats exam-

ined, respectively, contained sarcocysts in these tissues.

The prevalence of sarcocysts in the muscles of the tongue was significantly greater than in any other tissue examined ( $P < 0.005$ ) except for skeletal muscle ( $P = 0.25$ ). Comparisons between the other muscle tissue types yielded no significant difference ( $P > 0.4$ ). There were no significant differences in the distribution of *Sarcocystis* spp. in bobcats by county (Table 2) or between males and females ( $P = 0.17, 0.46$  respectively).

Prey items of the bobcat diet in Florida include rabbit (*Sylvilagus* spp.), cotton rat (*Sigmodon hispidus*), various other rodents and birds, and to a limited extent larger prey items such as raccoon (*Procyon lotor*), white-tailed deer (*Odocoileus virginianus*), and feral pig (*Sus scrofa*) (Maehr and Brady, 1986; M. E. Roelke, unpubl. data). The majority of these prey species are also components of the Florida panther diet (Roelke et al., 1986; Belden, 1987; Maehr et al., 1990), and may represent a common source of infection for

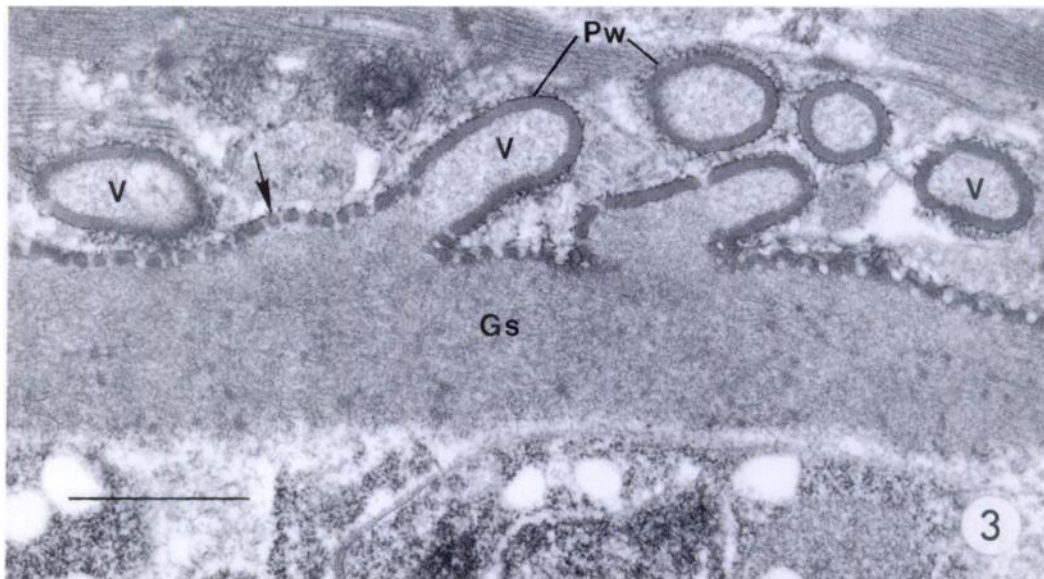


FIGURE 3. Transmission electron micrograph of a bobcat sarcocyst. The primary cyst wall (Pw) is folded into short, irregularly spaced villi (V). A thickened electron-dense layer beneath the primary cyst wall is modified into "hobnail"-like bumps (arrow). The ground substance (Gs) of the cyst wall consists of fine granules and fibrils. Bar = 1  $\mu$ m.

TABLE 1. Bobcat tissues examined for sarcocysts.

Tissue	Number bobcats examined		Prevalence	% of positives*
	Positive	Total		
Tongue	28	50	56%	100
Cardiac musc.	10	53	19%	37
Diaphragm	8	49	16%	31
Intestine	1	10	10%	20
Skeletal musc.	1	4	25%	25

\* This value reflects the percentage of the positive bobcats that contained sarcocysts in that tissue. Positive bobcats were those harboring sarcocysts in at least one of the tissues examined.

*Sarcocystis* sp. The degree of overlap in terms of quantity of these prey species eaten, however, is small. Maehr and Brady (1986) reported the presence of raccoon, feral pig, and white-tailed deer in the stomach contents of <2% of the bobcats sampled, while these three species constitute the major portion of the panther diet. This suggests that either the species of *Sarcocystis* infecting the bobcat is different from that in the panther, a minor prey item which is seldom eaten is the source of infection to both felids, or that transmission of the parasite is occurring in some other manner than via prey. One cannot exclude the potential that bobcats become

TABLE 2. Distribution of sarcocysts in Florida bobcats by county.

County in Florida	Total number <sup>a</sup>		Panther habitat <sup>b</sup>
	Positive/ examined		
Highlands	1/4		Yes
Glades	2/2		Yes
Hendry	4/6		Yes
Collier	21/41		Yes
Dade	1/2		Yes
Alachua	0/1		No
Duval	1/1		No
Lake	0/1		No
Lee	0/2		No
Total	30/60		

<sup>a</sup> Because there was no statistical difference in the prevalences in male and female bobcats, they were grouped into a single category.

<sup>b</sup> Panther habitat includes those areas in which panthers are currently known to reside.

infected through the ingestion of sporocysts through fecal contamination of food or water. The bobcat serves as an occasional prey species for the panther (O. Bass, pers. comm.), though due to the rare occurrence of this phenomenon, it is unlikely that it may have any effect on the common occurrence of this parasite in the muscles of either species.

Although immune suppression due to feline immunodeficiency virus (FIV) or feline panleucopenia virus (FPV) was suggested as a possible contributing cause for the presence of sarcocysts in the Florida panther, no such correlation could be made with the Florida bobcat. Of the 30 bobcats harboring sarcocysts, only 10 (33%) were shown to have a positive antibody titer for feline parvovirus indicating previous infection with the virus, and of those negative for *Sarcocystis*, 11 (38%) had positive titers for FPV (M. E. Roelke, unpubl. data; Roelke et al., 1986). Further, only 1 of 11 (9%) bobcats from southern Florida was positive for FIV (Barr et al., 1989). Though some other disease agent may have caused an immune suppression, neither infection with FPV nor FIV appears to be significantly correlated with the presence of sarcocysts in the bobcat. Unlike most of the sarcocyst infected domestic cats, the infected bobcats appeared healthy, with no apparent concurrent chronic diseases as reflected by physical condition and absence of gross pathologic lesions.

These results indicate that sarcocysts are prevalent in free-ranging Florida bobcats, and that it is distributed primarily in southern Florida (29 of 55 bobcats from southern counties versus 1 of 5 from northern counties). Furthermore, it is clear that the tongue serves as the best indicator tissue in determining the presence of sarcocysts in bobcats. The factors are unknown that allow sarcocysts to develop in carnivores such as bobcats. Further research on the mode of transmission of this species of *Sarcocystis* sp. in bobcats, and the role of the immune status and diseases such as FIV and FPV in the bobcat is nec-

essary to determine what these factors might be.

An interesting case has been presented recently that suggests some species of *Sarcocystis* are monoxenous. Matuschka and Bannert (1987) determined that feeding sarcocysts of *S. gallotiae* to canarian lizards (*Gallotia galloti*) resulted in completion of the entire cycle in this lizard. This phenomenon has not been demonstrated for mammalian hosts. One attempt to infect domestic kittens with sarcocysts from the Florida panther did not yield sporocyst production (Greiner et al., 1989). This experiment should be repeated to rule out that this species of *Sarcocystis* has the potential to complete its cycle in one host.

Primary funding for this project was provided by the Florida Game and Fresh Water Fish Commission and federal grant-in-aid funds administered through the U.S. Fish and Wildlife Service under section 6 of the Endangered Species Act of 1973 (PL No. 93-205), The Florida Panther Research and Management Trust Fund and the state of Florida non-game trust funds. We thank J. P. Dubey for confirming the presence of metrocytes in some of the sarcocysts. This paper is published as Florida Agricultural Experimentation Stations Journal Series Number R-01375.

#### LITERATURE CITED

- BARR, M. C., P. P. CALLE, M. E. ROELKE, AND F. W. SCOTT. 1989. Feline immunodeficiency virus infection in nondomestic felids. *Journal of Zoo and Wildlife Medicine* 20: 265-272.
- BELDEN, R. C. 1987. Florida panther recovery plan implementation—A 1983 progress report. *In* Cats of the world: Biology, conservation and management, S. D. Miller and D. D. Everett (eds.). Proceedings of the Second International Cat Symposium, Kingsville, Texas, pp. 159-172.
- DUBEY, J. P., C. A. SPEER, AND R. FAYER. 1989. Sarcocystosis of animals and man. CRC Press, Boca Raton, Florida, 215 pp.
- EDWARDS, J. F., M. D. FICKEN, P. J. LUTTGEN, AND M. S. FREY. 1988. Disseminated sarcocystosis in a cat with lymphosarcoma. *Journal of the American Veterinary Medical Association* 193: 831-832.
- EVERITT, J. I., E. J. BASGALL, S. B. HOOSER, AND K. S. TODD, JR. 1987. *Sarcocystis* sp. in the striated muscle of domestic cats, *Felis catus*. *Proceedings of the Helminthological Society of Washington* 54: 279-281.
- FIORI, M. G., AND H. E. LOWNDES. 1988. Histochemical study of *Sarcocystis* sp. cysts in gastrocnemius and soleus of the cat. *Parasitology Research* 75: 123-131.
- GREINER, E. C., M. E. ROELKE, C. T. ATKINSON, J. P. DUBEY, AND S. D. WRIGHT. 1989. *Sarcocystis* sp. in muscles of free-ranging Florida panthers and cougars (*Felis concolor*). *Journal of Wildlife Diseases* 25: 623-628.
- HILL, J. E., W. L. CHAPMAN, JR., AND A. K. PRESTWOOD. 1988. Intramuscular *Sarcocystis* sp. in two cats and a dog. *The Journal of Parasitology* 74: 724-727.
- KIRKPATRICK, C. E., J. P. DUBEY, M. H. GOLDSCHMIDT, J. E. SAIK, AND J. A. SCHMITZ. 1986. *Sarcocystis* sp. in muscles of domestic cats. *Veterinary Pathology* 23: 88-90.
- MAEHR, D. S., AND J. R. BRADY. 1986. Food habits of bobcats in Florida. *Journal of Mammalogy* 67: 133-138.
- , R. C. BELDEN, E. D. LAND, AND L. WILKINS. 1990. Food habits of panthers in Southwestern Florida. *The Journal of Wildlife Management* 54: 420-423.
- MATUSCHKA, F.-R., AND B. BANNERT. 1987. Cannibalism and autotomy as predator-prey relationship for monoxenous Sarcosporidia. *Parasitology Research* 74: 88-93.
- ROELKE, M. E., E. R. JACOBSON, G. V. KOLLIAS, AND D. J. FORRESTER. 1986. Medical management and biomedical findings on the Florida panther, *Felis concolor coryi*, 1 July 1985 to 30 June 1986. Annual Performance Report. Endangered Species Project E-1-10 7506. Florida Game and Fresh Water Fish Commission, Gainesville, Florida, 65 pp.

Received for publication 15 February 1991.