

Oronasal Squamous Cell Carcinoma in an African Hedgehog (*Erinaceidae albiventris*)

Authors: Rivera, Rachel Y. Reams, and Janovitz, Evan B.

Source: Journal of Wildlife Diseases, 28(1) : 148-150

Published By: Wildlife Disease Association

URL: <https://doi.org/10.7589/0090-3558-28.1.148>

BioOne Complete (complete.BioOne.org) is a full-text database of 200 subscribed and open-access titles in the biological, ecological, and environmental sciences published by nonprofit societies, associations, museums, institutions, and presses.

Your use of this PDF, the BioOne Complete website, and all posted and associated content indicates your acceptance of BioOne's Terms of Use, available at www.bioone.org/terms-of-use.

Usage of BioOne Complete content is strictly limited to personal, educational, and non - commercial use. Commercial inquiries or rights and permissions requests should be directed to the individual publisher as copyright holder.

BioOne sees sustainable scholarly publishing as an inherently collaborative enterprise connecting authors, nonprofit publishers, academic institutions, research libraries, and research funders in the common goal of maximizing access to critical research.

Oronasal Squamous Cell Carcinoma in an African Hedgehog (*Erinaceidae albiventris*)

Rachel Y. Reams Rivera and Evan B. Janovitz, Animal Disease Diagnostic Laboratory and the Department of Veterinary Pathobiology, Purdue University, West Lafayette, Indiana 47907, USA

ABSTRACT: Oronasal squamous cell carcinoma was diagnosed in an adult African hedgehog (*Erinaceidae albiventris*). Clinically, the carcinoma presented as a firm right maxillary swelling with deviation of the nose to the left. The carcinoma was attached to the hard palate and protruded into the oral cavity. At necropsy, the carcinoma appeared centered in the right maxillary sinus, and had replaced the maxilla and extended into the nasal cavity. Metastatic foci were not found.

Key words: Squamous cell carcinoma, hedgehog, *Erinaceidae albiventris*, oronasal neoplasm, case report.

On 16 January 1990, a firm swelling of the right cheek was observed in an adult (estimated 2-yr-old), wild-born, female African hedgehog housed at a local zoological park (West Lafayette, Indiana 47907, USA). In order to examine the oral cavity, the hedgehog was anesthetized with approximately 5 mg ketamine hydrochloride (Ketaset®, Bristol Laboratories, Syracuse, New York 13201, USA) by intramuscular injection. A fleshy mass was attached to the hard palate and protruded into the oral cavity. A biopsy of this mass was not obtained during this procedure.

A tentative diagnosis of an abscess prompted extraction of the right upper third incisor in order to promote drainage. The hedgehog was treated with penicillin G, procaine-penicillin G, benzathine (Flo-cillin®, Bristol Myers, Co., Pharmaceutical Research and Development Division, Wallingford, Connecticut 06492, USA) for 10 days.

On 29 January, the hedgehog became severely dyspneic and was euthanized by intracardiac injection of sodium pentobarbital. The carcass was frozen until 7 February when a necropsy was performed. The right maxillary region was swollen and the nose was deviated to the left (Fig. 1). A firm, white, poorly demarcated, invasive

mass, 1 cm in greatest dimension, was within the oral cavity extending from the palate (Fig. 2). The oral mucosa of the hard palate was ulcerated. On sectioning the head, the mass appeared centered in the right maxilla, extended into the nasal cavity and through the palatine bone, and replaced portions of the turbinate bones (Fig. 3). The nasal septum was deviated to the left. The mass had infiltrated the muscles overlying the right maxilla, but the skin was intact. No other masses were found.

Histologically, the mass was a squamous cell carcinoma. In one section of maxilla, the squamous cell carcinoma had isolated the root of an incisor. The neoplastic epithelial cells were well differentiated and formed irregularly branching cords and nests within abundant fibrous connective



FIGURE 1. Swelling of the right maxilla due to an oronasal squamous cell carcinoma in a hedgehog. The nose was deviated to the left.

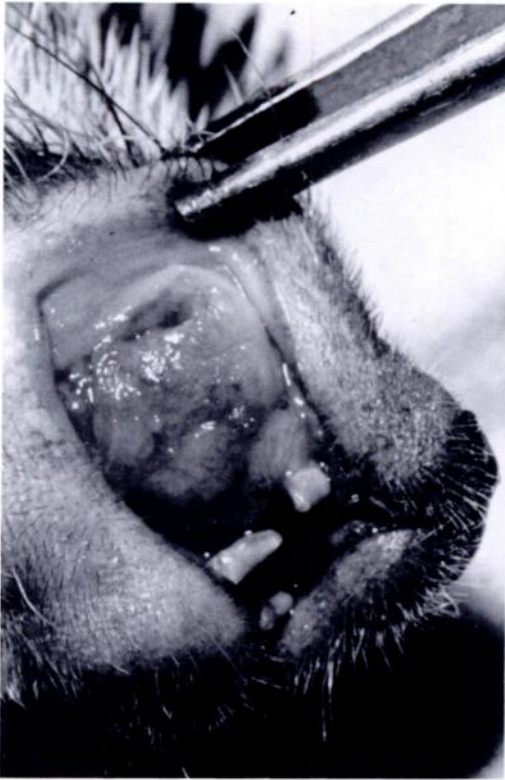

FIGURE 2. Oronasal squamous cell carcinoma protruding into the oral cavity from the maxilla and hard palate of a hedgehog.

tissue. These cells had abundant eosinophilic cytoplasm which, in many cells, was partially keratinized. Nuclei were round to oval and vesicular with one or two prominent nucleoli. Mitoses were infrequent (Fig. 4). Retropharyngeal lymph nodes were infiltrated by neutrophils (suppurative lymphadenitis), but there was no metastatic carcinoma. Additional findings were bilateral adrenal cortical hyperplasia and splenic extramedullary hematopoiesis.

Paraffin-embedded blocks containing representative tissue from the neoplasm were deposited in the Registry of Comparative Pathology (The Registry of Comparative Pathology, Armed Forces Institute of Pathology, Washington, D.C., 20306, AFIP accession number 2299398) and the Purdue Comparative Oncology Program (Purdue Comparative Pathology

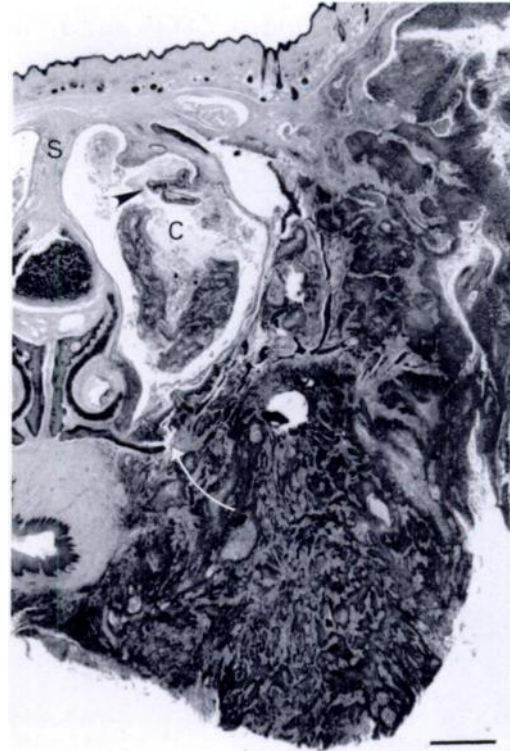


FIGURE 3. Oronasal squamous cell carcinoma in a hedgehog. The carcinoma was centered in the right maxilla and extended into the overlying soft tissues (upper left) and toward the oral mucosa (lower right). The palatine bone (arrow) was eroded and the carcinoma had entered the nasal cavity (C) where turbinates (arrow head) were atrophic and the nasal septum (S) was deviated. H&E (decalcified). Bar = 1 mm.

Program, Purdue School of Veterinary Medicine, Purdue University, West Lafayette, IN 47907, accession number R-16403).

Carcinomas of the nasal cavity or paranasal sinuses in nondomesticated animals are considered rare and few neoplasms of any kind have been reported in hedgehogs (Montali et al., 1983; Schmidt and Hubbard, 1987). We believe this is the first report of an oronasal squamous cell carcinoma in a hedgehog. Because the squamous cell carcinoma involved both nasal and oral cavities, its origin was not obvious. However, since the bulk of the carcinoma

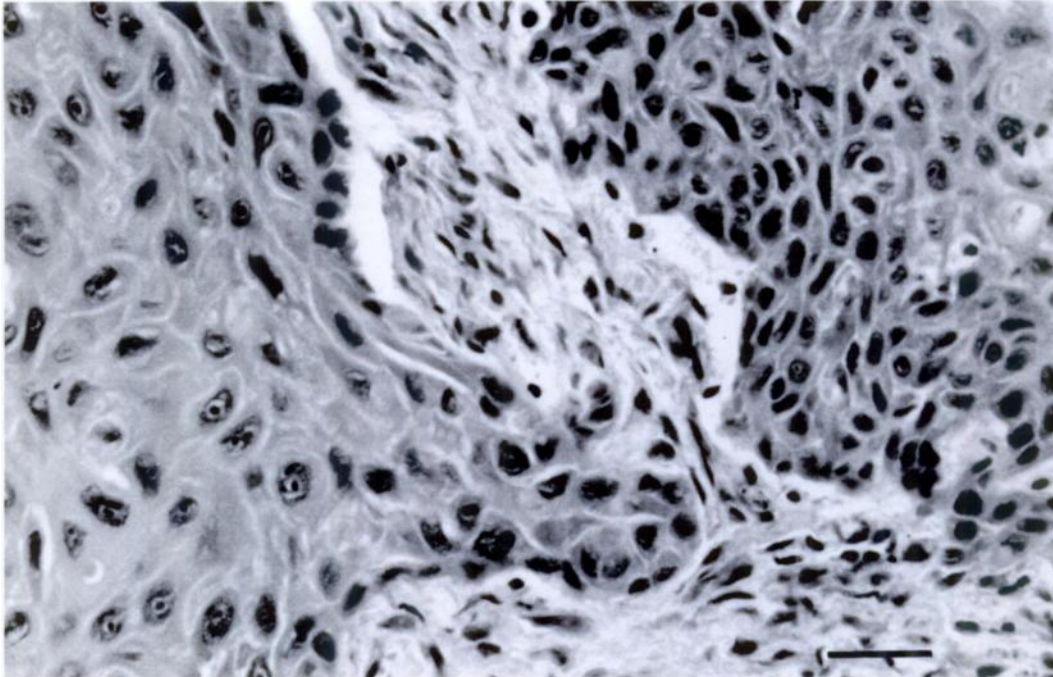


FIGURE 4. Sheets of neoplastic squamous epithelial cells surrounded by dense fibrous connective tissue from a oronasal carcinoma in a hedgehog. H&E (decalcified). Bar = 40 μ m.

involved the maxilla, it probably arose from the mucosa of the nasal cavity or paranasal sinus. The invasiveness of this squamous cell carcinoma was typical of oronasal carcinomas in domesticated species (Madwell et al., 1976; Moulton, 1990).

The authors thank Janiece Samman and Sam Royer for the excellent photomicrographs and Dr. T. C. Butler for submitting the case. This paper is submitted as journal paper number 12574, Purdue University, Agricultural Experiment Station (West Lafayette, Indiana 47907, USA).

LITERATURE CITED

- MADWELL, B. R., W. A. PRIESTER, E. L. GILLETTE, AND S. P. SNYDER. 1976. Neoplasms of the nasal passages and paranasal sinuses in domesticated animals as reported by 13 veterinary colleges. *American Journal of Veterinary Research* 37: 851-856.
- MONTALI, R. J., M. C. VALERIA, AND J. C. HARSHBARGER. 1983. Tumors of the nasal cavity in non-domesticated animals. *In* Nasal tumors in animals and man, Vol. 2, Tumor pathology, G. Reznik and S. F. Stinson (eds.). CRC Press, Inc., Boca Raton, Florida, pp. 239-254.
- MOULTON, J. E. 1990. Tumors of the respiratory system. *In* Tumors in domestic animals, 3rd ed., J. E. Moulton (ed.). University of California Press, Berkeley, California, pp. 308-346.
- SCHMIDT, R. E., AND G. B. HUBBARD. 1987. Atlas of zoo animal pathology, Vol. 1, Mammals. CRC Press, Inc., Boca Raton, Florida, 241 pp.

Received for publication 24 October 1990.