



THE RED-TAILED HAWK, BUTEO JAMAICENSIS, A NATIVE DEFINITIVE HOST OF FRENKELIA MICROTI (APICOMPLEXA) IN NORTH AMERICA

Authors: Upton, Steve J., and McKown, Richard D.

Source: Journal of Wildlife Diseases, 28(1) : 85-90

Published By: Wildlife Disease Association

URL: <https://doi.org/10.7589/0090-3558-28.1.85>

BioOne Complete (complete.BioOne.org) is a full-text database of 200 subscribed and open-access titles in the biological, ecological, and environmental sciences published by nonprofit societies, associations, museums, institutions, and presses.

Your use of this PDF, the BioOne Complete website, and all posted and associated content indicates your acceptance of BioOne's Terms of Use, available at www.bioone.org/terms-of-use.

Usage of BioOne Complete content is strictly limited to personal, educational, and non - commercial use. Commercial inquiries or rights and permissions requests should be directed to the individual publisher as copyright holder.

BioOne sees sustainable scholarly publishing as an inherently collaborative enterprise connecting authors, nonprofit publishers, academic institutions, research libraries, and research funders in the common goal of maximizing access to critical research.

THE RED-TAILED HAWK, *BUTEO JAMAICENSIS*, A NATIVE DEFINITIVE HOST OF *FRENKELIA MICROTI* (APICOMPLEXA) IN NORTH AMERICA

Steve J. Upton¹ and Richard D. McKown²

¹ Division of Biology and ² Department of Laboratory Medicine, Kansas State University, Manhattan, Kansas 66506, USA

ABSTRACT: Oral inoculation of prairie voles, *Microtus ochrogaster*, with coccidian sporocysts isolated from the feces of a red-tailed hawk, *Buteo jamaicensis*, in Kansas, USA, resulted in formation of *Frenkelia microti* (Apicomplexa: Sarcocystidae) tissue cysts in the brains of the voles. Five additional isolates of morphologically similar sporocysts collected from red-tailed hawks or other *Buteo* spp. in Kansas failed to result in detectable infections in rodents. These results are the first to verify that red-tailed hawks are natural definitive hosts in North America for *F. microti*.

Key words: Red-tailed hawk, *Buteo jamaicensis*, coccidia, *Frenkelia microti*, *Microtus ochrogaster*.

INTRODUCTION

Frenkelia microti (Findlay and Middleton, 1934) is a heteroxenous, tissue-cyst forming coccidian known to use the European buzzard, *Buteo buteo*, as the definitive host and rodents as intermediate hosts (Dubey et al., 1989). Tissue cysts form only in the central nervous system of the intermediate host, and become distinctly lobate and macroscopic. Although naturally infected intermediate hosts have been found in North America (Frenkel, 1953, 1955, 1956; Karstad, 1963; Bell et al., 1964; Hayden et al., 1976; Kennedy and Frelier, 1986), the definitive host of this parasite in North America is unknown because European buzzards do not occur in the Western hemisphere. Lindsay and Blagburn (1989) and Lindsay et al. (1987) have speculated that sporocysts found in the intestine of red-tailed hawks may represent *Frenkelia microti*, but experimental transmission data were lacking. Tadros and Laarman (1982) reported successfully infecting red-tailed hawks, *Buteo jamaicensis* (syn. *Buteo borealis jamaicensis*), with *F. microti* after feeding hawks infected European voles, *Microtus arvalis*. However, naturally infected red-tailed hawks never have been reported. We report here the discovery of a red-tailed hawk in Kansas, USA, naturally infected with *F. microti* and successful infections in prairie

voles, *Microtus ochrogaster*, after oral inoculation with sporocysts.

MATERIALS AND METHODS

Between February 1989 and December 1990, fecal samples were removed from cages of a variety of *Buteo* spp. undergoing treatment for a variety of traumatic ailments at the Kansas State University (KSU) College of Veterinary Medicine. In some cases, samples also were obtained from the lower portion of the intestine during necropsy. All samples were placed in 2.5% (w/v) aqueous K₂Cr₂O₇ solution and stored at 4 C for up to 1 wk prior to examination. Samples were examined for *Sarcocystis* spp. and *Frenkelia* spp. sporocysts by Nomarski interference contrast (NIC) microscopy following flotation in an aqueous sucrose solution (sp. gr. 1.30) (Current, 1990). Sporocysts were measured within 1 wk following discovery using a calibrated ocular micrometer and NIC optics. Fecal samples were strained through four layers of cheesecloth and sporocysts were washed three times in phosphate buffered saline (pH 7.4) by centrifugation within 1 wk of collection. Sporocysts were counted using a hemacytometer prior to inoculation into rodents by stomach tube.

The laboratory mice (*Mus musculus*) used were an ICR outbred strain purchased from Harlan Sprague-Dawley (Indianapolis, IN); they were 2- to 4-mo-old at the times of inoculation. White-footed mice, *Peromyscus leucopus*, all were F₃ generation animals and part of a 3-yr captive breeding colony at Kansas State University (KSU). These animals were 3- to 6-mo-old at the time of inoculation. Prairie voles, *Microtus ochrogaster*, also were part of a captive breeding colony at KSU and were 6- to 30-mo-old at the time of inoculation. All animals

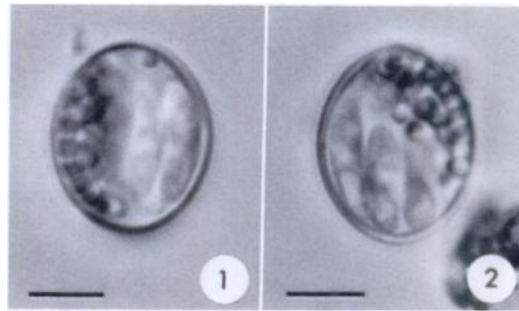
were housed in plastic cages with wood shavings for bedding and given water and a KSU rodent mash (ARF 3, Grain Sciences and Industry, KSU) ad libitum. Animals were placed on a 12-hr light/dark cycle and maintained at about 23 C both before and during experimental infections.

Rodents were examined at various intervals post-inoculation for sarcocysts and tissue cysts of *Frenkelia microti* (Table 1). All animals were euthanized using CO₂ overdose. Squash preparations of brain, tongue, heart, and thigh muscle were examined by NIC microscopy using 100× magnification. When tissue cysts were found (isolate SAR-13 only), one entire lateral hemisphere from the brain of each animal inoculated with SAR-13 was examined using squash preparations and NIC optics whereas the other half of the brain was fixed in neutral buffered formalin and prepared for paraffin embedding and histological sectioning. Sections were cut at 5.0 μm, stained using hematoxylin and eosin, and examined for tissue cysts using brightfield microscopy. Small portions of infected tissues sometimes were placed in 2.5% (v/v) glutaraldehyde for future transmission electron microscopy studies.

Necropsy examination of the red-tailed hawk with sporocysts of *Frenkelia microti* included the removal of 3 cm portions of the entire intestinal tract. Tissues were fixed in neutral buffered formalin for histopathological examination, dehydrated and embedded in paraffin, sectioned at 5.0 μm, and stained with hematoxylin and eosin.

RESULTS

Of all animals inoculated initially with sporocysts, only a single prairie vole inoculated with sporocysts from a red-tailed hawk (isolate SAR-13) became infected (Figs. 1–2, Table 1). The hawk that produced these sporocysts was an adult female, found near Manhattan, Kansas (39°15'N, 96°36'W), and submitted to the KSU College of Veterinary Medicine in November 1990. Preliminary examination revealed marked depression with hemorrhage from around the mouth and nares, tacky mucous membranes, and swelling around the right eye. Based on radiographs, pellet shot densities were observed adjacent to the proximal portion of the right ulna, in the neck, and in the head. With an ophthalmologic examination, it was noted that the right eye had a detached



FIGURES 1–2. Nomarski interference contrast photomicrographs of sporocysts of *Frenkelia microti* isolated from a red-tailed hawk, *Buteo jamaicensis*. Scale bars = 5.0 μm.

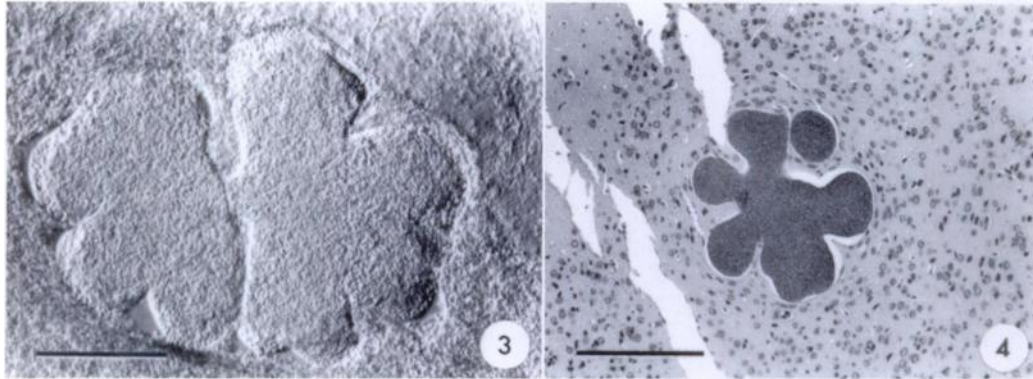
retina with retinal hemorrhage and the left eye had a cloud clot running horizontally through the vitreous humor. The birds had a packed cell volume of 33%, a total white count of 9,260 with a left shift (increased numbers of immature neutrophils), and low level *Leukocytozoon* sp. and *Hemoproteus* sp. infections. A fecal examination revealed *Capillaria* sp. ova and *Sarcocystis*-like sporocysts; the latter eventually were identified as *Frenkelia microti*. Despite supportive therapy, both intravenously and subcutaneously with lactated Ringer's solution and intramuscular injections of vitamin B complex, the bird was euthanized (Beuthanasia-D special, Schering-Plough Inc., Liberty Corner, NJ) 14 days after receipt. No additional lesions other than those related to gunshot trauma were observed at necropsy.

Lobate cysts identified as *Frenkelia microti* were found in the brain of the vole inoculated with isolate SAR-13 114 days post-inoculation (Table 1; Figs. 3, 4); sarcocysts were not observed in any of the other tissues examined. Mean measurements for 15 viable cysts in squash preparations were 577 × 463 μm (range 350 to 800 μm × 240 to 680 μm).

Some sporocysts remained viable up to 116 days. Low numbers of cysts were observed in the brain of a second vole inoculated with 9,000 sporocysts 63 days previously. Mean sizes for 10 viable cysts in these squash preparations were 238 ×

TABLE 1. Summary of six *Sarcocystis*/*Frenkelia* isolates collected from *Buteo* spp. 1989–90 and used to inoculate rodents.

Isolate	Host species	Sporocyst sizes [μm] (range)	Sporocyst shape index (length/width)	Rodent recipient	No. inoculated	Inoculation dose (no. sporocysts)	Sporocyst age (days)	Day examined (post-inoculation)
SAR-2	<i>Buteo jamaicensis</i>	14.0 × 10.2 (13.6 to 14.4 × 9.2 to 10.8)	1.4 (1.3 to 1.5)	<i>Mus musculus</i>	0/3	1,000	2	106
SAR-4	<i>Buteo swainsoni</i>	13.8 × 11.1 (12.8 to 14.4 × 10.4 to 11.6)	1.2 (1.2 to 1.3)	<i>Mus musculus</i>	0/2	1,000; 2,000	3	111
				<i>Microtus ochrogaster</i>	0/2	600; 1,200	3	111
SAR-9	<i>Buteo lagopus</i>	14.6 × 11.7 (13.6 to 16.0 × 10.8 to 12.2)	1.3 (1.1 to 1.4)	<i>Peromyscus leucopus</i>	0/2	600; 1,200	3	111
				<i>Microtus ochrogaster</i>	0/1	1,800	2	128
				<i>Peromyscus leucopus</i>	0/2	1,800	2	128
SAR-12	<i>Buteo jamaicensis</i>	13.8 × 10.9 (13.2 to 14.4 × 10.4 to 11.2)	1.3 (1.2 to 1.4)	<i>Microtus ochrogaster</i>	0/1	2,000	7	136
				<i>Peromyscus leucopus</i>	0/1	2,000	7	136
SAR-13	<i>Buteo jamaicensis</i>	13.7 × 11.3 (12.8 to 14.4 × 11.0 to 12.0)	1.2 (1.1 to 1.3)	<i>Microtus ochrogaster</i>	1/1	4,000	2	114
				<i>Microtus ochrogaster</i>	1/1	9,000	116	63
				<i>Microtus ochrogaster</i>	0/2	0 (controls)	—	—
				<i>Peromyscus leucopus</i>	0/2	4,500	116	63
SAR-14	<i>Buteo jamaicensis</i>	14.4 × 11.4 (13.6 to 15.2 × 10.8 to 12.0)	1.3 (1.2 to 1.4)	<i>Microtus ochrogaster</i>	0/1	1,000	2	114



FIGURES 3–4. Tissue cysts of *Frenkelia microti* in the brain of an experimentally infected prairie vole, *Microtus ochrogaster*, 114 days post-inoculation. Fig. 3. Nomarski interference contrast photomicrograph of viable tissue cyst in squash preparation. Fig. 4. Brightfield photomicrograph of tissue cyst in histological section, H & E stain. Scale bars = 200 μm .

193 μm (range 165 to 330 $\mu\text{m} \times 135$ to 264 μm). Both control animals, as well as two *Peromyscus leucopus*, each inoculated with 4,500 sporocysts, lacked detectable infections.

Numerous oocysts and sporocysts were observed in the anterior half of the small intestine of the red-tailed hawk (not shown). These oocysts and sporocysts were found in association with enterocytes at the distal end of the intestinal villi and in the lumen, and appeared to invoke little inflammation.

DISCUSSION

Two *Frenkelia* spp. currently are considered valid. *Frenkelia glareoli* (syn. *Frenkelia clethrionomyobuteonis* Rommel and Krampitz, 1975) has been found in Europe and uses buzzards, *Buteo buteo*, and rough-legged hawks, *Buteo lagopus*, as definitive hosts; it uses European bank voles, *Clethrionomys glareolus*, as intermediate hosts (Rommel and Krampitz, 1975; Krampitz et al., 1976; Krampitz and Rommel, 1977; Rommel et al., 1977; Geisel et al., 1978; Gobel et al., 1978; Tadros and Laarman, 1982). This species is characterized both by strict intermediate host specificity and by producing cysts in the central nervous system. These cysts are microscopic and divided into a large number of non-lobate compartments. *Fren-*

kelia microti (Findlay and Middleton, 1934) occurs in Europe, Japan, and North America and also uses buzzards as definitive hosts (Krampitz and Rommel, 1977). However, this species has a wide intermediate host range that includes not only new world and old world voles (*Microtus*, *Clethrionomys*), but also *Apodemus* spp. (old world wood and field mice), *Chinchilla laniger* (chinchilla), *Cricetus cricetus* (black-bellied hamster), *Erethizon dorsatum* (porcupine), *Lemmus lemmus* (Norway lemming), *Mastomys natalensis* (African soft-furred or multimammate rat), *Mesocricetus auratus* (golden hamster), *Mus musculus* (laboratory mouse), *Ondatra zibethica* (muskrat), *Oryctolagus cuniculus* (domestic rabbit), and *Rattus norvegicus* (Norway rats) (Findlay and Middleton, 1934; Frenkel, 1953, 1955, 1956; Jirovec et al., 1961; Karstad, 1963; Bell et al., 1964; Enemar, 1965; Tadros et al., 1972; Hayden et al., 1976; Krampitz and Rommel, 1977; Meingassner and Burtscher, 1977; Bestetti and Fankhauser, 1978; Rommel and Krampitz, 1978; Frenkel et al., 1979; Geisel et al., 1979; Tadros et al., 1972; Tadros and Laarman, 1982; Kennedy and Frelie, 1986; Fujita et al., 1988). Cysts are distinctive in that they are both macroscopic and highly lobate.

Sporocysts of *F. microti* in the present study measured 13.7 \times 11.3 μm (12.8 to

14.4 μm \times 11.0 to 12.0 μm) [shape index 1.2 (1.1–1.3)] and had a scattered sporocyst residuum. This differs somewhat from the reports of *F. microti* from *Buteo buteo* in Europe, where sporocysts were 12.2 \times 9.9 μm (11.7 to 14.6 μm \times 8.7–11.6 μm) (shape index calculated from mean 1.23) and had a spheroidal sporocyst residuum (Krampitz and Rommel, 1977). However, these differences are minor and we believe that the forms in Europe and North America should be regarded as the same species.

Although both *Buteo buteo* in Europe and *B. jamaicensis* in North America are appropriate definitive hosts for *F. microti*, neither species migrates between continents. This suggests that one or more other *Buteo* spp. may be suitable definitive hosts for *Frenkelia* spp. Tadros and Laarman (1982) have reported that the rough-legged hawk, *Buteo lagopus*, is a natural definitive host for *F. glareoli*. This hawk is circumarctic and, thus, represents an ideal candidate as a definitive host for *F. microti* as well. Since *F. glareoli* has never been found in North America, it is likely that the narrow intermediate host range of this coccidian limits its distribution whereas the wide intermediate host range of *F. microti* allows for a wide geographical distribution.

LITERATURE CITED

- BELL, J. F., W. L. JELLISON, AND L. GLESNE. 1964. Detection of *Toxoplasma microti* in living voles. *Experimental Parasitology* 15: 335–339.
- BESTETTI, VON G., AND R. FANKHAUSER. 1978. Doppelinfektion des Gehirns mit *Frenkelia* und *Toxoplasma* bei einem Chinchilla. Licht- und Elektronenmikroskopische Untersuchung. *Schweizer Archiv für Tierheilkunde* 120: 591–601.
- CURRENT, W. L. 1990. Techniques and laboratory maintenance of *Cryptosporidium*. In *Cryptosporidiosis of man and animals*, J. P. Dubey, C. A. Speer, and R. Fayer (eds.). CRC Press, Boca Raton, Florida, pp. 31–49.
- DUBEY, J. P., C. A. SPEER, AND R. FAYER. 1989. Sarcocystosis of animals and man. CRC Press, Boca Raton, Florida, 215 pp.
- ENEMAR, A. 1965. M-organisms in the brain of the Norway lemming, *Lemmus lemmus*. *Arkiv för Zoologi* 18: 9–16.
- FINDLAY, G. M., AND A. D. MIDDLETON. 1934. Epidemic disease among voles (*Microtus*) with special reference to *Toxoplasma*. *Journal of Animal Ecology* 3: 150–160.
- FRENKEL, J. K. 1953. Infections with organisms resembling *Toxoplasma*. VI Congresso Internazionale di Microbiologia, September 1953, Rome. Volume 2. Riassunti Delle Comunicazioni No. 764, Roma, pp. 556–557.
- . 1955. Infections with organisms resembling *Toxoplasma*, together with the description of a new organism: *Besnottia jellisoni*. Atti del VI Congresso Internazionale di Microbiologia, September 6–12, 1953, Roma. Volume 5, pp. 426–434.
- . 1956. Pathogenesis of toxoplasmosis and of infections with organisms resembling *Toxoplasma*. *Annals of the New York Academy of Sciences* 64: 215–251.
- , A. O. HEYDORN, H. MEHLHORN, AND M. ROMMEL. 1979. Sarcocystinae: *Nomina dubia* and available names. *Zeitschrift für Parasitenkunde* 58: 115–139.
- FUJITA, O., Y. OKU, AND M. OHBAYASHI. 1988. *Frenkelia* sp. from the red-backed vole, *Clethrionomys rufocanus bedfordiae*, in Hokkaido, Japan. *Japanese Journal of Veterinary Research* 36: 69–71.
- GEISEL, O., E. KAISER, H. E. KRAMPITZ, AND M. ROMMEL. 1978. Beiträge zum Lebenszyklus der Frenkelien. IV. Pathomorphologische Befunde an den Organen experimentell infizierter Rötelmäuse. *Veterinary Pathology* 15: 621–630.
- , O. VOGEL, H. E. KRAMPITZ, AND M. ROMMEL. 1979. Pathomorphologic findings in short-tailed voles (*Microtus agrestis*) experimentally-infected with *Frenkelia microti*. *Journal of Wildlife Diseases* 15: 267–270.
- GOBEL, E., M. ROMMEL, AND H. E. KRAMPITZ. 1978. Ultrastrukturelle Untersuchungen zur ungeschlechtlichen Vermehrung von *Frenkelia* in der Leber der Rötelmaus. *Zeitschrift für Parasitenkunde* 55: 29–42.
- HAYDEN, D. W., N. W. KING, AND A. S. K. MURTHY. 1976. Spontaneous *Frenkelia* infection in a laboratory-reared rat. *Veterinary Pathology* 13: 337–342.
- JIROVEC, O., Ž. ČERNÁ, J. LUDVÍK, AND Z. ŠEBEK. 1961. Der sogenannte M-organisms in Gehirn kleiner Nagetiere. *Wiadomości Parazytologiczne* 7: 875–879.
- KARSTAD, L. 1963. *Toxoplasma microti* (the M-organism) in the muskrat (*Ondatra zibethica*). *The Canadian Veterinary Journal* 4: 249–251.
- KENNEDY, M. J., AND P. F. FRELIER. 1986. *Frenkelia* sp. from the brain of a porcupine (*Erethizon dorsatum*) from Alberta, Canada. *Journal of Wildlife Diseases* 22: 112–114.
- KRAMPITZ, H. E., AND M. ROMMEL. 1977. Experimentelle Untersuchungen über das Wirtsspek-

- trum der Frenkelien der Erdmaus. Berliner und Münchener Tierärztliche Wochenschrift 90: 17-19.
- , O. GEISEL, AND E. KAISER. 1976. Beiträge zum Lebenszyklus der Frenkelien. II. Die ungeschlechtliche Entwicklung von *Frenkelia clethrionomyobuteonis* in der Rötelmaus. Zeitschrift für Parasitenkunde 51: 7-14.
- LINDSAY, D. S., AND B. L. BLAGBURN. 1989. *Caryospora uptoni* and *Frenkelia* sp.-like coccidial infections in red-tailed hawks (*Buteo borealis*). Journal of Wildlife Diseases 25: 407-409.
- , S. I. AMBRUS, AND B. L. BLAGBURN. 1987. *Frenkelia* sp.-like infection in the small intestine of a red-tailed hawk. Journal of Wildlife Diseases 23: 677-679.
- MEINGASSNER, J. G., AND H. BURTSCHER. 1977. Doppelinfection des Gehirns mit *Frenkelia* species und *Toxoplasma gondii* bei *Chinchilla laniger*. Veterinary Pathology 14: 146-153.
- ROMMEL, M., AND H. E. KRAMPITZ. 1975. Beiträge zum Lebenszyklus der Frenkelien. I. Die Identität von *Isospora buteonis* aus dem Mäusebussard mit einer Frenkelienart (*F. clethrionomyobuteonis* spec. n.) aus der Rötelmaus. Berliner und Münchener Tierärztliche Wochenschrift 88: 338-340.
- , AND ———. 1978. Weitere untersuchungen über das Zwischenwirtsspektrum und dem Entwicklungszyklus von *Frenkelia microti* aus der Erdmaus. Zentralblatt für Veterinärmedizin Reiche B 25: 273-281.
- , ———, AND O. GEISEL. 1977. Beiträge zum Lebenszyklus der Frenkelien. III. Die sexuelle Entwicklung von *F. clethrionomyobuteonis* im Mäusebussard. Zeitschrift für Parasitenkunde 51: 139-146.
- TADROS, W., AND J. J. LAARMAN. 1982. Current concepts on the biology, evolution and taxonomy of tissue cyst-forming eimeriid coccidia. In Advances in Parasitology 20: 293-468. Academic Press, London.
- , R. G. BIRD, AND D. S. ELLIS. 1972. The fine structure of cysts of *Frenkelia* (the M-organism). Folia Parasitologica (Praha) 19: 203-209.

Received for publication 24 June 1991.