

## **STARVATION, STAPHYLOCOCCOSIS, AND VITAMIN A DEFICIENCY AMONG MALLARDS OVERWINTERING IN SASKATCHEWAN**

Authors: Wobeser, G., and Kost, W.

Source: Journal of Wildlife Diseases, 28(2) : 215-222

Published By: Wildlife Disease Association

URL: <https://doi.org/10.7589/0090-3558-28.2.215>

---

The BioOne Digital Library (<https://bioone.org/>) provides worldwide distribution for more than 580 journals and eBooks from BioOne's community of over 150 nonprofit societies, research institutions, and university presses in the biological, ecological, and environmental sciences. The BioOne Digital Library encompasses the flagship aggregation BioOne Complete (<https://bioone.org/subscribe>), the BioOne Complete Archive (<https://bioone.org/archive>), and the BioOne eBooks program offerings ESA eBook Collection (<https://bioone.org/esa-ebooks>) and CSIRO Publishing BioSelect Collection (<https://bioone.org/csiro-ebooks>).

Your use of this PDF, the BioOne Digital Library, and all posted and associated content indicates your acceptance of BioOne's Terms of Use, available at [www.bioone.org/terms-of-use](http://www.bioone.org/terms-of-use).

Usage of BioOne Digital Library content is strictly limited to personal, educational, and non-commercial use. Commercial inquiries or rights and permissions requests should be directed to the individual publisher as copyright holder.

---

BioOne is an innovative nonprofit that sees sustainable scholarly publishing as an inherently collaborative enterprise connecting authors, nonprofit publishers, academic institutions, research libraries, and research funders in the common goal of maximizing access to critical research.

## STARVATION, STAPHYLOCOCCOSIS, AND VITAMIN A DEFICIENCY AMONG MALLARDS OVERWINTERING IN SASKATCHEWAN

G. Wobeser<sup>1</sup> and W. Kost<sup>2</sup>

<sup>1</sup> Department of Veterinary Pathology, Western College of Veterinary Medicine,  
University of Saskatchewan, Saskatoon, Saskatchewan, Canada S7N 0W0

<sup>2</sup> Saskatchewan Parks and Renewable Resources, 112 Research Drive,  
Saskatoon, Saskatchewan, Canada S7K 2H6

**ABSTRACT:** During January to March 1991, 38 mallards (*Anas platyrhynchos*) found dead from a group of approximately 600 overwintering on the South Saskatchewan River were examined. Thirty birds died from starvation, four had disseminated *Staphylococcus aureus* infection, and the cause of death of four birds was not determined. All six birds from which the esophagus was examined microscopically, including the four birds with staphylococcosis, had squamous metaplasia of the submucosal glands, a lesion pathognomonic for vitamin A deficiency. Vitamin A deficiency may occur in mallards and other waterfowl that overwinter north of traditional wintering areas and rely on grains deficient in carotenoids.

**Key words:** Starvation, vitamin A deficiency, *Staphylococcus*, winter, nutrition, mallard, *Anas platyrhynchos*.

### INTRODUCTION

Most waterfowl leave the Canadian prairies in autumn but small groups of ducks, particularly mallards (*Anas platyrhynchos*), attempt to overwinter where food is available and water is kept open by artificial turbulence below dams or by thermal pollution. This reflects a trend in recent years for mallards to winter north of their traditional wintering grounds (Jorde et al., 1983; Pederson et al., 1989). The largest and most long-standing such aggregation on the Canadian prairies is on the Bow River near Calgary (Alberta, Canada), where several thousand mallards have wintered for many years (Sugden et al., 1974). Little is known about the survival rate or causes of mortality among ducks wintering in such situations, but Sugden et al. (1974) calculated the annual mortality rate among mallards that wintered on the Bow River to be 47% and estimated that non-hunting mortality was relatively high in this group. Jorde et al. (1983) expressed the need for research "to measure the extent and causes of mallard mortality on northern wintering grounds and to more fully evaluate the significance of distribution, abundance, and quality of available food resources on survival." We re-

port causes of mortality in a group of mallards overwintering in Saskatchewan.

### MATERIALS AND METHODS

Diefenbaker Lake (51°17'N, 106°53'W) is an impoundment on the South Saskatchewan River created by a large earthfill dam. Several kilometers of river immediately downstream of the dam remain ice-free because of turbulence. Mallards have wintered on the open water for several years, feeding in adjacent grain fields. A 5-m-wide stream of runoff water from within the dam structure also remains open and joins the river about 300 m below the dam. This stream is used preferentially during cold weather as the water is warmer than that of the main channel. The size of the flock prior to 1991 was unknown but during January 1991 approximately 600 mallards were present. On 20 January, dead ducks were reported by a birdwatcher. The following day, a conservation officer found frozen carcasses of 30 mallards on the shore of the small stream. Approximately 400 ducks, all of which appeared normal, were present in the area. During the next 2 mo, 38 frozen carcasses, including 25 on 21 January, 8 on 8 February, 2 on 27 February and 3 on 13 March, were submitted to the Department of Pathology, Western College of Veterinary Medicine for examination. After thawing, intact carcasses were weighed and necropsies were performed on all specimens. Samples of lung from three intact birds collected 21 January, liver from all intact birds collected on 8 and 27 February, spleen, kidney and lung from three of the birds and heart valve from one bird collected 8 February, and ulnar

bone marrow from partial carcasses collected 27 February and 13 March, were submitted to the Diagnostic Bacteriology Laboratory, Department of Veterinary Microbiology, Western College of Veterinary Medicine. These tissues were inoculated onto 5% sheep blood agar and McConkey agar plates and incubated aerobically at 37 C. Bacteria isolated were identified on the basis of morphology and biochemical reactions (Carter and Cole, 1990).

Tissues for histopathology were fixed in neutral buffered 10% formalin, processed routinely, sectioned at 6  $\mu$  and stained with haematoxylin and eosin. Brown and Brenn stain (Luna, 1968) was used on selected tissues. Sections of liver, heart, spleen, lung, brain, pancreas, kidney, muscle and intestine were examined from ducks collected on 21 January and 8 February. Esophagus was not examined microscopically from birds collected on 21 January, but sections were examined from birds collected 8 and 27 February and 13 March.

Samples of liver from four birds collected 21 January and kidney from one bird collected 27 February were analyzed for lead using dry digestion and atomic absorption spectrophotometry (Prior, 1976) in the Diagnostic Toxicology Laboratory, Department of Veterinary Physiologic Sciences, Western College of Veterinary Medicine.

Weather records between 1 November 1990 and 28 February 1991 were obtained from the Environment Canada weather station at Elbow, Saskatchewan, approximately 20 km south of the site.

## RESULTS

Thirty of the 38 birds examined, including 25 from 21 January, 4 from 8 February, and 1 from 27 February, appeared to have died from starvation. All were severely emaciated with no visible fat and atrophy of skeletal muscles and visceral organs. The mean weight ( $\bar{x} \pm \text{SD}$ ) of 13 intact males and 12 intact females was  $759 \pm 89.6$  g and  $697 \pm 86.9$  g, respectively. Mean weight of the liver was  $10.2 \pm 1.9$  g for males and  $9.2 \pm 2.0$  g for females, and mean weight of both kidneys was  $5.3 \pm 0.7$  g for males and  $4.9 \pm 0.6$  g for females. The spleens were uniformly small ( $3 \times 10$  mm) and discoid. No ingesta were present within the alimentary tract of any bird. The lungs were edematous and the right ventricles were dilated. The only le-

sions detected microscopically were atrophy of hepatocytes, and edema and many bacteria in air spaces of the lungs. There was no inflammation in association with the bacteria, indicating that bacterial proliferation occurred terminally or post mortem. The mixture of bacteria isolated from the lungs of these birds, including *Corynebacterium* sp., *Enterobacter* sp., and *Pseudomonas* sp., was interpreted to result from post mortem contamination and/or terminal aspiration of water. A light growth of *Enterobacter* sp. and a few alpha *Streptococcus* sp. was isolated from the liver of a starved bird collected 27 February. One male considered to have starved also had lesions consistent with freezing. The distal portions of both feet were dry and necrotic and, on dissection, there was a distinct zone of hyperemia separating the necrotic and viable tissues of the foot.

Three intact males collected 8 February had less severe muscle wasting than birds that starved. The mean body weight ( $\bar{x} \pm \text{SD}$ ) of these males was  $920 \pm 118$  g and mean weight of liver and kidneys was  $38.9 \pm 13.7$  g and  $8.3 \pm 2.3$  g, respectively. Two of these birds had pale foci within the myocardium (Fig. 1) and one had fibrinous pericarditis. All three had vegetative endocarditis of the left atrio-ventricular valves (Fig. 2). Their spleens were globular and larger than those of the starved birds; pale foci were evident within the spleen of one bird. One bird had several sharply defined pale, friable foci, ranging from 0.5 to 2 cm in diameter, within the superficial pectoral muscles.

The three male birds had microscopic lesions varying from acute coagulation necrosis to chronic granulomas with abundant giant cells in myocardium, spleen, kidney, skeletal muscle and brain; these lesions were associated with Gram-positive coccoid bacteria. Septic thrombi were present in several organs. The foci in the pectoral muscles of one bird were infarcts with abundant bacterial growth about the margins. There was diffuse, subacute hepatitis in all three birds.

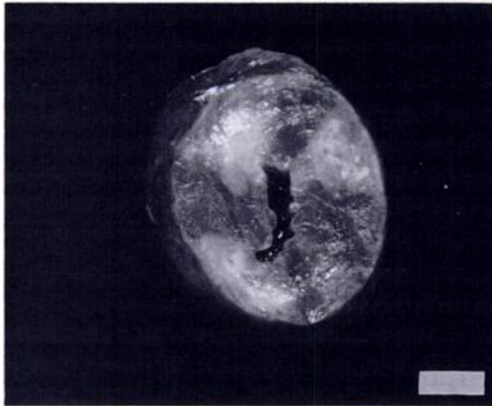


FIGURE 1. Cross-section of heart from mallard with staphylococcosis. Pale foci of fibrosis and necrosis are evident in the myocardium. (Bar = 5 mm.)

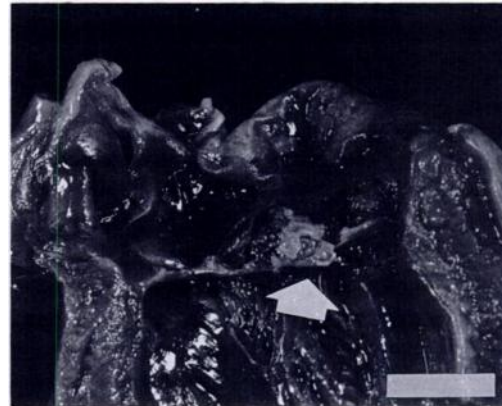

FIGURE 2. Opened left ventricle of the heart from a mallard. There are vegetative growths on the atrio-ventricular valves (arrow). *Staphylococcus aureus* was isolated from this material. (Bar = 1 cm.)

*Staphylococcus aureus* was isolated from liver of the birds with endocarditis but not from liver of the other four intact birds collected on 8 February. *Staphylococcus aureus* also was isolated from spleen and kidneys of birds with endocarditis, and from lung and heart valves of one bird. Other bacteria, including *Serratia* sp., *Lactobacillus* sp., *Yersinia enterocolitica*, *Vibrio fluvialis*, and gamma *Streptococcus* sp., isolated in small numbers from liver of birds collected 8 February (both those with endocarditis and those without), were considered to be contaminants. *Staphylococcus aureus* was isolated in pure culture from the bone marrow of a male collected 13 March. Only the head, neck, skeleton and wings were available for examination from this bird.

One male with staphylococcal infection had many raised, white, 0.5 to 1 mm foci in the esophageal mucosa (Fig. 3). These foci were the result of severe squamous metaplasia of the submucosal glands (Fig. 4). Similar but less severe microscopic changes were present in the esophagi of the other two birds with staphylococcal infections collected 8 February. Squamous metaplasia of the submucosal mucous glands also was found in the esophagus of one bird collected 27 February and two birds collected 13 March. Thus, all six birds

from which the esophagus was examined microscopically had squamous metaplasia of mucous glands, but only one had grossly visible changes in the esophagus.

No evidence was found of elevated tissue lead levels in tissues from birds collected on 21 January and 27 February. No cause of death could be established in four birds that had been scavenged extensively; no bacteria were isolated from bone marrow of these birds.

The mean daily temperature and the number of days in which the maximum daily temperature reached above freezing for each month were: November:  $-4.8^{\circ}\text{C}$ , 13 days above  $0^{\circ}\text{C}$ ; December:  $-17.6^{\circ}\text{C}$ , 5 days above  $0^{\circ}\text{C}$ ; January:  $-17.1^{\circ}\text{C}$ , 5 days above  $0^{\circ}\text{C}$ ; February:  $-5.2^{\circ}\text{C}$ , 11 days above  $0^{\circ}\text{C}$ . The ground was covered by at least 10 cm of snow continuously from 12 December to 5 February. Prior to the first reported mortality, there was a prolonged cold period from 16 December to 10 January during which the average daily minimum temperature was  $-30.1^{\circ}\text{C}$  (range  $-18.5$  to  $-39.5^{\circ}\text{C}$ ).

#### DISCUSSION

Three disease processes were identified in these birds but it was not possible to determine the sequence of events that occurred at the site. No systematic search

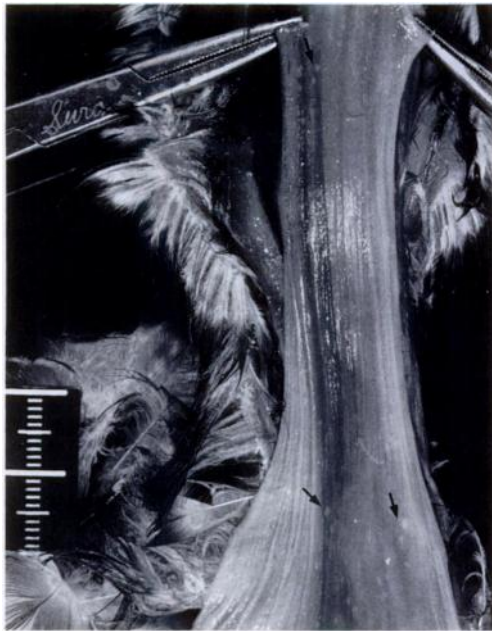

FIGURE 3. Esophagus of a mallard. Many tiny, raised, white foci are present in the mucosa (arrows). The microscopic appearance of these is shown in Figure 4. (Bar = 2 cm.)

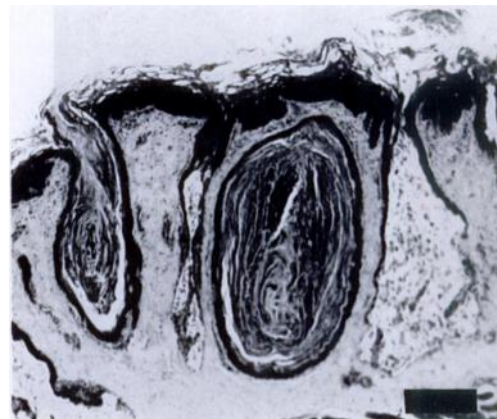


FIGURE 4. Submucosal glands of the esophagus filled with keratin as a result of severe squamous metaplasia of glandular epithelium. Haematoxylin-eosin. (Bar = 250  $\mu$ .)

was made along the river and scavengers were active at the site, so the birds found dead represented an unknown proportion of those that died.

Death from starvation is difficult to diagnose at necropsy because emaciation is a terminal event in many diseases. To make the diagnosis it is necessary to eliminate other likely explanations for emaciation and death. In this case, no gross lesions were seen to suggest other diseases and no evidence was found of lead poisoning. No pathogenic bacteria were isolated from birds considered to have starved. Body and organ weights are useful for quantifying the degree of emaciation present, and are reported for that purpose, but it is difficult to establish firm guidelines as to what constitutes a "starvation level." The degree of weight loss that occurs prior to death depends on the type of malnutrition (acute or chronic, partial or complete), rate of weight loss, and ambient conditions. Jordan (1953) found that air temperature in-

fluenced the extent of weight loss in experimentally-starved mallards. Drakes that died during "winter months" (temperature  $-3$  to  $2$  C) lost 45 to 50% of their original weight, whereas those dying during spring (average temperature  $13.9$  C) lost 50 to 55% of their body weight prior to death. Black ducks (*Anas rubripes*) that starved during winter lost 35 to 50% of "normal body weight" (Hagar, 1950). Loesch and Kaminski (1989) studied weight changes in female mallards maintained on various grains under Missouri winter conditions. Eight birds that died of starvation lost about 40% of their initial body weight prior to death. Tufted ducks (*Aythya fuligula*) and pochards (*A. ferina*), considered to have starved, lost 26 to 56% of normal body mass prior to death (Jenni-Eiermann and Schifferli, 1988). Sugden et al. (1974) weighed mallards on the Bow River in Alberta during January to March. If the average weight of those birds (female 1,051 g, male 1,214 g) is representative of normal winter weights of mallards on the Canadian prairies, males that died of starvation on the Saskatchewan River had lost about 37%, and females had lost about 34% of their body weights, respectively. However, Sugden et al. (1974) found dead ducks during each visit to the



Bow River as part of a “consistent but small loss of ducks that became too weak to obtain food,” so that the sample they weighed may have included emaciated birds. The mean weights ( $\bar{x} \pm \text{SD}$ ) of “after-hatching-year” mallards, collected during late October in Saskatchewan, were  $1,429 \pm 118$  g for males and  $1,237 \pm 108$  g for females (Greenwood et al., 1986). If these are considered normal, males and females that starved had lost 47% and 44% of body weight, respectively, at death. Mallards wintering on the Saskatchewan River may have been in unusually poor condition in the autumn of 1990. A small number of hunter-killed mallards examined by one of us (W.K.) on 13 and 15 December 1990, close to the site where birds were found dead about a month later, were noted to be thin. In addition to the severe cold prior to the first report of mortality, there was persistent snow cover in fields so that ducks likely had difficulty finding food. Whyte and Bolen (1984) calculated that adult mallards whose weights were similar to those of birds on the Bow River could survive on endogenous reserves for only 4 days if deprived of food at  $-20^\circ\text{C}$ .

Three birds collected 8 February had endocarditis and disseminated lesions caused by *Staphylococcus aureus*. A bird collected 13 March also had evidence of staphylococcal infection. *Staphylococcus aureus* is a common inhabitant of the skin and mucous membranes of animals (Gross, 1978) that may become a pathogen if it penetrates into deeper tissues. Staphylococcosis is relatively common in domestic poultry, particularly turkeys, resulting in osteomyelitis, arthritis, tendonitis, and occasionally septicemia (Gross, 1978). We are unaware of any report of staphylococcosis in wild ducks. Irwin (1975) reported one case in a lead-poisoned tundra swan (*Cygnus columbianus*). Staphylococcosis is a common problem among captive wild ducks, in our experience, resulting in arthritis, endocarditis and septicemia. We have observed an association between foot lesions and staphylococcosis in captive birds

and assume that the lesions provide a portal of entry for the bacterium. No foot injuries were observed in wild mallards with staphylococcosis; however, all of the birds had metaplastic changes in esophageal glands that may have provided a portal of entry.

All six birds from which the esophagus was examined microscopically had squamous metaplasia of mucous glands, a lesion pathognomonic for vitamin A deficiency in birds (Riddell, 1987). Unfortunately, liver tissue was not available for vitamin A analysis. Birds collected 21 January may have had similar lesions but the esophagus was not examined histologically. Squamous metaplasia of glands in the upper respiratory and digestive tract has been described in domestic ducks (Scott and Dean, 1991) and captive waterfowl (Wobeser, 1981). Hagar (1950) reported that black ducks, apparently dying of starvation, had lesions in the esophagus resulting from squamous metaplasia of submucosal glands. Although “there is no evidence, yet, to indicate the effects of a long-term, chronic deficiency of vitamin A in ducks” (Scott and Dean, 1991), deficiency of this vitamin in wild ducks may be important. Vitamin A has been termed the “anti-infection vitamin” (Sommer, 1990) because deficiency increases susceptibility of humans and other animals, including birds, to infectious diseases (Bang et al., 1973; Vyas and Chandra, 1984; Richter and Wiesner, 1987; Sijstma et al., 1989, 1990; Friedman et al., 1991). “Vitamin A functions in maintaining anatomical barriers of the body, suggesting that the primary nonspecific host defense in which vitamin A plays an essential role is the resistance of mucous membranes to microbial colonization, absorption of potentially dangerous antigens, or both” (Davis and Sell, 1989). Loss of this barrier may explain the occurrence of staphylococcosis in some mallards. Vitamin A also influences the systemic immune response. Vitamin A-deficient chickens have impaired antigen-specific antibody production and T lym-

phocyte proliferation in vitro (Friedman and Sklan, 1989), decreased antibody production (Davis and Sell, 1989), impaired cytotoxic T lymphocyte activity (Sijtsma et al., 1990), and are more susceptible to experimental infection with Newcastle disease virus (Sijtsma et al., 1989) and *Escherichia coli* (Friedman et al., 1991) than are vitamin A-sufficient birds. Friedman and Sklan (1989) reported that immune responsiveness was affected before there were other manifestations of vitamin deficiency. Thus, waterfowl on a vitamin A-deficient diet may be unusually susceptible to infections.

Vitamin A, obtained from the diet in the form of fat soluble retinyl esters from animal products and provitamin  $\beta$ -carotene from plants (Jetten et al., 1986), is stored in liver and other tissues. Signs of deficiency do not develop in adult chickens until 2 to 5 mo after being placed on a deficient diet (Scott et al., 1978). While yellow corn contains a small amount of carotenoids, cereal grains of the type available to birds in Saskatchewan contain none (Scott et al., 1982). Sugden and Driver (1980) reported that by mid-September most mallards in Saskatchewan were feeding on grain and the "average diet probably included less than 5% wetland foods." Birds wintering on the Saskatchewan River have little opportunity to obtain any food other than grain from November onward because other wetlands are frozen and there is a lack of organic substrate in the river. Natural food that may be available is likely depleted rapidly, as reported by Jorde et al. (1983) in a study of mallards overwintering in Nebraska. It is not surprising that birds collected during February and March had lesions of deficiency.

Dependence on cereal grains is not confined to the Canadian prairies or to mallards. Clark and Sugden (1990) found that more than 90% and 95%, respectively, of the energy needs of mallards and sandhill cranes (*Grus canadensis*) in western North America were supplied by grains between October and February. They echoed ear-

lier cautions by Baldassarre et al. (1983), Jorde et al. (1983), Delnicki and Reinecke (1986), and Miller (1987) that, despite being energy-rich, grains are deficient in specific nutrients. To our knowledge, the vitamin A status of waterfowl has not been examined anywhere in North America although many birds in northern locations feed on a grain diet (Pederson et al., 1989).

#### MANAGEMENT IMPLICATIONS

Death of a few mallards that chose to winter beyond the traditional wintering area had no direct impact on continental waterfowl populations. However, vitamin A deficiency may have implications for wintering waterfowl in other areas. Use of nutritionally deficient grain diets may reduce resistance to infection and could favor the occurrence of infectious disease among birds crowded under conditions that enhance exposure to disease agents. The relationship between diet and infection deserves investigation as part of the search for methods to reduce the impact of disease among wintering and migrating waterfowl.

#### ACKNOWLEDGMENTS

This investigation was supported by the Saskatchewan Department of Parks and Renewable Resources. Special assistance was given by Neil Laborde. Laboratory support by the Departments of Veterinary Microbiology, and Veterinary Physiological Sciences, Western College of Veterinary Medicine, is acknowledged, as are the helpful editorial comments by R. G. Clark and F. A. Leighton.

#### LITERATURE CITED

- BALDASSARRE, G. A., R. J. WHYTE, E. E. QUINLAN, AND E. G. BOLEN. 1983. Dynamics and quality of waste corn available to postbreeding waterfowl in Texas. *Wildlife Society Bulletin* 11: 25-31.
- BANG, B. G., M. A. FOARD, AND F. B. BANG. 1973. The effect of vitamin A deficiency and Newcastle disease on lymphoid cells. *Proceedings of the Society for Experimental Biology and Medicine* 143: 1140-1146.
- CARTER, G. R., AND J. R. COLE, JR. 1990. *Diagnostic procedures in veterinary bacteriology and mycology*, 5th ed. Academic Press Incorporated, San Diego, California, 620 pp.

- CLARK, R. G., AND L. G. SUGDEN. 1990. The importance of agricultural foods in the annual diet of mallard (*Anas platyrhynchos* L.) and sandhill crane (*Grus canadensis* L.). In *Granivorous birds in the agricultural landscape*, J. Pinowski and J. D. Summers-Smith (eds.). Intecol, Warszawa, Poland, pp. 317–331.
- DAVIS, C. Y., AND J. L. SELL. 1989. Immunoglobulin concentrations in serum and tissues of vitamin A-deficient broiler chicks after Newcastle disease virus vaccination. *Poultry Science* 68: 136–144.
- DELNICKI, D., AND K. J. REINECKE. 1986. Mid-winter food use and body weights of mallards and wood ducks in Mississippi. *The Journal of Wildlife Management* 50: 43–51.
- FRIEDMAN, A., AND D. SKLAN. 1989. Antigen-specific immune response impairment in the chick as influenced by dietary vitamin A. *Journal of Nutrition* 119: 790–795.
- , A. MEIDOVSKY, G. LEITNER, AND D. SKLAN. 1991. Decreased resistance and immune response to *Escherichia coli* infections in chicks with low or high intakes of vitamin A. *Journal of Nutrition* 121: 395–400.
- GREENWOOD, H., R. G. CLARK, AND P. J. WEATHERHEAD. 1986. Condition bias of hunter shot mallards (*Anas platyrhynchos*). *Canadian Journal of Zoology* 64: 595–601.
- GROSS, W. B. 1978. Staphylococcosis. In *Diseases of poultry*, 7th ed., M. S. Hofstad, B. W. Calnek, C. F. Helmboldt, W. M. Reid, and H. W. Yoder, Jr. (eds.). Iowa State University Press, Ames, Iowa, pp. 313–316.
- HAGAR, J. A. 1950. Black duck mortality in the Parker River region, winter of 1949–50. Massachusetts Division of Fisheries and Game, Bureau of Wildlife Research and Management, Amherst, Massachusetts, 17 pp.
- IRWIN, J. C. 1975. Mortality factors in whistling swans at Lake St. Clair, Ontario. *Journal of Wildlife Diseases* 11: 8–12.
- JENNI-EIERMANN, S., AND L. SCHIFFERLI. 1989. Body composition of starved tufted ducks *Aythya fuligula*, pochards *A. ferina* and little grebes *Tachybaptus ruficollis*. *Wildfowl* 40: 99–105.
- JETTEN, A. M., D. J. FITZGERALD, AND P. NETTESHEIM. 1986. Control of differentiation and proliferation of transformed airway epithelial cells by retinols. In *Current topics on nutrition and disease*, Vol. 15, D. G. Scarpelli and G. Migaki (eds.). Alan R. Liss, Inc., New York, pp. 33–70.
- JORDAN, J. S. 1953. Effects of starvation on wild mallards. *The Journal of Wildlife Management* 17: 304–311.
- JORDE, D. G., G. L. KRAPU, AND R. D. CRAWFORD. 1983. Feeding ecology of mallards wintering in Nebraska. *The Journal of Wildlife Management* 47: 1044–1053.
- LOESCH, C. R., AND R. M. KAMINSKI. 1989. Winter body-weight patterns of female mallards fed agricultural seeds. *The Journal of Wildlife Management* 53: 1081–1087.
- LUNA, L. G. 1968. Manual of histologic staining methods of the Armed Forces Institute of Pathology, 3rd ed. McGraw-Hill Book Co., New York, 258 pp.
- MILLER, M. R. 1987. Fall and winter foods of northern pintails in the Sacramento Valley, California. *The Journal of Wildlife Management* 51: 405–414.
- PEDERSON, R. L., D. G. JORDE, AND S. G. SIMPSON. 1989. Northern Great Plains. In *Habitat management for migrating and wintering waterfowl in North America*, L. M. Smith, R. L. Pederson, and R. M. Kaminski (eds.). Texas Tech University Press, Lubbock, Texas, pp. 281–310.
- PRIOR, M. G. 1976. Lead and mercury residues in kidney and liver of Canadian slaughter animals. *Canadian Journal of Comparative Medicine* 40: 9–11.
- RICHTER, G., AND J. WIESNER. 1987. Beziehung zwischen der Vitamin-A-Versorgung von Kuken und ihrer Disposition für Feldisolat von Eimeria tenella. *Monatsschrift für Veterinärmedizin* 42: 895–896.
- RIDDELL, C. 1987. Avian histopathology. American Association of Avian Pathologists, New Bolton Center, Kennett Square, Pennsylvania, 152 pp.
- SCOTT, M. L., AND W. F. DEAN. 1991. Nutrition and management of ducks. M. L. Scott of Ithaca, Ithaca, New York, 177 pp.
- , R. E. AUSTIC, AND C. L. GRIES. 1978. Nutritional deficiency diseases. In *Diseases of poultry*, 7th ed., M. S. Hofstad, B. W. Calnek, C. F. Helmboldt, W. M. Reid, and H. W. Yoder, Jr. (eds.). Iowa State University Press, Ames, Iowa, pp. 49–78.
- , M. C. NESHEIM, AND R. J. YOUNG. 1982. Nutrition of the chicken, 3rd ed. M. L. Scott & Associates, Ithaca, New York, 555 pp.
- SIJTSMA, S. R., C. E. WEST, J. H. W. M. ROMBOUT, AND A. J. VAN DER ZIJPP. 1989. The interaction between vitamin A status and Newcastle disease virus infection in chickens. *Journal of Nutrition* 119: 932–939.
- , J. H. W. M. ROMBOUT, C. E. WEST, AND A. J. VAN DER ZIJPP. 1990. Vitamin A deficiency impairs cytotoxic T lymphocyte activity in Newcastle disease virus-infected chickens. *Veterinary Immunology and Immunopathology* 26: 191–200.
- SOMMER, A. 1990. Vitamin A status, resistance to infection, and childhood mortality. *Annals of the New York Academy of Sciences* 587: 17–23.
- SUGDEN, L. G., AND E. A. DRIVER. 1980. Natural foods of mallards in Saskatchewan parklands during late summer and fall. *The Journal of Wildlife Management* 44: 705–709.
- , W. J. THURLOW, R. D. HARRIS, AND K. VERMEER. 1974. Investigations of mallards over-



- wintering at Calgary, Alberta. *Canadian Field-Naturalist* 88: 303-311.
- VYAS, D., AND R. K. CHANDRA. 1984. Vitamin A and immunocompetence. *In* Nutrition, disease resistance, and immune function, R. R. Watson (ed.). Marcel Dekker, Inc., New York, pp. 325-343.
- WHYTE, R. J., AND E. G. BOLEN. 1984. Impact of winter stress on mallard body composition. *The Condor* 86: 477-482.
- WOBESER, G. 1981. *Diseases of wild waterfowl*. Plenum Press, New York, 300 pp.
- Received for publication 20 May 1991.*