

Chlamydiosis in a Red-tailed Hawk (*Buteo jamaicensis*)

Authors: Mirandé, L. A., Howerth, E. W., and Poston, R. P.

Source: Journal of Wildlife Diseases, 28(2) : 284-287

Published By: Wildlife Disease Association

URL: <https://doi.org/10.7589/0090-3558-28.2.284>

BioOne Complete (complete.BioOne.org) is a full-text database of 200 subscribed and open-access titles in the biological, ecological, and environmental sciences published by nonprofit societies, associations, museums, institutions, and presses.

Your use of this PDF, the BioOne Complete website, and all posted and associated content indicates your acceptance of BioOne's Terms of Use, available at www.bioone.org/terms-of-use.

Usage of BioOne Complete content is strictly limited to personal, educational, and non - commercial use. Commercial inquiries or rights and permissions requests should be directed to the individual publisher as copyright holder.

BioOne sees sustainable scholarly publishing as an inherently collaborative enterprise connecting authors, nonprofit publishers, academic institutions, research libraries, and research funders in the common goal of maximizing access to critical research.

Chlamydiosis in a Red-tailed Hawk (*Buteo jamaicensis*)

L. A. Mirandé,¹ E. W. Howerth,^{2,3} R. P. Poston,² ¹ Department of Epidemiology and Community Health, School of Veterinary Medicine, Louisiana State University, Baton Rouge, Louisiana 70803, USA; ² Louisiana Veterinary Medical Diagnostic Laboratory, School of Veterinary Medicine, Louisiana State University, Baton Rouge, Louisiana 70803, USA; ³ Current address, Department of Pathology, College of Veterinary Medicine, The University of Georgia, Athens, Georgia 30602, USA

ABSTRACT: A red-tailed hawk (*Buteo jamaicensis*) with signs of respiratory distress and diarrhea was captured in the Manchac Wildlife Management Area, Louisiana (USA) and died the following day. At necropsy, the carcass was emaciated and there were splenomegaly, and fibrinous pericarditis, airsacculitis, and perihepatitis. Microscopically, there were fibrinous pericarditis and airsacculitis, myocardial necrosis, necrotizing hepatitis, splenic necrosis with reticuloendothelial cell hyperplasia, interstitial pneumonia and focal pancreatic necrosis. Intracytoplasmic chlamydial inclusion bodies were noticed in macrophages in the fibrinous exudate covering air sac and pericardium, and in spleen, liver, heart, lung, and pancreas. Schizonts compatible with a *Sarcocystis* sp.-like protozoon were present in the walls of air capillaries in the lung. A *Chlamydia* sp.-like organism was isolated in embryonating chicken eggs and cell culture and identified as *C. psittaci* with immunofluorescent staining.

Key words: Chlamydiosis, *Chlamydia psittaci*, ornithosis, sarcocystosis, *Sarcocystis* spp., red-tailed hawk, *Buteo jamaicensis*, falconiformes, case report.

Chlamydiosis is a naturally occurring, contagious, systemic disease of birds and mammals, including man. It is caused by the obligate intracellular bacterium *Chlamydia psittaci*, the numerous strains of which are known to vary in their pathogenicity for different avian and mammalian hosts (Page and Grimes, 1984). Infection has been documented in over 140 wild bird species representing at least 17 orders. Psittaciformes, Passeriformes, Charadriiformes, Anseriformes, and Columbiformes have been most extensively studied and include 76% of the recorded cases (Burkart and Page, 1971; Keymer, 1974).

Information on the prevalence of chlamydial infection in free-living birds of prey is limited. In an extensive survey for chlamydial infection in birds along the Cas-

pian Sea (USSR) 6 species of Falconiformes, including the European black vulture (*Aegypius monachus*), black kite (*Milvus korschun*), common kestrel (*Falco tinnunculus*), northern harrier (*Circus cyaneus*), marsh harrier (*Circus aeruginosus*), and common buzzard (*Buteo buteo*), and a single species of Strigiformes, the short-eared owl (*Asio flammeus*), were seropositive for *C. psittaci* on the complement fixation test (cited in Burkart and Page, 1971). In a serosurvey for chlamydial infection in birds of prey in France, 16 positive and five suspect reactors were found by complement fixation among 65 serum samples from raptors of unspecified species (Lepoutre et al., 1983). With the exception of a report of chlamydiosis in a bald eagle (*Haliaeetus leucocephalus*) (Brand, 1989), reports of clinical chlamydiosis in free-living raptors are lacking. The present study describes a case of chlamydiosis in a free-living red-tailed hawk (*Buteo jamaicensis*).

An immature female red-tailed hawk was found alive on 1 March 1989 on a canal within the Manchac Wildlife Management Area, St. John Parish, Louisiana (30°13'N, 90°25'W). The bird was alert but unable to fly and showed signs of respiratory distress. Evidence of diarrhea was present at the site of collection. The bird died the day following capture. On 3 March, the carcass was submitted to the School of Veterinary Medicine (Louisiana State University, Baton Rouge, Louisiana 70803, USA) by the Louisiana State Department of Wildlife and Fisheries for necropsy.

At necropsy, the carcass was extremely emaciated and there was severe pediculosis. The pericardium and air sacs were

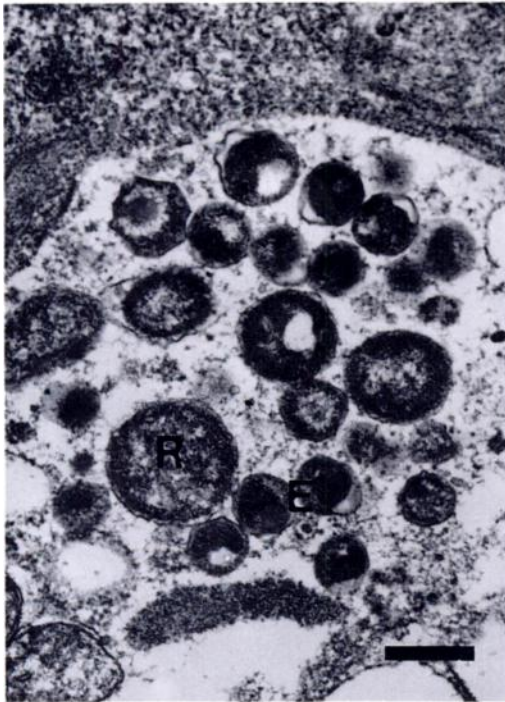


FIGURE 1. Transmission electron micrograph of lung of a red-tailed hawk. *Chlamydia psittaci* inclusion containing elementary (E) and reticulate bodies (R). Bar = 4.5 μ m.

thickened, opaque, and covered by fibrinous exudate. The liver was covered by fibrinous exudate, and there was splenomegaly.

Representative samples of trachea, air sac, lung, heart, pericardium, liver, spleen, kidney, and pancreas were fixed in 10% buffered formalin solution for histologic examination and stained with hematoxylin and eosin. Paraffin-embedded lung was deparaffinized and processed for transmission electron microscopy. Liver samples and swabs of pericardium and cloaca were routinely cultured for aerobic bacteria. Impression smears of liver were stained with Gimenez to identify chlamydial organisms. For chlamydial isolation, liver was homogenized and inoculated into 6-day old embryonating chicken eggs. Yolk sac was harvested from embryos with evidence of infection, homogenized, and subpassaged onto Vero cells. Cell cul-

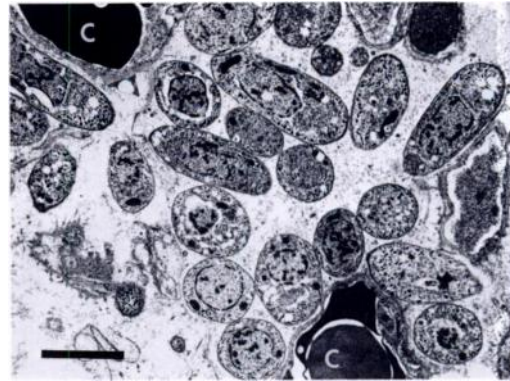


FIGURE 2. Transmission electron micrograph of schizont of *Sarcocystis* sp.-like protozoon in lung. Merozoites lie free in the cytoplasm of an unidentified cell in the wall of an air capillary and are not surrounded by a parasitophorous vacuolar membrane. The parasitized cell lies between two capillaries (C). Merozoites contain a large nucleus and numerous micronemes. Bar = 2.5 μ m.

tures were stained with *C. psittaci* fluorescent antibody conjugate (National Veterinary Services Laboratory, Ames, Iowa 50010, USA) at 72 hr post inoculation. Lead levels in formalin-fixed liver and kidney were determined by atomic absorption.

Microscopically, lesions were seen in the air sacs, pericardium, heart, liver, spleen, lung and pancreas. The air sacs and pericardium were covered by fibrinous exudate admixed with macrophages which contained basophilic intracytoplasmic chlamydial inclusion bodies. A similar exudate with macrophages containing chlamydial inclusion bodies covered the epicardium. The myocardial interstitium was hypercellular and some interstitial cells contained chlamydial organisms; multiple foci of myocardial necrosis were present. Diffuse hepatocellular vacuolar degeneration, multiple foci of necrosis often infiltrated with macrophages or mixed inflammatory cells, and mixed cellular perivascular infiltrations were present in liver. Sinusoidal lining cells were prominent and most sinusoidal lining cells, as well as many cells in the necrotic foci, contained chlamydial inclusion bodies. Reticuloendothelial cell hyperplasia, lym-

phoid necrosis, and necrotic cellular debris were noticed in spleen. Numerous reticuloendothelial cells in the spleen contained chlamydial organisms. In the lung, there was perivascular edema with thickening of air capillary walls and macrophage accumulation in the air capillary lumens. Many pulmonary macrophages contained chlamydial organisms. In addition, single merozoites and schizonts which were compatible with a *Sarcocystis*-like protozoon were present in air capillary walls. A focus of necrosis infiltrated with macrophages containing chlamydial organisms was noticed in the pancreas.

Intracellular organisms compatible with *Chlamydia* spp. (Fig. 1) (Wyrick and Richmond, 1989) and a *Sarcocystis* sp.-like organism (Fig. 2) (Dubey et al., 1989) were observed in the lung by transmission electron microscopy. Merozoites, either single or as groups in a schizont, of the *Sarcocystis* sp.-like organism were found free within the cytoplasm of cells in the air capillary walls and were not surrounded by a parasitophorous vacuolar membrane. Parasitized cells could not be identified but were in close proximity to vessels. The merozoites contained numerous micronemes but lacked rhoptries.

Chlamydia sp.-like organisms were observed in Gimenez-stained impression smears of liver and Giemsa-stained impression smears of yolk sac from eggs inoculated with liver. The organism was identified as *C. psittaci* in cell culture with immunofluorescent staining. No bacterial growth was obtained from the liver and pericardium and only the usual intestinal flora grew from the cloacal swab. Levels of lead in liver (0.40 ppm) and kidney (0.28 ppm) were considered insignificant (Reiser and Temple, 1981).

The paucity of reports of chlamydiosis in free-living birds of prey suggests that raptors are relatively resistant to disease caused by chlamydial infection. However, an epizootic of chlamydiosis in captive raptors has been described recently (Fowler et al., 1990). Several red-tailed hawks

which died during the epizootic had lesions similar to the hawk in this report.

The source of chlamydial infection in this bird is unknown. Red-tailed hawks, especially immature birds, prey mainly on mice and other small rodents (Brown and Amadon, 1968), but birds are occasionally consumed (Sprunt, 1955). A large colony of domestic pigeons (*Columbia livia*) roosts under a bridge near the site where this hawk was collected. As domestic pigeons are frequently infected with *Chlamydia* sp., they could represent the source of infection for this hawk. Another red-tailed hawk with similar signs was captured in the same vicinity a week previously but escaped from captivity.

The *Sarcocystis* sp.-like organism may have been responsible for some of the changes in the lung and may have contributed to the pulmonary insufficiency. *Sarcocystis* spp. was reported in skeletal muscle of an immature female red-tailed hawk, but no clinical significance was established (Ward, 1975).

Although the incidence of chlamydiosis in raptors appears to be low, falconers and the staffs of raptor rehabilitation units should exercise caution when handling sick birds or engaging in activities requiring close contact with raptors. The wildlife agent who found this bird developed influenza-like symptoms 7 days after handling the bird. Although this individual is suspected to have contracted chlamydiosis from this bird, a diagnosis of chlamydiosis was not confirmed.

The authors thank Mary Ard for assistance with electron microscopy and photography.

LITERATURE CITED

- BRAND, C. J. 1989. Chlamydia infections in free-living birds. *Journal of the American Veterinary Medical Association* 195: 1531-1535.
- BROWN, L., AND D. AMADON. 1968. Eagles, hawks and falcons of the world, Vol. 2. McGraw-Hill Book Co., New York, New York, 945 pp.
- BURKART, R. L., AND L. A. PAGE. 1971. Chlamydiosis. In *Infectious and parasitic diseases of wild birds*, J. W. Davis, R. C. Anderson, L. Karstad,

- and D. D. Trainer (eds.). Iowa State University Press, Ames, Iowa, pp. 118–140.
- DUBEY, J. P., C. A. SPEER, AND R. FAYER. 1989. Sarcocystosis in animals and man. CRC Press, Inc., Boca Raton, Florida, 215 pp.
- FOWLER, M. E., T. SCHULZ, A. ARDANS, B. REYNOLDS, AND D. BEHYMER. 1990. Chlamydiosis in captive raptors. *Avian Diseases* 34: 657–662.
- KEYMER, I. F. 1974. Ornithosis in free-living and captive birds. *Proceedings of the Royal Society of Medicine* 67: 733–735.
- LEPOUTRE, D., J. BARRAT, M. GUITET, AND J. BLANCOU. 1983. Contributions a l'etude de la biologie de quelques rapaces en France. *Revue de Medecine Veterinaire* 134: 481–493.
- PAGE, L. A., AND J. E. GRIMES. 1984. Avian chlamydiosis. In *Diseases of poultry*, 8th ed., H. J. Barnes, B. W. Calnek, W. M. Reid, and H. W. Yoder (eds.). Iowa State University Press, Ames, Iowa, pp. 283–308.
- REISER, M. H., AND S. A. TEMPLE. 1981. Effects of chronic lead ingestion on birds of prey. In *Recent advances in the study of raptor diseases*, J. E. Cooper and A. G. Greenwood (eds.). *Proceedings of the International Symposium on Diseases of Birds of Prey*, London, 1980. Chiron Publications, Keighley, West Yorkshire, United Kingdom, pp. 21–25.
- SPRUNT, A. 1955. *North American birds of prey*. Harper and Brothers, New York, New York, 227 pp.
- WARD, F. P. 1975. A clinical evaluation of parasites of birds of prey. *Journal of Zoo Animal Medicine* 6: 3–8.
- WYRICK, P. B., AND S. J. RICHMOND. 1989. Biology of chlamydiae. *Journal of the American Veterinary Medical Association* 195: 1507–1512.

Received for publication 29 August 1990.