



Cranial Asymmetry in a Dall Sheep Ram (*Ovis dalli dalli*)

Authors: Hoefs, M., and Bunch, T. D.

Source: Journal of Wildlife Diseases, 28(2) : 330-332

Published By: Wildlife Disease Association

URL: <https://doi.org/10.7589/0090-3558-28.2.330>

BioOne Complete (complete.BioOne.org) is a full-text database of 200 subscribed and open-access titles in the biological, ecological, and environmental sciences published by nonprofit societies, associations, museums, institutions, and presses.

Your use of this PDF, the BioOne Complete website, and all posted and associated content indicates your acceptance of BioOne's Terms of Use, available at www.bioone.org/terms-of-use.

Usage of BioOne Complete content is strictly limited to personal, educational, and non - commercial use. Commercial inquiries or rights and permissions requests should be directed to the individual publisher as copyright holder.

BioOne sees sustainable scholarly publishing as an inherently collaborative enterprise connecting authors, nonprofit publishers, academic institutions, research libraries, and research funders in the common goal of maximizing access to critical research.

Cranial Asymmetry in a Dall Sheep Ram (*Ovis dalli dalli*)

M. Hoefs,¹ and T. D. Bunch,² ¹Yukon Fish and Wildlife Branch, P.O. Box 2703, Whitehorse, Yukon, Canada, Y1A 2C6; ²Department of Animal, Dairy and Veterinary Sciences, Utah State University, Logan, Utah 84322, USA

ABSTRACT: The horns of a 13-yr-old Dall sheep ram (*Ovis dalli dalli*) from the Sheep Mountain herd in Kluane National Park (Yukon, Canada) had unique characteristics. The right horn was 1,127 mm long, while the left horn was only 861 mm long and compressed and distorted at its base. The reduced growth of the left horn was due to chronic epidermitis and osteomyelitis of the cornual process, which began when the ram was 5 yr of age.

Key words: Dall sheep, *Ovis dalli dalli*, horn aberration, skull infection, case report.

On 1 July 1990, the skull of a Dall sheep ram (*Ovis dalli dalli*) was found at the base of Sheep Mountain in Kluane National Park, Yukon, Canada (61°10'N, 138°35'W). The skull was severely damaged but both horns were intact. The ram had been well known to Parks staff because of its unique asymmetric horn characteristics (Fig. 1). The ram disappeared during the winter of 1989-90.

The Sheep Mountain population in Kluane Park has been under surveillance for over 20 yr (Hoefs and Bayer, 1983). More than 250 different rams in this herd have been observed, and the skulls of 118 have been recovered and analyzed. Horn deformities have been documented in Dall sheep (Hoefs et al., 1982; Bunch et al., 1984). However, the type of asymmetry reported in the current case had not been observed in hundreds of live animals or skulls previously evaluated.

The horn annulus technique (Geist, 1966) was used to estimate the ram's age at 13 yr. This is the maximum age rams obtain in this population (Hoefs and Bayer, 1983). The right horn was 1,127 mm long. This is the longest horn ever documented in this herd ($n = 118$). The left horn was only 861 mm long and was compressed and distorted at its base. Neither horn

showed significant brooming of the lamb tip.

Measuring annual increment lengths of both horns allowed determination of the age at which asymmetry began (Table 1). Growth of both horns was similar for years one to five. Growth of the left horn was progressively reduced starting in year six. For years seven to 12, total growth was 38 mm versus the population mean of 193 mm. Growth of the right horn was reduced during year five, presumably when infection began in the left horn. Growth of the right horn rebounded in year six and equalled or exceeded the population mean in most years thereafter (Table 1).

The right cornual process and sheath appeared normal. Based upon visual characteristics, the abnormal growth of the left horn appeared to be due to chronic epidermitis and osteomyelitis of the cornual process (Fig. 2). Caudal and lateral aspects of the cornual process and the flattened portion of the base contained numerous pits and crevices 1 to 8 mm in diameter and 1 to 3 mm deep. There was a large cavity (20 mm in diameter and 10 mm

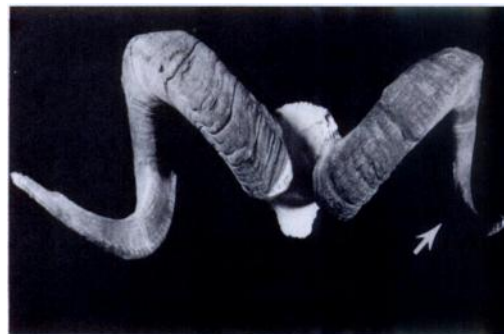

FIGURE 1. Asymmetric growth of left horn (arrow) in a Dall ram.

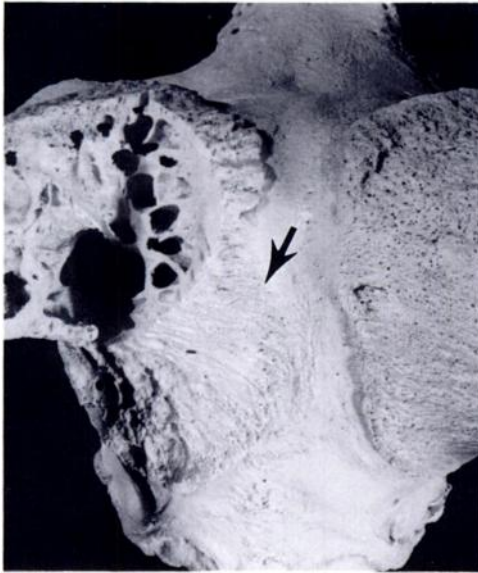


FIGURE 2. Chronic infection resulted in extensive bone loss at the base of the left cornual process (arrow).

deep) on the caudal lateral aspect of the projecting portion near the base posterior to the zygomatic arch (Fig. 3). The cavity extended into the medulla of the cornual sinus via small (<1 mm) openings that were surrounded by small bone spicules. The cortex of the cornual process was 6 to 9 mm thick. The caudal region of the horn sheath consisted of multiple layers of keratin (10 to 50 mm thick). The sheath in contact with the bone was diffusely roughened and pitted. Some areas of the sheath were dark red from localized hemorrhaging. The caudal base of the sheath was

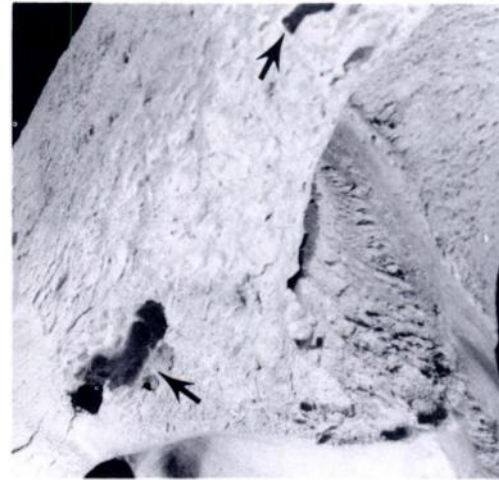


FIGURE 3. Pitting and cavitation of cornual process (arrows).

elongated and thickened (Fig. 4). These lesions are consistent with chronic epidermitis and osteomyelitis.

The lesions in this Dall sheep ram differed from those observed in chronic osteomyelitis of desert bighorn sheep (*Ovis canadensis* spp.) (Bunch, 1979). In desert bighorn, bacterial infection leads to a pyogenic osteomyelitis within the frontal and cornual sinuses. In the Dall sheep ram, the inflammation appeared to be contained mainly between the cornus and horn sheath. Bacteria may have entered at the base of the left horn and spread over the entire surface of the cornus. Trauma caused by butting other rams could have provided a route of entry.

TABLE 1. Annual horn growth measurements of the Sheep Mountain population of Dall rams (in mm).

	Annual growth (mm)													Total length
	1	2	3	4	5	6	7	8	9	10	11	12	13	
Population mean (n = 118)	25	143	180	135	106	79	59	45	35	24	18	12	4	865
Right horn of affected ram	61	238	191	174	104	121	86	55	35	23	20	14	5	1,127
Left horn of affected ram	54	239	193	177	112	46	13	8	7	5	3	2	2	861

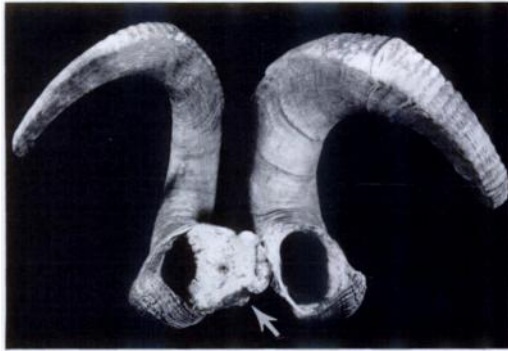

FIGURE 4. Loss of bone at the base of the left horn was followed by abnormal growth of the horn sheath (arrow).

Actinomyces pyogenes was isolated from exudates of Dall sheep rams with mandibular osteomyelitis (Glaze et al., 1982) and from desert bighorn sheep with chronic sinusitis (Bunch et al., 1978). *Actinomyces* spp. is common in North American wild sheep and may have been the organism that infected the left horn of this Dall ram.

LITERATURE CITED

- BUNCH, T. D. 1979. Skeletal lesions associated with desert bighorn chronic sinusitis. *Desert Bighorn Transactions* 23: 27-32.
- , S. R. PAUL, AND H. MCCUTCHEN. 1978. Chronic sinusitis in the desert bighorn (*Ovis canadensis nelsoni*). *Desert Bighorn Transactions* 22: 16-20.
- , M. HOEFS, R. L. GLAZE, AND H. S. ELLSWORTH. 1984. Further studies on horn aberrations in Dall's sheep (*Ovis dalli dalli*) from Yukon Territory, Canada. *Journal of Wildlife Diseases* 20: 125-133.
- GEIST, V. 1966. Validity of horn segment counts in aging bighorn sheep. *The Journal of Wildlife Management* 30: 634-646.
- GLAZE, R. L., M. HOEFS, AND T. D. BUNCH. 1982. Aberrations of the tooth arcade and mandible in Dall's sheep from Southwestern Yukon. *Journal of Wildlife Diseases* 18: 305-310.
- HOEFS, M., AND M. BAYER. 1983. Demographic characteristics of an unhunted Dall sheep (*Ovis dalli dalli*) population in southwest Yukon, Canada. *Canadian Journal of Zoology* 61: 1346-1357.
- , T. D. BUNCH, R. L. GLAZE, AND H. S. ELLSWORTH. 1982. Horn aberration in Dall's sheep (*Ovis dalli*) from Yukon Territory, Canada. *Journal of Wildlife Diseases* 18: 297-304.

Received for publication 9 March 1991.