



## **Chaunocephalosis in a Wild Population of Asian Open-billed Storks in Thailand**

Authors: Poonswad, Pilai, Chatikavanij, Pradon, and Thamavit, Witaya

Source: Journal of Wildlife Diseases, 28(3) : 460-466

Published By: Wildlife Disease Association

URL: <https://doi.org/10.7589/0090-3558-28.3.460>

---

BioOne Complete ([complete.BioOne.org](https://complete.BioOne.org)) is a full-text database of 200 subscribed and open-access titles in the biological, ecological, and environmental sciences published by nonprofit societies, associations, museums, institutions, and presses.

Your use of this PDF, the BioOne Complete website, and all posted and associated content indicates your acceptance of BioOne's Terms of Use, available at [www.bioone.org/terms-of-use](http://www.bioone.org/terms-of-use).

Usage of BioOne Complete content is strictly limited to personal, educational, and non - commercial use. Commercial inquiries or rights and permissions requests should be directed to the individual publisher as copyright holder.

---

BioOne sees sustainable scholarly publishing as an inherently collaborative enterprise connecting authors, nonprofit publishers, academic institutions, research libraries, and research funders in the common goal of maximizing access to critical research.

## Chaunocephalosis in a Wild Population of Asian Open-billed Storks in Thailand

Pilai Poonswad,<sup>1</sup> Pradon Chatikavanij,<sup>1</sup> and Witaya Thamavit,<sup>2</sup> <sup>1</sup> Department of Microbiology, Faculty of Science, Mahidol University, Rama 6 Road, Bangkok 10400, Thailand; <sup>2</sup> Department of Pathobiology, Faculty of Science, Mahidol University, Rama 6 Road, Bangkok 10400, Thailand

**ABSTRACT:** The most common trematode collected from Asian open-billed storks (*Anastomus oscitans*) was *Chaunocephalus ferox* (80% prevalence). The trematode was paired in granulomas in the intestinal wall. Based on histological examination of these capsules, there was degeneration and necrosis of muscle cells in the tunica muscularis. Granulation tissue with heterophil and lymphocyte infiltration appeared in the granulomas. Intestinal villi were shorter and wider in infected areas than in non-infected areas. Some intestinal glands were dilated. Storks with high intensity of *C. ferox* appeared ill. The death of storks infected with *C. ferox* may result from malnutrition due to the loss of absorptive function of the intestine and from the effect of granuloma formation which might interfere with the intestinal peristalsis.

**Key words:** Asian open-billed stork, *Anastomus oscitans*, *Chaunocephalus ferox*, echinostome, granuloma, pathology, small intestine, trematode.

*Chaunocephalus ferox* was first reported to parasitize Asian open-billed storks (*Anastomus oscitans*) by Rai (1963). The trematode is known to infect storks (Ciconiidae), herons (Ardeidae) and hawks (Accipitridae) (Dawes, 1956; Yanchev and Bozhkov, 1960; Feizullaev, 1962; Rai, 1963; Grunberg and Kutzer, 1964; Fabian et al., 1979). The pathology caused by *C. ferox* was first described as a nodular disease by Patnaik et al. (1970) who studied the trematodes recovered from captive Asian open-billed storks at Nandankanan zoo (India). In those birds, lesions were found in the post duodenal portion of the intestine. We describe the pathology of the disease in a wild population of Asian open-billed storks.

Seventy-one Asian open-billed storks were collected in the breeding colony of the Wat Phai Lom Bird Sanctuary, Sam Kok District, Pathum Thani Province (13°55' to 14°4'N, 100°25' to 100°32'E) in

central Thailand. Sixty-seven storks were captured with 12 m × 2.4 m mist nets with 61 mm mesh (McClure and Kwan-yuen, 1974). These included five adults and 62 hatch-year birds. In addition, four hatch-year birds that had drooping heads and were moving clumsily on the ground were caught by hand. The hatch-year birds were identified by their overall dark and gray plumage, brownish head and neck and short blunt bill without a gap between the mandibles. Adults were identified by their pale smoky gray plumage, black flight feathers and scapulars, and a gap between the mandibles (King and Dickinson, 1975).

The storks were killed (UFAW, 1967) and we removed their visceral organs, including heart, lung, liver, kidneys, spleen, and digestive tract. Total length of the small intestine as well as the distance from the gizzard to the area of infection were measured. Examination of the digestive tract for parasite infection was done by dissection, and of the other organs by pressing them between two heavy glass plates (size 230 × 50 × 5 mm) which were tightened with screws at both ends. The parasites recovered were counted and transferred to a petri dish containing 0.85% NaCl for further preparation, modified from Burrows (1965), including relaxation in tap water, fixation in alcohol-formalin-acetic acid (AFA) solution, staining in Semichon carmine, dehydration in a series of various concentrations of ethanol (35%, 50%, 70%, 80%, 90% and absolute), clearing in methylsalicylate and mounting in caedax (Canada balsam synthetic, Merck, Frankfurt, Federal Republic of Germany).

Infected portions of intestines were fixed in 10% buffered formalin. The selected specimens were passed through a series of

alcohol, xylene solution and embedded in paraffin. Sections of 5  $\mu\text{m}$  thickness were stained with hematoxylin and eosin, Mason's trichrome stain and Mallory's phosphotungstic acid hematoxylin method (PTAH) (Luna, 1976).

Specimens were deposited under accession number MUF0001 in the Museum of Malacology and Entomology, Faculty of Science, Mahidol University, Bangkok 10400, Thailand.

*Chaunocephalus ferox*, the most common parasite, was collected from 57 (80%) of 71 storks. The trematodes were found in granulomatous encapsulations embedded in the serosal layers of the small intestine. *Chaunocephalus ferox* was identified by its tadpole-like shape and characteristic arrangement of 27 head collar spines, including four corner spines grouped on each side. Two other trematodes were found in concurrence with *C. ferox* in the intestinal lumen. One which possessed 44 to 47 collar spines was identified as *Echinoparyphium recurvatum* and the other which had 25 collar spines was identified as *E. oscitansi*. *Echinoparyphium recurvatum* always was found in the lumen of the intestine and there was no evidence of attachment to the mucosa, whereas *E. oscitansi* were found associated with haemorrhagic spots on the mucosal surface. These two *Echinoparyphium* sp. never were found concurrently. The prevalence of these two latter species was 17% and 4%, respectively. All three species of trematodes are in the family Echinostomatidae.

The granulomas containing *C. ferox* were found in the small intestine between 27 and 78 cm posterior from the gizzard. The average distance between the gizzard and the proximal end of the infected area was 47.1 (SD = 9.5) cm and the average distance between the gizzard and the distal end was 61.9 (SD = 9.1) cm. The total length of the intestine ranged from 142 to 308 cm ( $\bar{x}$  = 209.9, SD = 30.0). The granulomas were globular in shape with sizes varying from 2.0 to 5.2 mm in diameter

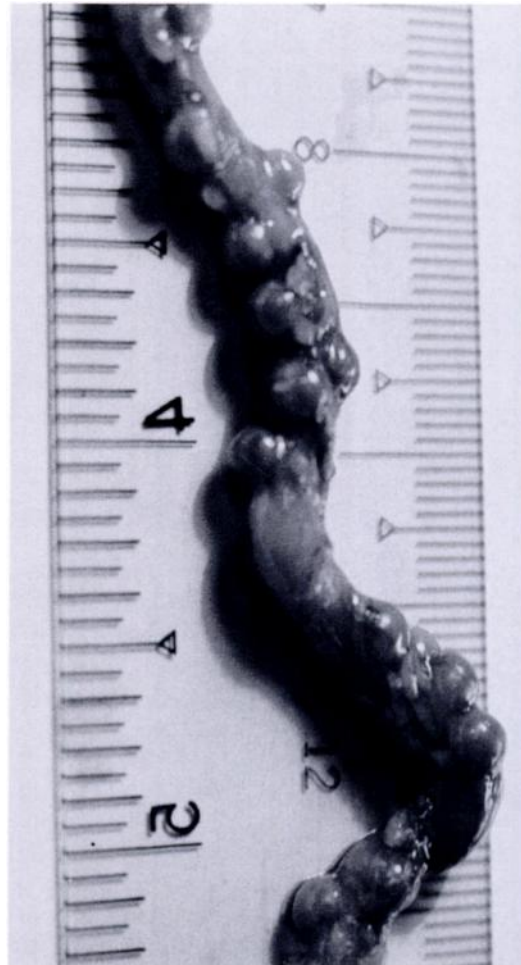

FIGURE 1. Granulomatous nodular lesions containing *Chaunocephalus ferox* on the small intestine of an Asian open-billed stork. Finer scale is in cm.

and a mean of 3.4 (SD = 0.68) mm (Fig. 1). The number of granulomatous lesions in infected storks varied from 1 to 86 with a mean of 14.7 (SD = 18.8). One to three worms were found embedded in each nodule lesion; most granulomas contained two. Intensity of trematodes per stork ranged from 2 to 180 with mean of 29.4 (SD = 37.9) and a median of 14. Every granuloma had a pore which opened into the intestinal lumen. The posterior portions of the worms protruded into the lumen and were just visible macroscopically. The size of the granulomatous nodules corresponded to the size of the encapsulated parasites.

TABLE 1. Infected Asian open-billed storks which had mixed infections of three species of echinostome trematodes with intensities of each species.

Stork number	Number of trematodes found		
	<i>Chaunocephalus ferox</i>	<i>Echino-paryphium recurvatum</i>	<i>E. oscitansi</i>
17	96	—	1
27	2	—	298
37	30	—	212
53	16	500	—
54*	122	220	—
55	88	132	—
56	79	100	—
60	67	22	—
63	74	218	—
64	12	500	—
65	53	565	—
66*	126	38	—
67	50	16	—
68*	180	300	—
69	57	7	—

\* Storks which were seen debilitated and were easily caught on the ground.

In 46 infected storks, the trematodes inside the lesion were mature with completely developed reproductive systems. Nineteen immature trematodes were found in 11 infected storks. They were recognized by their similar number and arrangement of collar spines to the mature trematodes but with a less developed reproductive system (small testes, small ovary and uterus with no eggs).

Mixed infections occurred between *C. ferox* and *E. recurvatum* in 12 storks and between *C. ferox* and *E. oscitansi* in three storks (Table 1). The four easily caught storks were heavily infected with *C. ferox*. One was infected with 124 individual *C. ferox* alone. The other three storks were infected with *C. ferox* in concurrence with *E. recurvatum*. The intensity of infection of these three storks was 122 *C. ferox* with 220 *E. recurvatum*, 126 *C. ferox* with 38 *E. recurvatum*, and 180 *C. ferox* with 300 *E. recurvatum*, respectively.

The soft bodies of *Pila* sp. snails including the foot, hepatopancreatic gland, mantle, reproductive system and other body parts were found in the esophagi and gizzards

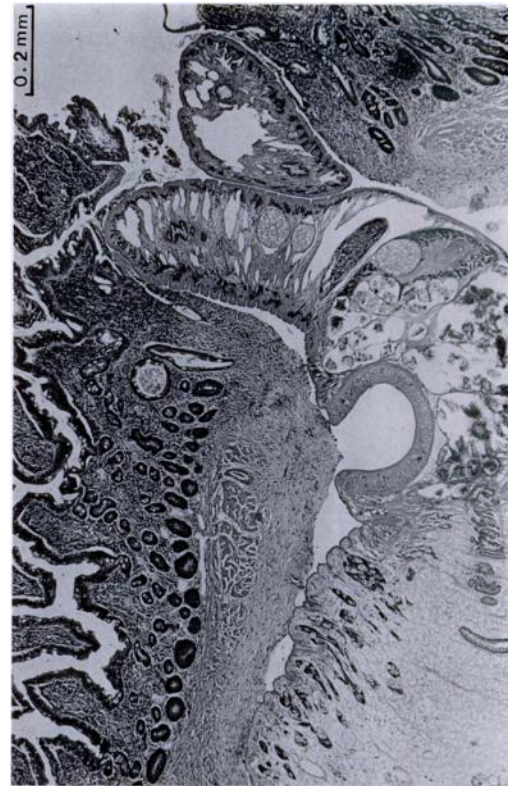


FIGURE 2. A *C. ferox*-containing granuloma with an opening into the intestinal lumen of an Asian open-billed stork. Cell infiltration in the lamina propria is denser in the area adjacent to the *Chaunocephalus ferox* than in other areas. Approximately half of the muscle in the tunica muscularis on the inner side where the parasite contacts the host tissue is fibrosed. H&E stain.

of 52 storks. They were identified based on observations of storks feeding on these snails, or by shells and soft bodies found below nests. The number of snails found eaten by storks varied from 1 to 35 ( $\bar{x} = 15.4$ ,  $SD = 8.7$ ). Five storks had empty gizzards. A few soft bodies of *Filoparudina* sp. snails (identified by the remaining operculum lids in the gizzard) were found together with *Pila* sp. in the gizzards of three storks.

Based on serial sections, the parasite-containing granulomatous nodules opened into the intestinal lumen (Fig. 2). The lamina propria adjacent to the nodule openings and to the parasites was infiltrated with plasma cells, lymphocytes, hetero-

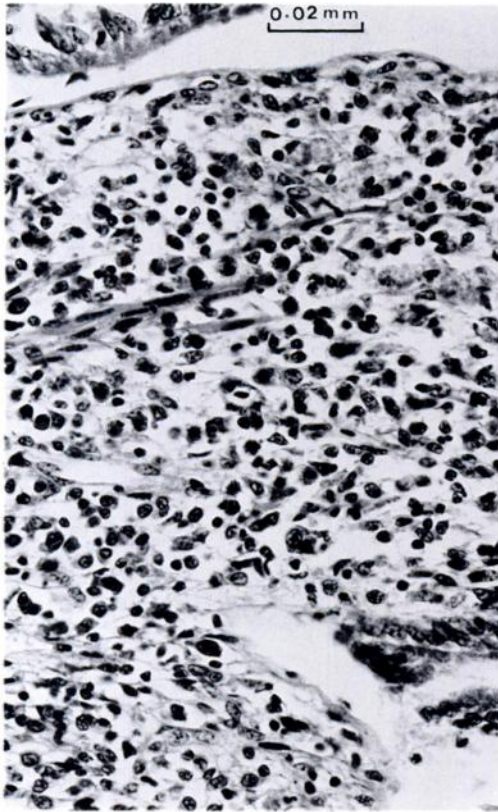


FIGURE 3. Infiltration of mononuclear cells in the lamina propria of the small intestine of an Asian open-billed stork adjacent to the *Chaunocephalus ferox*. H&E stain.

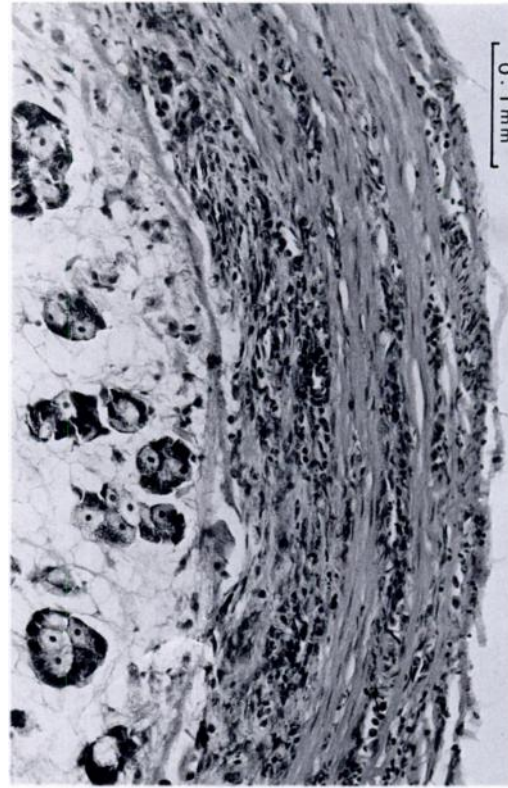


FIGURE 4. Infiltration of heterophils in the muscularis externa of an Asian open-billed stork. The muscles in the muscularis layer are degenerated and necrosed. The lesion is more severe at the inner layer in contact with *Chaunocephalus ferox*. H&E stain.

phils and some histiocytes (Fig. 2, 3). Smooth muscles in the tunica muscularis surrounding the parasites and forming the lesion wall in conjunction with the serosa became degenerative and necrotic with heterophil infiltration (Fig. 4). Granulation tissues with heterophil and lymphocyte infiltration (Fig. 5) and occasional giant cells and lymphoid follicles were present in the lesion (Fig. 6). The tissue around the nodule was hardened as the entire wall became fibrosed and fibrous tissues entirely replaced the smooth muscles of the muscular layer despite a few atrophic muscular fibers remaining in the walls of some lesions (Fig. 7). Intestinal villi adjacent to the pores of the lesion appeared shorter and wider than villi in uninfected areas. Some glands in the affected

areas were dilated and occasionally formed cyst-like structures (Fig. 8). Desquamation of the surface epithelium near the pores was frequently observed.

In contrast to the development of *C. ferox* within nodular lesions in the intestinal wall, most other members of the family Echinostomidae develop in the intestinal lumen. However, the pairing of *C. ferox* in granulomatous nodules is similar to that of *Paragonimus* sp. infecting the lungs (Schmidt and Roberts, 1981). The nodular granulomas and the pairing of *C. ferox* may involve either cross-fertilization or maturity acceleration as it does in some *Paragonimus* sp. (Miyazaki et al., 1981).

From our observations, we believe that the degree of pathogenicity of these echinostome infections varied with the num-

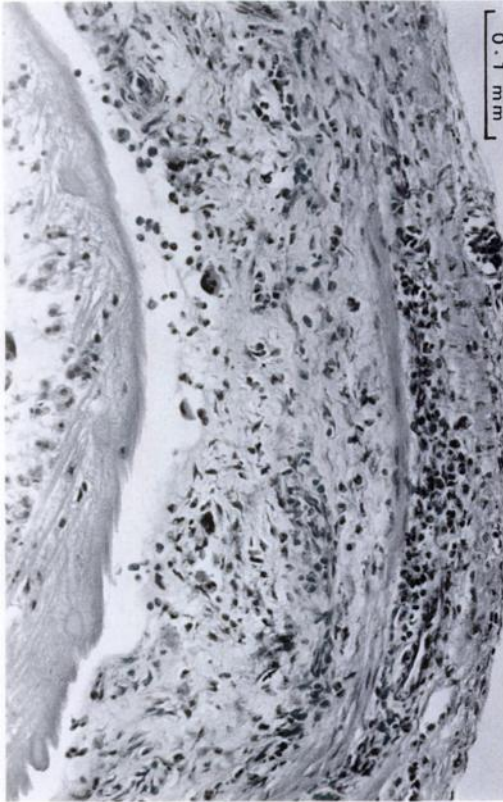

FIGURE 5. Granulation tissue with fibrosis replacing almost the entire layer of muscularis externa of the intestine of an Asian open-billed stork. The remaining outer muscular fibers are heavily infiltrated with heterophils, and a few giant cells in the granulation tissue can be seen. H&E stain.

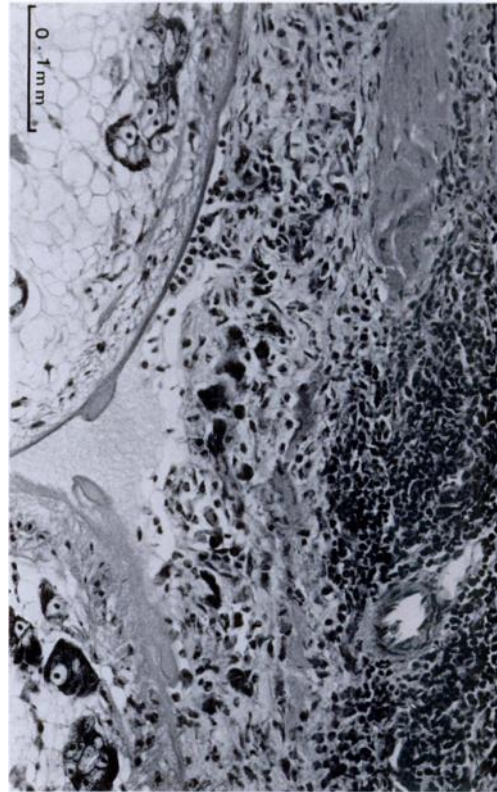


FIGURE 6. Fibrosis occurring over almost two-thirds of the inner muscularis externa of the intestine of an Asian open-billed stork. Infiltration of a few heterophils and giant cells and the presence of lymphoid follicles are also seen in the fibrosed layer. H&E stain.

ber of mature worms. The four storks which appeared debilitated were infected with the highest number of *C. ferox*, of the infected storks we examined. Mixed infections of *C. ferox* and *E. recurvatum* were found in three of the four storks. Based on the number of trematodes found in mixed infections (Table 1), it can be seen that despite very high intensity of *E. recurvatum* in some individuals it was only in cases of high intensity of *C. ferox* that debilitation occurred. Therefore, we believe that debilitation of these four storks was due to the extremely heavy infection with *C. ferox* rather than the concurrent infection of both parasites. *Echinoparyphium recurvatum* has been reported to in-

fect ducks, fowl, pigeons and man (Dawes, 1956; Yamashita, 1964), but no clinical signs have been described. Other researchers have stated that *C. ferox* caused deep ulcers and catarrhal enteritis and caused death in white storks (*Ciconia ciconia*), especially in young birds (Grunberg and Kutzer, 1964; Fabian et al., 1979). Patnaik et al. (1970) noted that seven of ten dead Asian open-billed storks at Nandankanan Zoo (India) were infected with *C. ferox*. They noted that storks infected with *C. ferox* had signs of diarrhea, listlessness, loss of appetite and convulsion before death. In addition, they also suggested that the larger adult parasites were more pathogenic.

From gross and histopathologic evi-

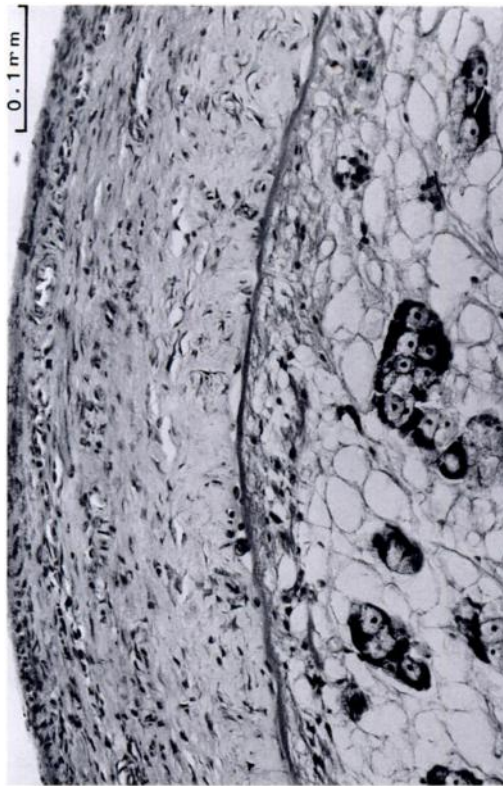


FIGURE 7. Fibrosis replacing the entire layer of muscularis externa of the intestine of an Asian open-billed stork despite scant infiltration of heterophils. H&E stain.

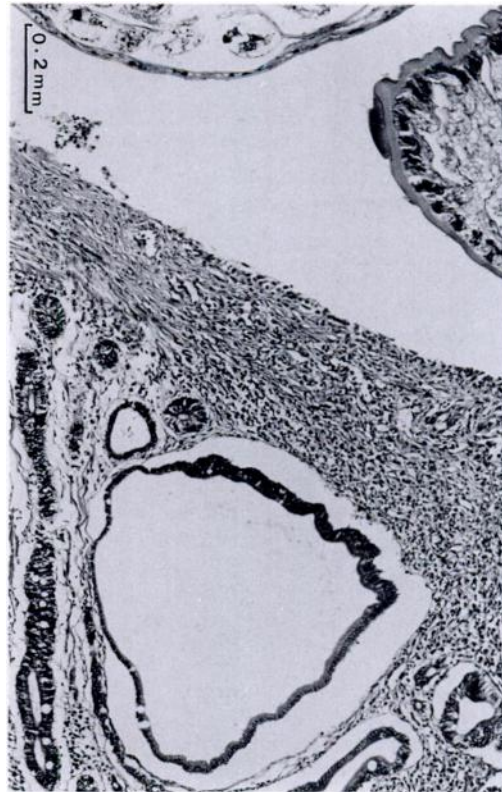

FIGURE 8. An intestinal gland in an Asian open-billed stork formed into a cyst-like lesion. H&E stain.

dence, we postulate that, following ingestion of metacercaria, the parasites buried themselves in the intestinal wall at the duodenal portion. A granuloma was formed which encapsulated the parasites, but with a small opening into the intestinal lumen. The inner portion of the granuloma was formed from the tunica muscularis of the small intestines in direct contact with the parasites. Initially, the tunica muscularis became necrotic and then was repaired by granulation tissue and subsequent scoring by fibrosis of the entire wall (Neafie and Connor, 1976). We believe that the mechanical damage caused by the presence of the large nodular lesions was partially responsible for the clinical signs observed in heavily infected birds. This probably resulted in malnutrition following an inability to absorb food. This pathogenicity

was similar to that caused by *C. similiferox* (Sharma, 1980). The presence of giant cells, lymphocytes, lymphoid follicles, plasma cells and monocytes indicated that there had been a long interaction between parasite and host with immunological involvement (Bhamarapavati et al., 1978). In addition, intestinal fibrosis also may have affected food absorption and peristalsis.

Asian open-billed storks are known to migrate from Thailand across Myanmar (formerly Burma) to Bramaputra and the Ganges delta in Bangladesh (McClure, 1974). The trematode must, therefore, be carried between these localities in the migratory corridor. With such a high prevalence of infection in storks, *Pila* sp. snails, the main food of this stork (Lauhachinda, 1969), should be examined for the presence of the infective stages of *C. ferox*.

We would like to thank the Royal Forest

Department of Thailand for permission to collect storks at Wat Phai Lom Bird Sanctuary. We are in debt to Paiboon Sithithaworn, Daoroong Kungwanpong, Malcolm Coulter and Phil Hurrell for their kind assistance in various matters. We highly appreciate Chariya Brockelman for her comments and suggestions on this manuscript. Our thanks are also extended to Charnchai Champrecha for his careful typing of this manuscript.

#### LITERATURE CITED

- BHAMARAPRAVATI, N., W. THAMAVIT, AND S. VAJRASATHIRA. 1978. Liver changes in hamster infected with a liver fluke of man, *Opisthorchis viverrini*. American Journal of Tropical Medicine and Hygiene 27: 789-794.
- BURROWS, R. B. 1965. Microscopic diagnosis of the parasites of man. Yale University Press, New Haven, Connecticut, 328 pp.
- DAWES, B. 1956. The Trematoda. Cambridge University Press, London, England, 644 pp.
- FABIAN, L., G. BOROES, AND M. JANISCH. 1979. Death of white stork (*Ciconia ciconia*) in Budapest Zoo due to fluke infections. In *Erkrankungen der Zootiere*, R. Ippen and H. D. Schroder (eds.). Akademie Verlag, Berlin, German Democratic Republic, pp. 253-255.
- FEIZULLAEV, N. A. 1962. The divergence in two species of trematodes, *Cathaemasia hians* (Rudolphi, 1819) and *Chaunocephalus ferox* (Rudolphi, 1795) Dietz, 1909 on change of the intermediate host. Dokladi Akademii Nauk SSSR, 146: 238-241.
- GRUNBERG, W., AND E. KUTZER. 1964. Die pathologie verschiedener trematodeninfektionen bei storchen (*Ciconia ciconia* L., *C. nigra* L.). Zentralblatt für Veterinärmedizin Reihe B 11: 712-727.
- KING, B., AND E. C. DICKINSON. 1975. A field guide to the birds of south-east Asia. Collins, London, England, 480 pp.
- LAUHACHINDA, V. 1969. Preliminary study on the life history of open-billed stork *Anastomus oscitans* (Boddaert). M.Sc. Thesis. Department of Biology, Kasetsart University, Bangkok, Thailand, 51 pp.
- LUNA, L. G. 1976. Manual of histologic staining methods of the Armed Forces Institute of Pathology, 3rd ed. McGraw-Hill Book Company, New York, New York, 258 pp.
- MCCLURE, H. E. 1974. Migration and survival of the birds of Asia. Sahamitr Karn Pim, Din Daeng, Bangkok, Thailand, 476 pp.
- , AND P. KWANYUEN. 1974. The avifauna complex of an open-billed stork colony (*Anastomus oscitans*) in Thailand. The Natural History Bulletin of the Siam Society 25: 133-156.
- MIYAZAKI, I., S. HABA, AND K. TERASAKI. 1981. On the pairing of adult lung flukes. Medical Bulletin of Fukuoka University 8: 159-167.
- NEAFIE, R. C., AND D. H. CONNOR. 1976. Trichinosis. In *Pathology of tropical and extraordinary diseases*, C. H. Binford and D. H. Connor (eds.). Armed Forces Institute of Pathology, Washington, D.C., 696 pp.
- PATNAIK, M. M., A. T. RAO, L. N. ACHARJYO, AND D. N. MOHANTY. 1970. Notes on a nodular disease of the intestine of the open-billed stork—*Anastomus oscitans* caused by *Chaunocephalus ferox*. Journal of Wildlife Diseases 6: 64-66.
- RAI, S. L. 1963. Further observations on *Chaunocephalus ferox* (Rud., 1795) Dietz, 1909. (Trematoda: Echinostomatidae) Part I. Indian Journal of Helminthology 15: 6-13.
- SCHMIDT, G. D., AND L. S. ROBERTS. 1981. Foundation of parasitology. The C. V. Mosby Company, London, England, 795 pp.
- SHARMA, P. N. 1980. Host-parasite relations of *Chaunocephalus similifer*, Verma 1936 (Trematoda, Echinostomatidae) in the bird host *Anastomus oscitans*. Acta Parasitologica Polonica 27: 273-278.
- UFAW. 1967. Humane killing of animals. The University Federation for Animal Welfare, Herts, England, 38 pp. [Thai translation edition.]
- YANCHEV, Y., AND D. BOZHKOV. 1960. The biology of *Proalaria excavata* Rud. Dokladi Akademii Nauk SSSR 132: 726-728.
- YAMASHITA, J. 1964. Echinostome. In *Progress of medical parasitology in Japan*, Vol I, K. Morishita, Y. Komiya, and H. Matsubayashi (eds.). Meguro Parasitological Museum, Tokyo, Japan, 753 pp.

Received for publication 22 September 1989.