



Freemartinism in a Captive Herd of Rocky Mountain Bighorn Sheep (*Ovis canadensis*)

Authors: Kenny, David E., Cambre, Richard C., Frahm, Michelle W., and Bunch, Thomas D.

Source: Journal of Wildlife Diseases, 28(3) : 494-498

Published By: Wildlife Disease Association

URL: <https://doi.org/10.7589/0090-3558-28.3.494>

BioOne Complete (complete.BioOne.org) is a full-text database of 200 subscribed and open-access titles in the biological, ecological, and environmental sciences published by nonprofit societies, associations, museums, institutions, and presses.

Your use of this PDF, the BioOne Complete website, and all posted and associated content indicates your acceptance of BioOne's Terms of Use, available at www.bioone.org/terms-of-use.

Usage of BioOne Complete content is strictly limited to personal, educational, and non - commercial use. Commercial inquiries or rights and permissions requests should be directed to the individual publisher as copyright holder.

BioOne sees sustainable scholarly publishing as an inherently collaborative enterprise connecting authors, nonprofit publishers, academic institutions, research libraries, and research funders in the common goal of maximizing access to critical research.

Freemartinism in a Captive Herd of Rocky Mountain Bighorn Sheep (*Ovis canadensis*)

David E. Kenny,¹ Richard C. Cambre,¹ Michelle W. Frahm,² and Thomas D. Bunch,³ ¹ Denver Zoological Gardens, City Park, Denver, Colorado 80205, USA; ² Gladys Porter Zoo, Brownsville, Texas 78520, USA; ³ Utah State University, College of Agriculture, Department of Animal, Dairy and Veterinary Sciences, Logan, Utah 84322, USA

ABSTRACT: Freemartinism in two animals from a captive herd of Rocky Mountain bighorn sheep (*Ovis canadensis*) at the Denver Zoological Gardens (Denver, Colorado, USA) is described. A young ewe had female external genitalia, a masculine appearance, and demonstrated male behavior as she matured. Another ewe with female external genitalia died as a yearling. Necropsy revealed a non-patent vagina and internal male genitalia. Both females were chimeric with karyotypes containing XX and XY sex chromosomes.

Key words: Intersex, freemartin, chimera, Rocky Mountain bighorn sheep, *Ovis canadensis*, H-Y antigen, Müllerian ducts, Wolffian ducts.

Gender is determined at fertilization with the genetic and gonadal sex normally being the same (Winter and Pfeffer, 1977; Jubb et al., 1985; McFeely and Kessly, 1980). Masculinization of the fetus occurs early in gestation. Maleness is thought to be associated with an H-Y antigen which is theorized to be elaborated by genes on the Y sex chromosome (Jubb et al., 1985). The fetus initially has a set of undifferentiated gonads and both Wolffian and Müllerian ducts. The primitive gonadal tissue of the male, the Wolffian ducts (which become the epididymis, vas deferens, and seminal vesicles) develop under the influence of androgens. The female primordial tissues are not stimulated by androgens as in the male and regress. In the absence of H-Y antigen, the Müllerian ducts (which become the oviducts, uterus, and anterior vagina) and female genitalia develop (Jubb et al., 1985; Alifakiotis et al., 1976; McFeely et al., 1980). Any interruption in this process at the genetic or hormonal level could cause a sexual abnormality, the severity of which depends upon when it occurs during gestation (Jubb et al., 1985).

Intersex describes a broad category of genital disorders and abnormalities in which an animal has the genitalia and/or the secondary sex characteristics of both male and female (Winter and Pfeffer, 1977; Hafez, 1987). Freemartinism is a specific condition which can occur when there is heterosexual twinning. It happens when a genetic female's fetal circulation, through the chorioallantoic sac, is shared with a genetic male's (McFeely and Kessly, 1980; Arthur et al., 1982). The anastomosis may need to occur early in gestation and involve major vessels for blood cells from one twin to become established in the bone marrow of the other (Dain, 1971). The cellular exchange results in a mixed population of cells (male and female) in each twin making them a chimera and also may transfer the H-Y antigen of the male to the female (McFeely and Kessly, 1980). In the presence of the H-Y antigen, the female develops testicular tissue and produces androgens thus inhibiting development of Müllerian ducts and allowing for differentiation of the Wolffian ducts. Freemartin ewes tend to have a more masculine appearance than is characteristic of freemartinism in cattle (Wilkes et al., 1978). The male twin may be less fertile and the female twin is sterile (Jubb et al., 1985; Shanker and Bhatia, 1983; McFeely and Kessly, 1980).

Freemartinism is most frequently reported in domestic cattle and occasionally in other species including sheep (Wilkes et al., 1978; McFeely and Kessly, 1980). Wilkes et al. (1978) described a Dorset ewe in a set of triplets with female external genitalia, an enlarged clitoris, and a male internal reproductive tract that included inguinal testes, epididymes, vas deferentia,

and seminal vesicles. There was no uterus or cervix. This animal also appeared masculine and demonstrated male behavior. Alexander and Williams (1964) reported freemartinism in a set of Merino triplets detected when a caesarian section was performed at 146 days of gestation. The left horn contained a male and a female fetus. The female was closest to the cervix. A second male was in the right horn. There was an arterial umbilical anastomosis between fetuses in the left horn. The female fetus had female external genitalia with an enlarged clitoris, rudimentary cervix, no uterus, and subcutaneous inguinal testicles.

A Rocky Mountain bighorn lamb, purported to be a ewe, was obtained by the Denver Zoological Garden (DZG) (Denver Colorado 80205, USA) on 20 May 1985 from a Canadian Zoo. She had large horn buds and female external genitalia. As she matured, she grew as large as the herd ram (90 kg) and developed masculine type horns (Fig. 1). During the breeding season she behaved like a competing ram. The keeper noted horn displays, front kicking, lip curl (Flehmen) response, and sniffing the genitals of other ewes (Geist, 1971). She also followed and attempted to mount estrous ewes but deferred to the herd ram if he was interested in breeding. She occasionally engaged in head butting with the ram.

On 12 October 1987, the external genitalia of this animal were visually examined using manual restraint. The vulva was typical, except for an enlarged clitoris. Two oblong masses were present in the inguinal region. A percutaneous needle biopsy showed atrophic fibrotic testicular tissue on histopathologic examination. Heparinized blood samples were taken for karyotyping and serum was collected to evaluate testosterone levels utilizing radioimmunoassay. Samples were also submitted from the herd ram and another female who has produced three sets of twins. All samples were transported on wet ice. For the karyotype 5 to 10 metaphase spreads were




FIGURE 1. Captive male Rocky Mountain bighorn sheep. A. Freemartin demonstrating male conformation. B. Herd ram.

examined following the procedure described by Yunis (1976). The diploid chromosome number for the freemartin was 54 and her karyotype contained 2 X chromosomes (normal female bighorn sheep karyotype). The herd ram and the control female also had normal karyotypes. The radioimmunoassay for serum testosterone was run on the same animals following the procedure described by Berndston et al. (1974). The levels for the herd ram were 4.830 ng/ml, for the suspected freemartin they were 3.820 ng/ml, and for the normal female they were 0.057 ng/ml. The high testosterone level of the affected ewe suggested the presence of testicular tissue.

A second case involved a female bighorn who was twin to a male born on 3 May 1989. This was the second of three sets of twins born to this ewe. The 1-day-old lamb was examined and had an enlarged vagina and clitoris which were showing signs of desiccation. This was treated with a topical steroidal ointment. After the examination the mother rejected the lamb, necessitating bottle-raising. At 5 mo of age she still had an enlarged vagina and clitoris and her horns were developing male form. At 10 mo of age she was immobilized for physical examination with a mixture of 175 mg ketamine hydrochloride (Aveco

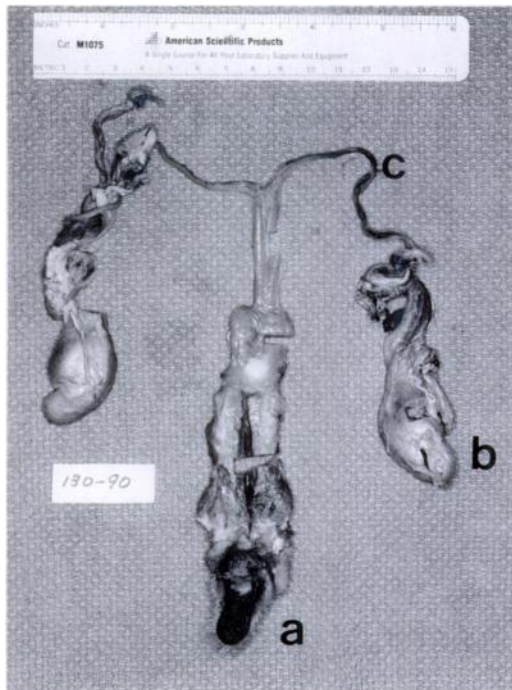


FIGURE 2. Freemartin bighorn sheep reproductive tract. a, external female genitalia; b, immature testicle, and c, vas deferens.

Co. Inc., Fort Dodge, Iowa 50501, USA) and 8.75 mg xylazine hydrochloride (Moby Corporation, Animal Health Division, Shawnee, Kansas 66201, USA) administered intravenously. A sterile feeding catheter could only be advanced a few centimeters into the vulva. The vulva and clitoris were surgically debulked at this time due to retention of urine between the enlarged vulvar lips which caused chronic urine scalding around the perineum. Two oblong masses were palpated in the inguinal region. A percutaneous needle biopsy from one of the masses contained reactive lymphocytes. A whole blood sample was collected in sodium heparin and transported on wet ice from this animal, her male twin, and a repeat sample from the freemartin in the first case for karyotyping. Karyotyping was performed by examining ten metaphase spreads following the procedure of Bunch et al. (1976). Chromosome analysis indicated the three bighorns were chimeras, having both male and female

cells. They were karyotyped as 8 54XX, 2 54XY; 5 54XX, 5 54XY; and 2 54XX, 8 54XY, respectively.

The female twin died suddenly without premonitory signs of illness at 14 mo of age. Death was thought to be due to a ruminal ulcer which led to bacterial colonization and finally a fulminant bacterial hepatitis. Necropsy also confirmed that the vulva was non-patent and the clitoris markedly enlarged. The urethral orifice was located just ventral to the vulva. The inguinal masses noted on earlier physical examination were immature testicles. The percutaneous biopsy performed at that time probably missed the testicular tissue. From the testicles the vasa deferentia passed through the inguinal rings into the abdominal cavity where they united and formed seminal vesicles at the level of the bladder. There was no evidence of an internal female reproductive tract (Fig. 2). The male twin was euthanized 3 mo later for a chronic debilitating respiratory problem and at necropsy had a normal male reproductive tract.

The current DZG bighorn sheep herd has been intact since December 1985. The same ram has been breeding the same 3 ewes over this time period. The lineages of the herd ram, first freemartin, and one of the breeding ewes trace back to Canada. The origin of one of the other two breeding ewes is from the Colorado Rocky Mountains while the second is a descendant of ancestors from the Colorado Rockies and Canada. Offspring from each year are sent to other institutions before the next breeding season and are not bred back to their sire.

Twinning is more common in domestic sheep than in cattle; however, freemartins are much more common in cattle. North American wild sheep rarely twin, unlike Asiatic wild sheep (Geist, 1971; Schaller, 1977). In domestic cattle, approximately 92% of heterosexual twin females are freemartins (Marcum, 1974). The difference in freemartin rates between sheep and cattle has been attributed to the lower fre-

quency of major vessel interplacental anastomosis in sheep during twinning (Jubb et al., 1985; McFeely and Kessly, 1980). In a study with domestic sheep involving 161 heterosexual twins, there were 0.23 freemartins per 100 ewes that lambed (Dain, 1971). The freemartins occurred in very inbred lines.

The zoo in Canada where the freemartin from the first case was born had not recorded that she had been born with a twin brother. She had the phenotypic characteristics of a freemartin, and her second karyotyping showed she was a chimera. She had external female genitalia, testicular tissue and a high testosterone level. The first karyotype was conducted at a human hospital cytogenetics laboratory and personnel may not have detected chimerism because they were unfamiliar with the species or did not examine sufficient cells.

The phenotypic and karyotypic abnormalities of the second freemartin were identical to those of the first. She had female external genitalia and male internal genitalia. There was no evidence, grossly or histologically, of an internal female reproductive tract. The karyotype of the twins in the second case showed that they were also chimeric.

There are reproductive differences between Old and New World wild sheep. The Asiatic wild sheep and domestic sheep have a 145 to 155 day gestation while gestation in North American wild sheep is 170 to 180 days. Asiatic and European wild sheep were the ancestors of domestic sheep. Asiatic wild sheep commonly twin and occasionally have triplets while North American wild sheep have single, large lambs (Geist, 1971; Schaller, 1977). Intersexuality is rare in domestic sheep and presumably the situation is the same with wild sheep. Hermaphroditism was reported in a lamb from a cross between a ewe and a ram that were Agrali-mouflon X Mexican desert bighorn crosses. This lamb had female external genitalia with an enlarged clitoris and an exploratory celiotomy revealed tes-

ticular and ovarian tissue (Bunch et al., 1991). Freemartinism would be a disadvantage for species survival in species and breeds of wild and domestic sheep that commonly twinned or bore litters. The incidence of freemartinism in Asiatic wild sheep is unknown but might be similar to that in domestic sheep (0.23 freemartins/100 heterosexual births). The incidence of freemartinism in North American wild sheep is also unknown but is probably a rare event because the ewes rarely twin. Freemartinism is not known to be a major reproductive problem in domestic or wild sheep.

ACKNOWLEDGMENTS

We thank Penny Smith, zookeeper, Denver Zoological Gardens, Denver, Colorado for excellent observations; The Children's Hospital Cytogenetics Laboratory, Denver, Colorado for karyotyping; Colorado State University, Roth Gerber Endocrine Laboratory, Fort Collins, Colorado for testosterone levels; Utah State University, College of Agriculture, Department of Animal, Dairy, and Veterinary Sciences, Logan, Utah for karyotyping; Robert Taylor, Alameda East Veterinary Hospital, Denver, Colorado for surgical assistance; Terry Spraker, Colorado State University, College of Veterinary Medicine, Fort Collins, Colorado for histopathology; Edward Gentz, a former Denver Zoo preceptee and now with Willow Creek Veterinary Clinic, Salt Lake City, Utah for help in researching the case reports.

LITERATURE CITED

- ALEXANDER, G., AND D. WILLIAMS. 1964. Ovine freemartins. *Nature* 201: 1296-1298.
- ALIFAKAIOTIS, T. A., J. W. CALL, AND W. C. FOOTE. 1976. Androgen induction of intersexuality in sheep. *Theriogenology* 6: 21-24.
- ARTHUR, G. H., D. E. NAOHES, AND H. PEARSON. 1982. Infertility in the cow. In *Veterinary reproduction and obstetrics*, 5th ed. Bailliere Tindall, London, pp. 295-327.
- BERNDSTON, W. E., PICKETT, B. W., AND T. M. NETT. 1974. Reproductive physiology of the stallion: Seasonal changes in the testosterone concentration of peripheral plasma. *Journal of Reproductive Fertility* 39: 115-118.
- BUNCH, T. D., W. C. FOOTE, AND J. J. SPILLET. 1976. Translocations of uerocentric chromosomes and their implications in the evolution of sheep (*Ovis*). *Cytogenetic Cell Genetics* 17: 122-136.

- , R. J. CALLAN, A. MACIULIS, J. C. DALTON, M. R. FIGUEROA, R. KUNZLER, AND R. E. OLSON. 1991. True hermaphroditism in a wild sheep: A clinical report. *Theriogenology* 36: 185–190.
- DAIN, A. 1971. The incidence of freemartinism in sheep. *Journal of Reproductive Fertility* 24: 91–97.
- GEIST, V. 1971. A study in behavior and evolution. *In Mountain sheep*. University of Chicago Press, Chicago, Illinois, pp. 130–146.
- HAFEZ, E. S. E. 1987. Intersexuality. *In Reproduction in farm animals*, 5th ed. Lea & Febiger, Philadelphia, Pennsylvania, pp. 448–450.
- JUBB, K. V. F., P. C. KENNEDY, AND N. PALMER. 1985. The female genital system. *In Pathology of domestic animals*, 3rd ed. Academic Press, San Diego, California, pp. 305–307.
- MARCUM, J. B. 1974. The freemartin syndrome. *Animal Breeding Abstracts* 42: 227–238.
- MCFEELY, R. A., AND L. R. KESSLY. 1980. Intersexuality. *In Reproduction in farm animals*, 4th ed. Lea & Febiger, Philadelphia, Pennsylvania, pp. 494–502.
- SCHALLER, G. B. 1977. Mountain Monarchs-Wild sheep and Goats of the Himalaya. University of Chicago Press, Chicago, Illinois, 425 pp.
- SHANKER, V., AND S. BHATIA. 1983. Sex chromatin study of a bull and its freemartin cotwin. *The Veterinary Record* 113: 17–18.
- WILKES, P. R., I. B. MUNNO, AND W. V. S. WIJERATNE. 1978. Studies on sheep freemartin. *The Veterinary Record* 102: 140–142.
- WINTER, H., AND A. PFEFFER. 1977. Pathogenic classification and intersex. *The Veterinary Record* 100: 307–310.
- YUNIS, J. J. 1976. High resolution of human chromatin. *Science* 191: 1268–1279.

Received for publication 21 May 1991.