

HISTOMORPHOMETRIC STUDIES OF DERMAL BONE IN THE DESERT TORTOISE, GOPHERUS AGASSIZII

Authors: Wronski, T. J., Yen, C-F., and Jacobson, E. R.

Source: Journal of Wildlife Diseases, 28(4) : 603-609

Published By: Wildlife Disease Association

URL: <https://doi.org/10.7589/0090-3558-28.4.603>

BioOne Complete (complete.BioOne.org) is a full-text database of 200 subscribed and open-access titles in the biological, ecological, and environmental sciences published by nonprofit societies, associations, museums, institutions, and presses.

Your use of this PDF, the BioOne Complete website, and all posted and associated content indicates your acceptance of BioOne's Terms of Use, available at www.bioone.org/terms-of-use.

Usage of BioOne Complete content is strictly limited to personal, educational, and non - commercial use. Commercial inquiries or rights and permissions requests should be directed to the individual publisher as copyright holder.

BioOne sees sustainable scholarly publishing as an inherently collaborative enterprise connecting authors, nonprofit publishers, academic institutions, research libraries, and research funders in the common goal of maximizing access to critical research.

HISTOMORPHOMETRIC STUDIES OF DERMAL BONE IN THE DESERT TORTOISE, *GOPHERUS AGASSIZII*

T. J. Wronski,¹ C-F. Yen,¹ and E. R. Jacobson²

¹ Department of Physiological Sciences, College of Veterinary Medicine, Box 100144,
JHMHC, University of Florida, Gainesville, Florida 32610

² Department of Small Animal Clinical Sciences, College of Veterinary Medicine, Box 100006,
JHMHC, University of Florida, Gainesville, Florida 32610

ABSTRACT: Dermal bone biopsies were collected from the periphery of the carapaces of adult desert tortoises (*Gopherus agassizii*) from grazed and ungrazed habitats near the Arizona/Utah border (USA). Quantitative bone histomorphometry was performed on these biopsies as well as on dermal bone biopsies collected from captive juvenile desert tortoises. Except for mild osteomalacia, carapaces of adult desert tortoises from the grazed habitat were relatively normal. No signs of osteopenia were observed. Based on the low numbers of osteoblasts and osteoclasts in dermal bone of both populations of adult desert tortoises, it appears that the peripheral carapace is relatively inert with very low levels of dermal bone turnover. Bone cells and osteoid were more common in dermal bone biopsies from the carapace and plastron of captive juvenile desert tortoises than in adult desert tortoises. However, the great variability in the incidence of bone cells among individuals and the difficulty in collecting juvenile desert tortoises in the field limit the usefulness of dermal bone biopsies from animals of this age group. Based on these results, we propose that dermal bone of the peripheral carapace is a poor sample site for evaluating the effects of dietary or environmental conditions on calcified tissues in desert tortoises.

Key words: Desert tortoise, *Gopherus agassizii*, carapace, dermal bone biopsy, bone histomorphometry, osteomalacia.

INTRODUCTION

The anatomic and histologic characteristics of the aquatic turtle shell have been well described (Suzuki, 1963; Zangerl, 1969). It consists of a dorsal arched carapace and a ventral flat plastron connected laterally by the bridge. These components of the shell are covered by epidermal horny scutes under which are dermal bone plates separated by sutures. The dermal plates are composed of inner and outer layers of compact bone with an intervening middle region of trabecular or spongy bone. The carapace of aquatic turtles does not become osteopenic during egg production (Suzuki, 1963).

Dermal bone of the desert tortoise *Gopherus agassizii* has not been characterized histologically to date. In this report, we present the first histomorphometric characterization of dermal bone in the desert tortoise *Gopherus agassizii*. There is evidence that the tortoise carapace may become osteopenic in populations from habitats devoid of perennial grasses due to livestock overgrazing (Jarchow and May,

1989). To test this hypothesis, we compared carapaces from a population of adult desert tortoises from a grazed habitat to those from a population inhabiting an area with minimal livestock grazing. We also compared dermal bones from adult-free living desert tortoises to those of captive juvenile desert tortoises.

MATERIALS AND METHODS

Members of the Arizona Game and Fish Department performed field studies in September, 1989 on two distinct populations of adult desert tortoises. The first population was located in a study area of 2.6 km² at Beaver Dam Slope (37°4'N, 113°55'W) near the Arizona and Utah (USA) border. The vegetation types that composed the major portion of the diet of desert tortoises within this study area were annual plants such as foxtail brome (*Bromus rubens*), redstem filaree (*Erodium cicutarium*), and Mediterranean grass (*Schismus barbatus*) (Hansen et al., 1976). Beaver Dam Slope was open to livestock grazing, which depleted the vegetation available to desert tortoises.

The second population of desert tortoises was located in a study area of 2.6 km² at City Creek, Utah (37°10'N, 113°35'W). Foxtail brome and

redstem filaree were the major vegetation types ingested by desert tortoises within this study area. The rugged terrain, drought conditions, and lack of a permanent water source at the City Creek study area limited livestock grazing since 1988 to a few cattle passing through the area. Before this time, the City Creek area was occasionally used as winter range only with livestock leaving the area by late May. Despite some minimal grazing, the City Creek study area was essentially ungrazed, compared to the heavy livestock grazing allowed at the Beaver Dam Slope study area.

Most (>80%) animals collected from each desert tortoise population were males. Each animal was weighed and anesthetized with an intramuscular injection of ketamine hydrochloride (Fort Dodge Laboratories, Fort Dodge, Iowa, USA) at a dose of 25 mg/kg body weight. The biopsy site between the second and third marginal scutes of the carapace was surgically scrubbed with a 0.5% organic iodine solution (Medadine, Tech America, Kansas City, Missouri, USA). A cylindrical sample of dermal bone 6 mm in diameter was removed aseptically with a manually-operated Galt skull trephine (J and J Codman, Randolph, Massachusetts, USA). The resulting carapace defect was initially packed with sterile gauze, then sealed with a methacrylate resin (Cyanoveneer, Ellman International Manufacturing Inc., Hewlett, New York, USA). All tortoises were released at the site of their collection soon after recovery from anesthesia.

For comparison with adult desert tortoises, additional dermal bone biopsies were collected in the same manner from captive juvenile desert tortoises maintained at the Adobe Mountain Rehabilitation Center of the Arizona Fish and Game Department, Phoenix, Arizona. The sex of these animals could not be determined. The biopsy sites were between the second and third marginal scutes of the carapace as well as the gular scute of the plastron. Juvenile desert tortoises also had their carapace defect packed with sterile gauze and sealed with methacrylate resin.

All dermal bone biopsies were placed immediately in 10% phosphate-buffered formalin for tissue fixation. The bone samples were dehydrated in ethanol and embedded undecalcified in methyl methacrylate (Baron et al., 1983). Cross sections of 5 μ m thickness were cut with an AO Autocut/Jung 1150 microtome (Jung, Heidelberg, Germany) and stained according to the Von Kossa method (Baron et al., 1983) with a tetrachrome counterstain.

Quantitative histomorphometry was performed with the Bioquant Bone Morphometry System (R & M Biometrics Corp., Nashville, Tennessee, USA). Areas and lengths of interest were traced with a cursor on a Hipad digitizing

tablet (Houston Instruments, Austin, Texas, USA) adjacent to a Nikon Labophot microscope (Nikon Inc., Garden City, New York, USA). The light within the cursor can be visualized in the microscopic field when used in conjunction with a camera lucida. Raw data were stored in an Apple IIe microcomputer interfaced to the digitizing tablet. Values for dermal bone histomorphometric parameters were then calculated with Bioquant software.

Six measurements were determined in each dermal bone biopsy. Dermal bone thickness (mm) is the mean distance between the periosteal surface of the outer dermal plate to the periosteal surface of the inner dermal plate, measured at three equally-spaced sites in each carapace and plastron biopsy. Dermal bone porosity (%) is the area of soft, noncalcified tissue within the dermal plates, expressed as a percent of total (calcified + noncalcified) tissue area. This measurement was performed in the area within 1 mm of the periosteal surface along both the inner and outer dermal plates of the carapaces and plastrons. Osteoclast surface (%) is the length of bone surface with adjacent osteoclasts (bone resorbing cells), expressed as a percent of total bone surface length. This measurement was indicative of bone resorption and was performed in the trabecular compartment between the inner and outer dermal plates of the carapaces and plastrons. Osteoblast surface (%) is the length of bone surface with adjacent osteoblasts (the bone forming cells), expressed as a percent of total bone surface length in the trabecular compartment of the carapaces and plastrons. This parameter is an index of bone formation. Osteoid surface (%) is the length of bone surface lined with osteoid (unmineralized bone matrix), expressed as a percent of total bone surface length in the trabecular compartment of the carapaces and plastrons. Osteoid seam width (μ m) is the mean width of an osteoid seam measured at three to five equally-spaced sites along the length of an individual osteoid seam. These measurements were performed in 10 osteoid seams within each biopsy on dermal bone of the carapace and plastron.

All values are expressed as the mean and standard deviation (SD). A Kruskal-Wallis test (Conover, 1980) was used to evaluate differences in body weight and dermal bone parameters between the Beaver Dam Slope and City Creek populations of adult desert tortoises, and between adult desert tortoises of the City Creek population and captive juvenile desert tortoises. Statistical differences between the carapaces and plastrons of juvenile desert tortoises were evaluated with the paired *t*-test (Sokal and Rohlf, 1981). A value of $P < 0.05$ was considered to be significant.

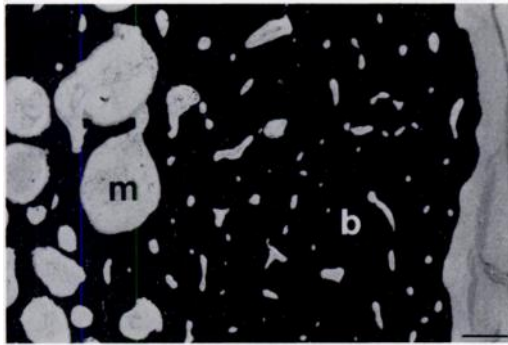


FIGURE 1. Dermal bone biopsy from carapace of an adult desert tortoise. Note the darkly-stained bone (b) and the lightly-stained marrow tissue (m). The dermal plate to the right of the figure is relatively dense with few marrow or vascular spaces. Marrow spaces are more extensive in the trabecular compartment to the left. Von Kossa/tetrachrome. Bar = 400 μ m.

RESULTS

The mean (SD) body weight of 16 adult desert tortoises from the Beaver Dam Slope population (grazed habitat) was 2,751 (599) g. This group consisted of 13 males and 3 females with mean body weights of 2,920 (519) g and 2,020 (301) g, respectively. This difference in body weight between sexes was significant ($P < 0.02$).

The mean (SD) body weight of 17 adult desert tortoises from the City Creek population (ungrazed habitat) was 3,166 (827) g. This group consisted of 13 males and 4 females with mean body weights of 3,304 (888) g and 2,719 (373) g, respectively. This difference in body weight between sexes was not statistically significant.

When comparing adult desert tortoises from the two populations, their mean body weights (both sexes combined) were not significantly different. Although the male desert tortoises weighed more than the females within each population, significant differences in bone histomorphometric parameters between sexes were not observed. Therefore, histomorphometric data from both sexes were combined within each population of adult desert tortoises.

Dermal bone of the typical carapace of an adult desert tortoise consisted of dense inner and outer dermal plates separated

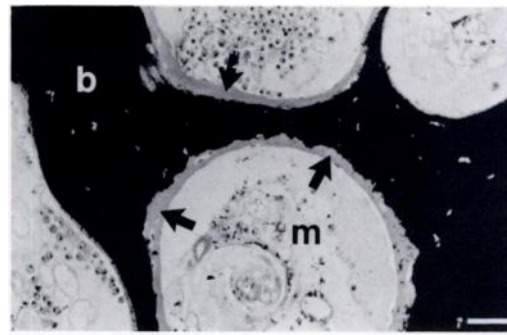


FIGURE 2. The trabecular compartment of the carapace of an adult desert tortoise composed of bone (b), marrow (m), and unmineralized bone matrix, or osteoid (arrows). Von Kossa/tetrachrome. Bar = 100 μ m.

by a trabecular compartment composed of calcified bone spicules with areas of soft, marrow-like tissue (Fig. 1). Osteoid lined the surfaces of some bone spicules of the trabecular compartment (Fig. 2). The marrow-like tissue was composed of connective tissue, some fat cells, and isolated pockets of hematopoietic cells.

Dermal bone thickness and porosity were nearly identical in adult desert tortoises from the grazed and ungrazed habitats (Table 1). However, desert tortoises from the grazed Beaver Dam Slope habitat had a two-fold greater osteoid surface compared to desert tortoises from the ungrazed City Creek habitat. This difference in osteoid surface between the two populations was statistically significant ($P < 0.02$). In contrast, osteoid seam width was not significantly different between desert tortoises from the grazed and ungrazed habitats. Since bone cells were lacking in dermal bone from most adult desert tortoises, the percentages of osteoblast and osteoclast surfaces could not be reliably measured.

The body weights for 11 captive juvenile desert tortoises ranged from 110 g to 830 g with a mean (SD) of 350 (209) g. As observed in adult desert tortoises, the carapace and plastron of the juvenile animals each consisted of inner and outer dermal plates separated by a trabecular compartment composed of calcified bone spicules

TABLE 1. Dermal bone histomorphometric parameters in the carapaces of adult desert tortoises from grazed and ungrazed habitats near the Arizona and Utah border, September, 1989.

	<i>n</i>	Dermal bone thickness (mm)	Dermal bone porosity (%)	Osteoid surface (%)	Osteoid seam width (μ m)
Beaver Dam Slope (grazed habitat)	16	7.6 (1.4) ^a	4.4 (1.1)	22.0 (15.5) ^b	5.6 (2.3)
City Creek (ungrazed habitat)	17	7.6 (1.0)	3.6 (1.8)	10.6 (9.5)	4.9 (1.8)

^a All values are the mean (SD).

^b Significantly different from City Creek value ($P < 0.02$).

with areas of marrow-like soft tissue. The dermal plates were porous and poorly developed in the younger desert tortoises of low body weight (Fig. 3) but became more dense with size (Fig. 4). Nearly all bone surfaces within the trabecular compartment were lined by osteoid in juvenile desert tortoises (Fig. 5). Osteoblast (Fig. 5) and osteoclast (Fig. 6) surfaces were highly variable: the standard deviations exceeded the means for these parameters (Table 2). Such surfaces, indicative of bone resorption and formation, respectively, were totally absent in some animals but present in others. With the exception of dermal bone thickness, histomorphometric parameters in the carapace and plastron of juvenile desert tortoises were nearly identical (Table 2). The plastron was significantly thicker than the carapace in these animals ($P < 0.01$).

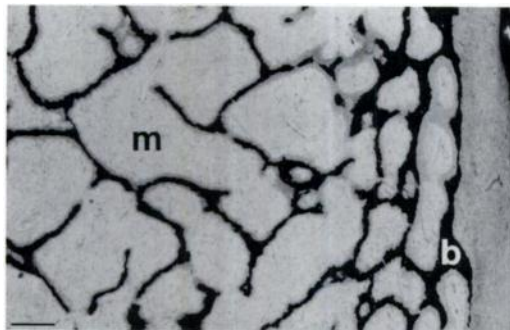


FIGURE 3. Dermal bone from the carapace of a 210 g juvenile desert tortoise. Note the darkly-stained bone (b) and the lightly-stained bone marrow (m). The carapace of this younger desert tortoise is porous with a poorly-developed dermal plate. Von Kossa/tetrachrome. Bar = 400 μ m.

Several differences in dermal bone of the carapace were evident between captive juvenile desert tortoises and adult desert tortoises of the City Creek population. Adults had thicker, denser carapaces with decreased osteoid surfaces and relatively thin osteoid seams. These differences were significant ($P < 0.01$). Although highly variable, osteoclasts and osteoblasts were more common in the juvenile desert tortoises. These bone cells usually were absent in adult desert tortoises. The observed differences between the carapaces of juvenile and adult desert tortoises probably are a consequence of the normal aging process.

DISCUSSION

The effect of livestock grazing on the vitality of desert tortoise populations is an important issue for wildlife management

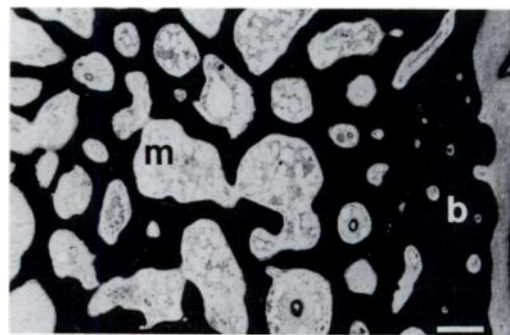


FIGURE 4. Dermal bone from the carapace of a 535 g juvenile desert tortoise with darkly-stained bone (b) and lightly-stained bone marrow (m). The carapace of this older desert tortoise has more bone with a relatively dense dermal plate compared to the carapace of the younger desert tortoise seen in Figure 3. Von Kossa/tetrachrome. Bar = 400 μ m.

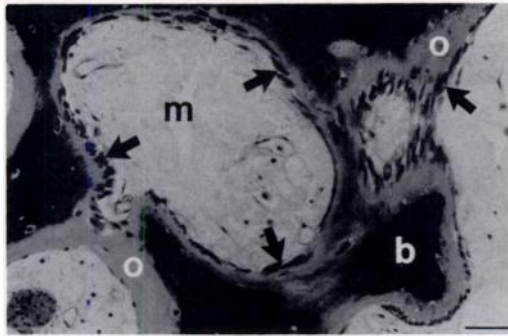


FIGURE 5. The trabecular compartment of a juvenile desert tortoise composed of bone (b), marrow (m), and unmineralized bone matrix, or osteoid (o). Note that all bone surfaces are lined by osteoid. Note also the darkly-stained osteoblasts (arrows) adjacent to the osteoid. Osteoblasts were relatively common in this particular animal, but were rare or absent in other juvenile desert tortoises of comparable ages. Von Kossa/tetrachrome. Bar = 100 μ m.

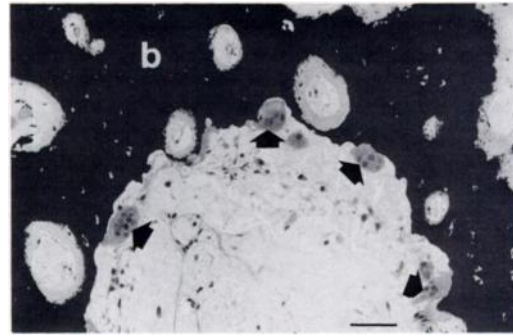


FIGURE 6. Osteoclasts (arrows) adjacent to darkly-stained bone (b) in the carapace of a juvenile desert tortoise. Osteoclasts were present in some juvenile desert tortoises, but were absent in others. Von Kossa/tetrachrome. Bar = 100 μ m.

of public lands. In the current study, dermal bone of the carapace of adult tortoises from a grazed habitat was not osteopenic (decreased bone mass). Dermal bone thickness and porosity were nearly identical in desert tortoises from grazed and ungrazed habitats. Greater osteoid surface in the animals from the grazed habitat may be evidence of mild osteomalacia. Osteoid increases as a consequence of dietary calcium deficiency or malnutrition (Keymer, 1978; Frye, 1981; Jackson and Cooper, 1981). However, the possible osteomalacia observed in dermal bone of desert tortoises from the grazed habitat was mild, with no accompanying increase in osteoid seam width.

Our quantitative finding of normal dermal bone mass in carapace biopsies from adult desert tortoises from a grazed habitat

is not consistent with a qualitative report of osteopenia in some carapaces of dead desert tortoises from the same grazed habitat at Beaver Dam Slope (Jarchow and May, 1989). A possible reason for this discrepancy is the unknown length of time for which the carapaces from the dead desert tortoises were exposed to the environment before their collection. Degradation of dermal bone with time may have resulted in the false impression of osteopenia in these weathered carapaces. Another possible explanation is that osteopenia may be more pronounced in the more medial areas of the carapace rather than in the laterally-placed marginal scutes from which the dermal bone biopsies were collected. Medial dermal bone biopsies were not collected because sampling from this site would have a high probability of invading the coelomic cavity.

Osteoblasts and osteoclasts were lacking in peripheral dermal bone of most adult

TABLE 2. Dermal bone histomorphometric parameters in the carapaces and plastrons of captive juvenile desert tortoises, September 1989.

	Dermal bone thickness (mm)	Dermal bone porosity (%)	Osteoclast surface (%)	Osteoblast surface (%)	Osteoid surface (%)	Osteoid seam width (μ m)
Carapace ($n = 11$)	3.0 (0.7) ^{a,b}	37.4 (20.4)	0.3 (0.5)	2.6 (5.5)	87.2 (23.0)	15.5 (7.6)
Plastron ($n = 11$)	4.5 (1.2)	32.2 (20.2)	0.5 (0.6)	2.8 (4.4)	87.1 (20.9)	14.8 (5.1)

^a All values are the mean (SD).

^b Significantly different from plastron value ($P < 0.01$).

desert tortoises. Since changes in bone mass are cell-mediated, we interpret the low number of bone cells present to mean that the peripheral carapace of adult desert tortoises has a low rate of bone turnover. Suzuki (1963) found dermal bone of aquatic turtles to also have a low turnover. However, Magliola (1984) inferred that metabolic activity in dermal bone of the plastron was similar to that of the long bones in adult box turtles (*Terrapene carolina triunguis*). The reasons for the conflicting results are unclear. However, we propose that peripheral dermal bone of the carapace is a poor sample site for detecting skeletal abnormalities induced by dietary, environmental, or hormonal changes in adult chelonians.

Dermal bone biopsies were similarly evaluated in captive juvenile desert tortoises. Although osteoblasts and osteoclasts were observed in dermal bone of some juvenile animals, high variability in the bone cell population among individuals would make it difficult to evaluate bone cellular changes as a consequence of malnutrition or other physiological disturbances. The plastron does not offer any significant advantages over the carapace; dermal bone histomorphometric parameters were nearly identical at the two sites. However, one may detect a delay in the development of more dense (i.e., less porous) dermal plates in malnourished, juvenile desert tortoises relative to well-nourished counterparts. A defect in calcification could result in dermal bone of greater porosity and wider osteoid seams. However, a comparative study between distinct juvenile desert tortoise populations would require careful standardization of age as well as biopsy site. In view of the difficulty in collecting juvenile desert tortoises in the field, such a study would be problematical.

The organization of dermal bone in the carapace of adult desert tortoises was found to be identical to that previously reported in aquatic turtles (Suzuki, 1963; Zangerl, 1969); both had inner and outer compact

dermal plates with a middle compartment of trabecular or spongy bone. The dermal plates were poorly developed and porous in juvenile desert tortoises of the lowest body weights but became more compact in the heavier animals. Nearly all osteoid surfaces in the rapidly growing, juvenile desert tortoises were devoid of adjacent osteoblasts, the cells which normally deposit the unmineralized bone matrix. This is in marked contrast to mammals in which nearly all osteoid surfaces are lined by osteoblasts (Jee, 1983; Wronski et al., 1991). Thus, dense connective tissue of dermal bone may be converted to osteoid and subsequently calcify without prior osteoblastic deposition. If so, this phenomenon would be unique to dermal bone of chelonians.

ACKNOWLEDGMENTS

The authors are grateful to members of the Arizona Game and Fish Department for collecting dermal bone biopsies from desert tortoises. We thank Mr. Cecil Schwalbe, Mr. James Wegge, Dr. James Jarchow, Mr. Todd Esque, and Ms. Vanessa Dickinson for helpful discussions. We are grateful to Ms. Patricia Prudencio for technical assistance and to Mrs. Mary Dixon for secretarial assistance. This research was supported by the Arizona Game and Fish Department.

LITERATURE CITED

- BARON, R., A. VIGNERY, L. NEFF, A. SILVERGATE, AND A. SANTA MARIA. 1983. Processing of undecalcified bone specimens for bone histomorphometry. In *Bone histomorphometry: Techniques and interpretation*, R. R. Recker (ed.), CRC Press, Boca Raton, Florida, pp. 13-35.
- CONOVER, W. J. 1980. Practical nonparametric statistics. John Wiley and Sons, New York, New York, pp. 229-237.
- FRYE, F. L. 1981. Biomedical and surgical aspects of captive reptile husbandry. Veterinary Medicine Publishing Co., Edwardsville, Kansas, 456 pp.
- HANSEN, R. M., M. K. JOHNSON, AND T. R. VAN DEVENDER. 1976. Foods of the desert tortoise, *Gopherus agassizii*, in Arizona and Utah. *Herpetologica* 32: 247-251.
- JACKSON, O. F., AND J. E. COOPER. 1981. Nutritional diseases. In *Diseases of the reptilia*, Vol. 2, J. E. Cooper and O. F. Jackson (eds.), Academic Press, New York, New York, pp. 409-428.

- JARCHOW, J. L., AND C. J. MAY. 1989. Investigation of desert tortoise mortality on the Beaver Dam Slope, Arizona and Utah. Report to the Arizona Game and Fish Department, Phoenix, Arizona, 22 pp.
- JEE, W. S. S. 1983. The skeletal tissues. In *Histology—Cell and tissue biology*, L. Weiss (ed.). Elsevier Science Publishing Co., New York, New York, pp. 200–255.
- KEYMER, I. F. 1978. Diseases of chelonians: (1) Necropsy survey of tortoises. *The Veterinary Record* 103: 548–552.
- MAGLIOLA, L. 1984. The effects of estrogen on skeletal calcium metabolism and on plasma parameters of vitellogenesis in the male, three-toed box turtle (*Terrapene carolina triunguis*). *General and Comparative Endocrinology* 54: 162–170.
- SOKAL, R. R., AND F. J. ROHLF. 1981. *Biometry*, 2nd ed. W. H. Freeman and Company, New York, New York, pp. 354–357.
- SUZUKI, H. K. 1963. Studies on the osseous system of the slider turtle. *Annals of the New York Academy of Sciences* 109: 351–410.
- WRONSKI, T. J., C-F. YEN, AND K. S. SCOTT. 1991. Estrogen and diphosphonate treatment provide long-term protection against osteopenia in ovariectomized rats. *Journal of Bone and Mineral Research* 6: 387–394.
- ZANGERL, R. 1969. The turtle shell. In *Biology of the reptilia*, C. Gans (ed.). Academic Press, New York, New York, pp. 311–339.

Received for publication 10 December 1991.