



Possible vaccine-induced Canine Distemper in a South American Bush Dog (*Speothos venaticus*)

Authors: McInnes, Elizabeth F., Burroughs, R. E. J., and Duncan, N. M.

Source: Journal of Wildlife Diseases, 28(4) : 614-617

Published By: Wildlife Disease Association

URL: <https://doi.org/10.7589/0090-3558-28.4.614>

BioOne Complete (complete.BioOne.org) is a full-text database of 200 subscribed and open-access titles in the biological, ecological, and environmental sciences published by nonprofit societies, associations, museums, institutions, and presses.

Your use of this PDF, the BioOne Complete website, and all posted and associated content indicates your acceptance of BioOne's Terms of Use, available at www.bioone.org/terms-of-use.

Usage of BioOne Complete content is strictly limited to personal, educational, and non - commercial use. Commercial inquiries or rights and permissions requests should be directed to the individual publisher as copyright holder.

BioOne sees sustainable scholarly publishing as an inherently collaborative enterprise connecting authors, nonprofit publishers, academic institutions, research libraries, and research funders in the common goal of maximizing access to critical research.

Possible vaccine-induced Canine Distemper in a South American Bush Dog (*Speothos venaticus*)

Elizabeth F. McInnes,¹ R. E. J. Burroughs,² and N. M. Duncan,¹ ¹ Department of Pathology, Faculty of Veterinary Science, Medical University of Southern Africa, 0204 Medunsa, Republic of South Africa; ² National Zoological Gardens, Pretoria, Republic of South Africa

ABSTRACT: Suspected vaccine-induced canine distemper was diagnosed in a captive female bush dog (*Speothos venaticus*). Macroscopic lesions included mild congestion of the gastric mucosa and focal consolidation of the lung. Histopathological lesions included status spongiosis, gliosis, widespread eosinophilic, intranuclear and intracytoplasmic inclusion bodies in neurons, astrocytes and gitter cells of the cerebral, cerebellar and spinal white matter.

Key words: Bush dog, *Speothos venaticus*, canine distemper, vaccine-induced disease, case report.

Although it is recommended (Montali et al., 1983) that susceptible wild canids in zoological collections be vaccinated against canine distemper, the use of modified-live vaccines is problematic because canine distemper vaccines have not been tested for efficacy and safety in most wild carnivores. Vaccine-induced canine distemper has been reported in wild and captive species including the lesser panda (*Ailurus fulgens*) (Bush et al., 1976), gray fox (*Urocyon cinereoargenteus*) (Halbrooks et al., 1981), the kinkajou (*Potos flavus*) (Kazacos et al., 1981) and the black-footed ferret (*Mustela nigripes*) (Carpenter et al., 1976). It has been reported also in the domestic dog (Hartley, 1974), in the Cape hunting dog (*Lycaon pictus*) (McCormick, 1983; Van Heerden et al., 1989), the maned wolf (*Chrysocyon brachyurus*) (Thomas-Baker, 1985) and possibly in the fennec fox (*Fennecus zerda*) (Montali et al., 1987). No cases of naturally occurring distemper have been reported in bush dogs (*Speothos venaticus*). Despite these vaccine-induced cases in other wild canids, modified-live, chicken embryo-derived, canine distemper vaccine is recommended (Sedgwick and Young, 1968; Montali et al., 1983). There are no reports of the use of modi-

fied-live canine cell origin vaccine in bush dogs. In this report, we document clinical findings and lesions of suspected canine distemper in a bush dog. The possibility that this case of canine distemper may have been vaccine-induced is considered.

A female juvenile, bush dog, from a litter of two, was born at the National Zoological Gardens (Pretoria, Republic of South Africa) (28°11'S, 25°44'E) on 26 October 1988. The second pup died 7 days before the death of the bush dog under consideration; however, no necropsy was performed on this animal since it was autolysed. The dam had been imported from the Berlin Zoological Gardens (Berlin, Federal Republic of Germany) and was vaccinated against canine distemper and parvovirus before arrival. The dam was vaccinated at 6 and 10 wk against parvovirus with a commercial inactivated vaccine called Candor P (Behringwerke AG, 3550 Marburg (Lahn), Federal Republic of Germany). The dam was vaccinated against canine distemper virus at 8 and 12 wk with an inactivated vaccine; the name of the vaccine no longer is available. The bush dog pup was kept in an enclosure and fed fruit, honey, and 1-day-old chicks. The enclosure was isolated from other wild canids. The possibility of exposure of the bush dog pup to a field strain canine distemper virus was considered impossible since the zoological gardens are completely surrounded by a security wall.

On 11 January 1989, the bush dog pup was vaccinated with a commercially available, modified-live canine vaccine (DA₂MP Vanguard Smith and Kline, Isando, Republic of South Africa) for parainfluenza viruses, adenovirus type 2, measles and canine distemper (Snyder-Hill strain). The

bush dog pup was not vaccinated against parvovirus. Twenty-one days later the bush dog pup showed anorexia and a mucopurulent ocular discharge. Twenty-four days after vaccination it developed nervous signs characterized by pacing within its enclosure and by not responding to humans. During the illness, the animal was force-fed and treated with an antibiotic eye ointment, Terracortril (Pfizer Laboratories SA Limited, Sandton, South Africa). Other drugs used were Lincospectin (Upjohn (Pty) Ltd, Isando, South Africa), a nutritional stimulant Nutrijel (Centaur Labs Limited, Johannesburg, South Africa) given by mouth, and vitamin B complex injectable (Vitamin B Co, Centaur Labs Limited, Johannesburg, South Africa). A corticosteroid, Fluvet (Coopers Animal Health Limited, Kempton Park, South Africa) was given three times over a period of 5 days; a tranquilizer, Valium (Roche Products Limited (Veterinary Division), Johannesburg, South Africa) was given twice; a tetracycline, Doxycycline (Milborrow Limited, Benrose, South Africa) and a sulfonamide Dimeton B (Centaur Labs Limited, Johannesburg, South Africa) were given daily over a 5-day period, until the death of the animal. The animal died 5 days after the onset of signs. It is unlikely that the corticosteroid could have contributed to the immunosuppression since it only was used to treat the bush dog pup after the onset of the canine distemper-like symptoms.

At necropsy, organs were examined grossly and specimens of intestine, cerebellum, cerebrum, spinal cord, liver, lung, kidney, bladder, spleen and heart were preserved in 10% neutral buffered formalin. These samples were embedded in paraffin, sectioned at 5 μm , and stained with hematoxylin and eosin for microscopic examination. A swab taken from the affected lung and embedded in Ames transport medium, and a portion of lung collected aseptically, were submitted for routine bacteriological examination (Department of Infectious Diseases and Public

Health, Medical University of Southern Africa, Medunsa, Republic of South Africa). A portion of the small intestine, scrapings of the intestine and a sample of the lung tissue were submitted on ice for electron microscopic examination by negative staining techniques to the Department of Infectious Diseases and Public Health (Medical University of Southern Africa, Medunsa, Republic of South Africa). The contents of the small intestine were subjected to four cycles of ultracentrifugation to produce a pellet of fecal content. The pellet was resuspended in a few droplets of water. A small droplet of 3% phosphotungstic acid (pH 6.5) and the virus suspension were mixed on wax surface and a carbon-coated formvar grid was floated onto this mixture for 10 sec. The grid was removed and the excess fluid was drained onto the edge of filter paper. The grids were examined in a Jeol 1200EX electron microscope (Jeol Ltd., Tokoyo, Japan). A smear of blood obtained from an ear vein was stained with RapiDiff (Clinical Sciences Diagnostics, Division of Central Medical Sciences Laboratories Limited, Booyens, Republic of South Africa) and examined under a light microscope. A fecal sample was collected for fecal flotation.

Yellow, purulent fluid and mucus were found in the trachea. There was widespread, multifocal congestion and consolidation of the lung tissue; a small amount of yellow purulent exudate exuded from the cut surface of the bronchioles. The gastric mucosa was mildly congested. Mild, focal meningeal congestion was noted. The fecal flotation was negative. *Klebsiella oxytoca* was isolated from the lung.

On electron microscopic examination, paramyxovirus-like nucleocapsids were observed in the scrapings of the small intestine (Fig. 1).

Multifocal areas of status spongiosis, demyelination and perivascular round cell infiltration composed mainly of lymphocytes were seen in white matter of the pons, cerebellum and spinal cord. Plasma

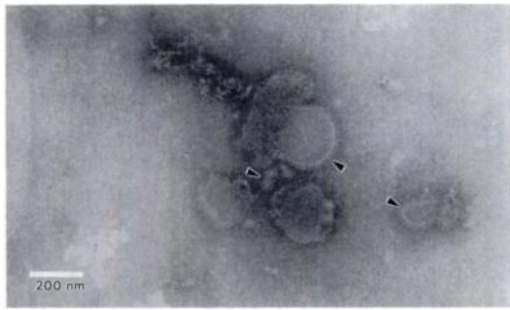


FIGURE 1. Negatively stained transmission electron micrograph of paramyxovirus-like nucleocapsids in the feces of the bush dog.

cells and lymphocyte perivascular cuffing was observed throughout the cerebrum as well as neuronal necrosis and gliosis. Deeply eosinophilic, intranuclear and intracytoplasmic inclusion bodies were present in neurons, astrocytes and gitter cells. Inclusion bodies were ovoid or round, distinct, homogenous. No inclusions were seen in the choroid plexus. Multiple inclusions were occasionally present in the neurons of the spinal cord. The meninges had a mild, diffuse lymphocyte and neutrophil infiltration.

The germinal centers of the spleen were depleted of lymphocytes and some of the lymphocytes were necrotic.

Severe congestion and hemorrhage into pulmonary alveoli were accompanied by mild edema. Focal areas of severe neutrophil infiltration into alveoli, bronchioles and the interstitium and fibrin were present. Colonies of plump bacilli and active alveolar macrophages were present within these areas. A few macrophages contained phagocytosed neutrophils and hemosiderin.

The liver was moderately congested. No significant lesions were observed in other tissues.

Canine distemper can be presumptively diagnosed by demonstrating intranuclear and intracytoplasmic inclusions in the brain and visceral tissue (Goss et al., 1948). Therefore, we concluded that this bush dog had distemper. The isolation of *Klebsiella*

oxytoca from the lungs is not surprising because secondary invaders are common in cases of canine distemper resulting from immunosuppression (Kazacos et al., 1981).

A strong possibility exists that the modified-live canine distemper vaccine attenuated in canine cell lines was responsible for the signs of clinical canine distemper and subsequent death in this bush dog. Since the virus was never isolated, the possibility of this having been a measles virus infection cannot be discounted. The bush dog involved was isolated from possible carrier animals in its enclosure, which was situated in an isolated area of the zoological gardens. The modified-live canine cell origin vaccine (Snyder-Hill strain) contains a neurotropic virus strain (Greene, 1984), which replicates rapidly in canine cells. Therefore, it produces widespread infection before an immune response can be mounted by the animal (Confer et al., 1975, as cited by Halbrooks, 1981). The manufacturers do not recommend use of this vaccine in exotic species.

Since the virus involved in this case was not identified, other explanations for the cause of the disease should be considered. These include the triggering of a latent canine distemper virus infection by the vaccination procedure (Bestetti et al., 1978) and immunoincompetence.

Canine distemper is a serious disease of carnivores with high mortality in susceptible animals. Thus, it is advisable to vaccinate all wild carnivores in zoological gardens. However, dogs vaccinated with some inactivated vaccines failed to develop good humoral and cellular response and were not protected against a challenge (Sedgwick and Young, 1968; Montali et al., 1983). This is a contradistinction to the findings of Williams et al. (1988) who reported neutralizing antibody titers in six healthy black-footed ferrets (*Mustela nigripes*) inoculated with an inactivated canine distemper virus vaccine with adjuvant.

Inactivated canine distemper vaccines have not been available for some time in South Africa. Two types of modified-live

canine distemper vaccines are available in South Africa. One is derived from either virulent Rockborn or Snyder-Hill strain, which has been attenuated by serial passage in canine cell lines. The other contains Onderstepoort canine distemper strain, which has been attenuated through passage in chicken embryos. The chicken embryo attenuated strain of distemper virus can be safely used in the bush dog (Sedgwick and Young, 1968; Montali et al. 1983). Montali et al. (1983) did not comment on use of canine cell-derived vaccine in the bush dog. In view of our case, we conclude that the canine cell attenuated vaccine may be pathogenic in the bush dog. It would thus seem prudent to recommend the use of the chicken-derived vaccine in exotic species in zoological gardens in South Africa.

LITERATURE CITED

- BESTETTI, G., R. FATZER, AND R. FRANKHAUSER. 1978. Encephalitis following vaccination against distemper and infectious hepatitis in the dog. *Acta Neuropathologica* 43: 69-75.
- BUSH, M., R. J. MONTALI, D. BROWNSTEIN, A. E. JAMES, AND M. J. G. APPEL. 1976. Vaccine-induced canine distemper in a lesser panda. *Journal of the American Veterinary Medical Association* 169: 959-960.
- CARPENTER, J. W., M. J. G. APPEL, R. C. ERICKSON, AND M. N. NOVILLA. 1976. Fatal vaccine-induced distemper virus infection in black-footed ferrets. *Journal of the American Veterinary Medical Association* 169: 961-964.
- GOSS, L. W., C. R. COLE, AND H. ENGEL. 1948. Inclusion bodies with special application to clinical diagnosis of canine distemper. *Journal of the American Veterinary Medical Association* 112: 236-237.
- GREENE, E. C. 1984. Canine distemper. In *Clinical microbiology and infectious diseases of the dog and cat*, E. C. Greene (ed.). W. B. Saunders Company, Philadelphia, Pennsylvania, pp. 386-401.
- HALBROOKS, R. D., L. J. SWANGO, P. R. SCHURRENBERGER, F. E. MITCHELL, AND E. P. HILL. 1981. Response of gray foxes to modified-live virus canine distemper vaccine. *Journal of the American Veterinary Medical Association* 179: 1170-1174.
- HARTLEY, W. J. 1974. A post-vaccinal inclusion body encephalitis in dogs. *Veterinary Pathology* 11: 301-312.
- KAZACOS, K. R., H. L. THACKER, H. L. SHIVAPRASAD, AND P. P. BURGER. 1981. Vaccine-induced distemper in kinkajous. *Journal of the American Veterinary Medical Association* 179: 1166-1168.
- MCCORMICK, A. E. 1983. Canine distemper in African Cape hunting dogs (*Lycan pictus*)—Possibly vaccine induced. *Journal of Zoo Animal Medicine* 14: 66-71.
- MONTALI, R. J., C. R. BARTZ, J. A. TEARE, J. T. ALLEN, M. J. G. APPEL, AND M. BUSH. 1983. Clinical trials with canine distemper vaccines in exotic carnivores. *Journal of the American Veterinary Medical Association* 183: 163-166.
- , ———, AND M. BUSH. 1987. Canine distemper virus. In *Virus infections of carnivores*, M. J. Appel (ed.). Elsevier Science Publishers, Amsterdam, The Netherlands, p. 441.
- SEDGWICK, C. J., AND W. A. YOUNG. 1968. Distemper outbreak in a zoo. *Modern Veterinary Practice* 49: 39-42.
- THOMAS-BAKER, B. 1985. Vaccination-induced distemper in maned wolves, vaccination-induced corneal opacity in a maned wolf. *Proceedings of the American Association of Zoo Veterinarians. Annual Report. Scottsdale, Arizona*, p. 53.
- VAN HEERDEN, J., BAINBRIDGE, N., R. E. J. BURROUGHS, AND N. P. J. KRIEK. 1989. Distemper-like disease and encephalitozoonosis in wild dogs (*Lycan pictus*). *Journal of Wildlife Diseases* 25: 70-75.
- WILLIAMS, E. S., E. T. THORNE, M. J. G. APPEL, AND D. W. BELITSKY. 1988. Canine distemper in black-footed ferrets (*Mustela nigripes*) from Wyoming. *Journal of Wildlife Diseases* 24: 385-398.

Received for publication 24 October 1990.