

Probable Herpesvirus Infection in an Eastern Cottontail (*Sylvilagus floridanus*)

Authors: Schmidt, Stephen P., Bates, George N., and Lewandoski, Paul J.

Source: Journal of Wildlife Diseases, 28(4) : 618-622

Published By: Wildlife Disease Association

URL: <https://doi.org/10.7589/0090-3558-28.4.618>

The BioOne Digital Library (<https://bioone.org/>) provides worldwide distribution for more than 580 journals and eBooks from BioOne's community of over 150 nonprofit societies, research institutions, and university presses in the biological, ecological, and environmental sciences. The BioOne Digital Library encompasses the flagship aggregation BioOne Complete (<https://bioone.org/subscribe>), the BioOne Complete Archive (<https://bioone.org/archive>), and the BioOne eBooks program offerings ESA eBook Collection (<https://bioone.org/esa-ebooks>) and CSIRO Publishing BioSelect Collection (<https://bioone.org/csiro-ebooks>).

Your use of this PDF, the BioOne Digital Library, and all posted and associated content indicates your acceptance of BioOne's Terms of Use, available at www.bioone.org/terms-of-use.

Usage of BioOne Digital Library content is strictly limited to personal, educational, and non-commercial use. Commercial inquiries or rights and permissions requests should be directed to the individual publisher as copyright holder.

BioOne is an innovative nonprofit that sees sustainable scholarly publishing as an inherently collaborative enterprise connecting authors, nonprofit publishers, academic institutions, research libraries, and research funders in the common goal of maximizing access to critical research.

Probable Herpesvirus Infection in an Eastern Cottontail (*Sylvilagus floridanus*)

Stephen P. Schmidt,¹ George N. Bates,² and Paul J. Lewandoski,¹ ¹ Wisconsin Department of Agriculture, Trade & Consumer Protection, Wisconsin Animal Health Laboratory, Madison, Wisconsin 53705, USA; ² Wildlife Department, Wisconsin Humane Society, Milwaukee, Wisconsin 53225, USA

ABSTRACT: One wild eastern cottontail (*Sylvilagus floridanus*) from Milwaukee County, Wisconsin was necropsied. The lungs contained numerous multifocal, circumscribed, tan foci; the spleen was markedly enlarged and had a mottled reddish tan color; and the brain had a red to tan friable tract in the left hemisphere. Microscopically, the lung had a severe bronchiolitis and pneumonia. The bronchiolitis was characterized by epithelial cells containing eosinophilic intranuclear inclusion bodies. The encephalomalacia of the left cerebral cortex featured tissue disruption and astrocytes or neurons containing intranuclear inclusion bodies. Herpesvirus particles were found within the bronchiolar epithelial cells. Based on histopathological and ultrastructural findings, a herpesvirus seemed the most likely etiologic agent.

Key words: *Sylvilagus floridanus*, eastern cottontail, rabbit, herpesvirus, pathology, case report.

A young adult (≥ 6 -month-old) cottontail (*Sylvilagus floridanus*) was found in a parking lot in Milwaukee County, Wisconsin, USA (42°56'N, 87°53'W). The animal was thin, slightly dehydrated and weighed approximately 1.2 kg. On physical examination, the cottontail was depressed, had visual deficits, and was treated with a 3 mg/kg intramuscular (IM) injection of 4 mg/ml dexamethasone sodium phosphate (Burns Veterinary Supply, Oakland, California, USA). The next day the animal was dyspneic and therapy included another 3 mg/kg IM injection of dexamethasone and a 50 mg/kg IM injection of 100 mg/ml chloramphenicol succinate (Chloromycetin, Parke Davis, Morris Plains, New Jersey, USA). The following day, the dyspnea was severe and the animal was convulsing. Due to the severity and progression of the clinical signs, the cottontail was anesthetized with a 0.3 ml IM injection of a 5:1 combination of 100 mg/ml ketamine hydrochloride (Aveco

Company, Inc., Fort Dodge, Iowa, USA) and 100 mg/ml xylazine (Rugby Laboratory, Inc., Rockville Centre, New York, USA) and euthanized by a 1.0 ml intracardiac injection of 390 mg/ml pentobarbital sodium (Anthony Products Company, Arcadia, California).

At necropsy, fecal matter was adhered to the perineum. The respiratory system had mucopurulent exudate within the trachea and a multifocal pneumonia. The consolidated pulmonary parenchyma contained numerous multifocal circumscribed tan foci approximately 1 to 2 mm in diameter. The spleen was a mottled reddish tan color and enlarged 10 to 20 times normal. The brain was slightly enlarged and edematous. On cut surface, the left hemisphere contained a red to tan friable tract extending from the midcerebrum to the frontal lobe. No other macroscopic changes were observed in this animal.

The Wisconsin Animal Health Laboratory received brain, lung, and spleen fixed in 10% neutral buffered formalin for histological evaluation. For light microscopy, 6 μ m sections of paraffin-embedded tissue were stained with hematoxylin and eosin (H&E), Brown and Hopps (B&H), and Grocott's methenamine silver (Carson, 1990). For electron microscopy, 1 to 2 mm blocks of pulmonary tissue were post-fixed in 0.1 M phosphate buffered 4% glutaraldehyde, rinsed in 0.1 M phosphate buffer followed by 2% buffered osmium tetroxide (Glauert, 1974; Bozzola and Russell, 1992). The tissues were dehydrated in a graded series of ethanol, embedded in Durcupan ACM (Flucka AG, Buchs, Switzerland), sectioned at 70 nm, and stained with Reynolds lead citrate and uranyl acetate (Glauert, 1974; Bozzola and Russell, 1992), and

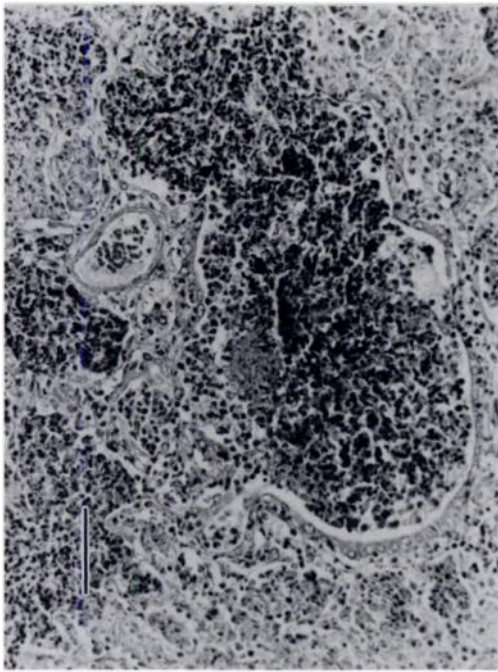


FIGURE 1. Photomicrograph of the lung of the cottontail. Note the dense heterophilic infiltration within a terminal bronchiole. H&E. Bar = 78 μ m.

examined with a Hitachi H-500 microscope (Hitachi Ltd, Tokyo, Japan).

On microscopic examination, significant lesions were observed in the lungs, cerebral cortex, and spleen. The lungs had severe multifocal necroproliferative bronchiolitis and proliferative interstitial pneumonia (Fig. 1). The necrotizing bronchiolitis was characterized by epithelial cell proliferation and necrosis. There were numerous hyperplastic epithelial cells containing well-defined eosinophilic intranuclear inclusion bodies (Fig. 2). The interstitial pneumonia was characterized by Type II pneumocyte proliferation and numerous syncytial cells. Based on B&H stains, scattered colonies of Gram negative bacteria were observed in the pulmonary parenchyma. Fungal hyphae occurred within one terminal bronchiole. These hyphae were approximately 4 μ m in diameter, branched dichotomously, and were partially septate.

The left cerebral cortex, dorsal to the juncture of the internal capsule and corona

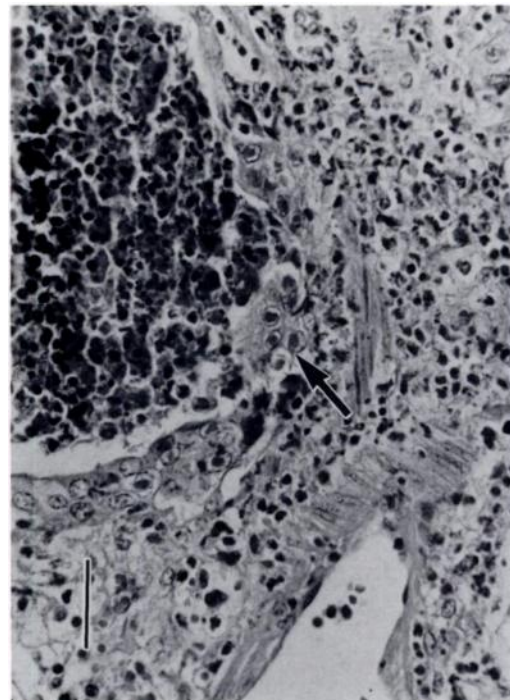


FIGURE 2. Photomicrograph of a terminal bronchiole of the cottontail. Note the bronchiolar epithelial cells which contain intranuclear inclusion bodies (arrow). H&E. Bar = 42 μ m.

radiata and dorsolateral to the hippocampus, contained a tract of encephalomalacia extending rostrally into the frontal lobe. The encephalomalacia was characterized by extensive neuroparenchymal dissolution with hemorrhage, vasculitis with lymphohistiocytic perivascular cuffing, macrophages containing black granular intracytoplasmic pigment, microgliosis, multifocal gemistocytic astrocytes, and neurons and astrocytes with eosinophilic intranuclear inclusion bodies. These inclusion bodies were typified by a homogeneous eosinophilic material encircled by a clear zone between the inclusion body and the margined chromatin at the nuclear membrane (Fig. 3).

The spleen was characterized by severe ischemic necrosis with vasculitis and thrombosis. The cause of the necrosis was not determined.

Using the electron microscope, bacteria and numerous herpesvirus particles were

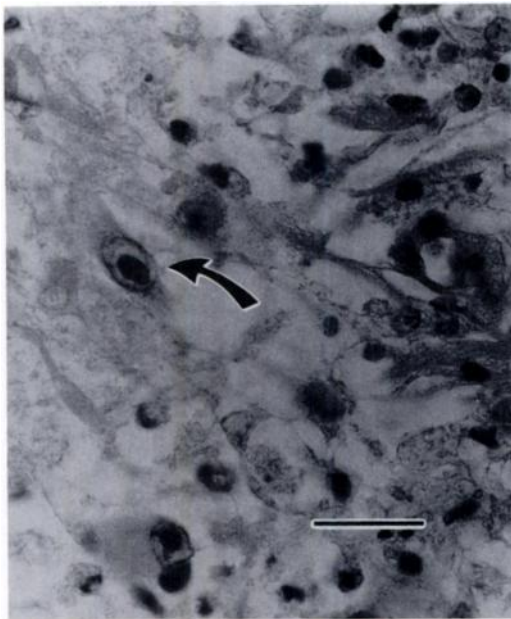


FIGURE 3. Photomicrograph from the cerebral cortex of the cottontail. Note the intranuclear inclusion body (arrow) within the neuron. H&E. Bar = 26 μ m.

observed in the lung. The herpesvirus particles were in the bronchiolar epithelial cells containing intranuclear inclusion bodies (Fig. 4). A few enveloped virus particles also were observed within the cytoplasm of the affected cells. The approximate viral particle sizes were 45 nm for the intranuclear core particles, 95 nm for the intranuclear unenveloped particles, and 135 nm for the enveloped cytoplasmic virus.

The tract of encephalomalacia was compatible with cerebrospinal nematodiasis caused by parasite migration (Jacobson et al., 1976; Kazacos et al., 1981; Nettles et al., 1975). The encephalomalacia was further confounded by the presence of intranuclear inclusion bodies within astrocytes and neurons.

The confirmation of a specific type of herpesvirus depends upon either virus isolation or serological analysis. In this case, neither fresh tissue nor serum were available from the animal. The differential diagnosis could include *Herpesvirus sylvila-*

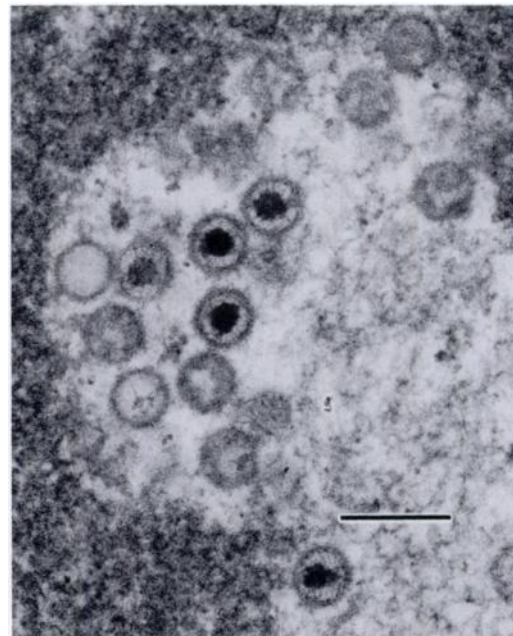

FIGURE 4. Transmission electron photomicrograph of a bronchiolar epithelial cell of the cottontail containing intranuclear particles consistent with herpesvirus. Uranyl acetate and lead citrate. Bar = 170 μ m.

gus, the endemic herpesvirus of wild cottontails, and possibly *H. cuniculi*, the endemic herpesvirus of domestic New Zealand white rabbits (*Oryctolagus cuniculus*).

Wild cottontail and domestic New Zealand white rabbits have their own unique herpesviruses, *H. sylvilagus* and *H. cuniculi*, respectively (Hinze, 1971a; Maré, 1974). Although these distinct herpesviruses cause latent infections in their natural hosts, there is no neutralizing serum activity between the viruses (Hinze, 1971b). Furthermore, domestic rabbits and cottontails may be genetically resistant to each others' latent herpesviruses (Hinze, 1971b).

The pathology of herpesvirus infection differs between the species of virus and their respective host animals. *Herpesvirus cuniculi* causes no macroscopic changes in New Zealand white rabbits; however, microscopic changes include mononuclear cell infiltration and intranuclear inclusion

body formation in the testes, skin, and cornea. The eosinophilic inclusion bodies are distributed in the testicular interstitial cells, corneal epithelium, and endothelium of the skin vasculature (Maré, 1974). However, *H. sylvilagus*, causes acute inflammatory changes in juvenile cottontails and a progressive lymphoproliferative disorder in adults (Hinze, 1971b; Hesselton et al., 1988).

The cottontail herpesvirus, *H. sylvilagus*, has been isolated and characterized from naturally infected cottontails (Hinze, 1971a). This virus is endemic in wild cottontails; infections are characterized by low grade viremia with concurrent antibody titers (Hinze, 1971a; Spieker and Yuill, 1976). The mode of virus transmission between cottontails has not been confirmed; arthropod and transplacental transmission have been discounted as possible routes (Spieker and Yuill, 1977a, b). In two studies, there was evidence of salivary excretion in experimentally inoculated cottontails (Hesselton et al., 1988; Spieker and Yuill, 1977a).

Herpesvirus sylvilagus causes both inflammatory changes and lymphoid hyperplasia in juvenile and adult cottontails (Hinze, 1971b; Hesselton et al., 1988). The inflammatory changes are more severe in the juveniles and include viral myocarditis, interstitial pneumonia, and lymphocytic myositis. As the infection progresses, the lymphoid tissues undergo reactive hyperplasia. Lymphoid hyperplasia also occurs in nonlymphoid organs such as the lung and kidney (Hinze, 1971b; Hesselton et al., 1988). The ability of *H. sylvilagus* to induce lymphoid proliferation suggests that infected cottontails may be an animal model for Epstein-Barr disease in humans (Hinze, 1971b; Hesselton et al., 1988).

The type A intranuclear inclusion bodies observed in this case have not been reported in cottontails either naturally or experimentally infected with *H. sylvilagus*. There are three possible explanations for these inclusion bodies. First, there may be different strains of *H. sylvilagus* of dif-

fering virulence. Second, the dexamethasone therapy may have depressed immunity, causing herpesvirus recrudescence and intranuclear inclusion body formation. Finally, this infection may have been caused by a previously undescribed herpesvirus which also is endemic to cottontails.

We thank Ms. Susan Samuelson and Ms. Beth Byrne for their cooperation and histotechnological support and Mr. Craig Radi for his photographic assistance. We are also grateful to Ms. Ronné Belk for typing drafts of this manuscript. And lastly, we thank Dr. Harry Hinze for reviewing our case materials and manuscript.

LITERATURE CITED

- BOZZOLA, J. J., AND L. D. RUSSELL. 1992. Electron microscopy principles and techniques for biologists. Jones and Bartlett Publishers, Boston, Massachusetts, pp. 14-37.
- CARSON, F. L. 1990. Histotechnology: A self-instructional text. American Society of Clinical Pathologists Press, Chicago, Illinois, pp. 194-201.
- GLAUERT, A. M. 1974. Fixation, dehydration and embedding of biological specimens. In Practical methods in electron microscopy (III), A. M. Glauert (ed.). American Elsevier Publishing Company, New York, New York, pp. 111-170.
- HELSELTON, R. M., W. C. YANG, P. MEDVECZKY, AND J. L. SULLIVAN. 1988. Pathogenesis of *Herpesvirus sylvilagus* infection in cottontail rabbits. American Journal of Pathology 133: 639-647.
- HINZE, H. C. 1971a. New member of the herpesvirus group isolated from wild cottontail rabbits. Infection and Immunity 3: 350-354.
- . 1971b. Induction of lymphoid hyperplasia and lymphoma-like disease in rabbits by *Herpesvirus sylvilagus*. International Journal of Cancer 8: 514-522.
- JACOBSON, H. A., P. F. SCANLON, V. F. NETTLES, AND W. R. DAVIDSON. 1976. Epizootiology and an outbreak of cerebrospinal nematodiasis in cottontail rabbits and woodchucks. Journal of Wildlife Diseases 12: 357-360.
- KAZACOS, K. R., G. O. APPEL, AND H. L. THACKER. 1981. Cerebrospinal nematodiasis in a woodchuck suspected of having rabies. Journal of the American Veterinary Medical Association. 179: 1102-1104.
- MARÉ, C. J. 1974. Viral diseases. In The biology of the laboratory rabbit, S. H. Weisbroth, R. E. Flatt, and A. L. Kraus (eds.). Academic Press, New York, New York, pp. 237-257.
- NETTLES, V. F., W. R. DAVIDSON, S. K. FISK, AND

- H. A. JACOBSON. 1975. An epizootic of cerebrospinal nematodiasis in cottontail rabbits. *Journal of the American Veterinary Medical Association* 167: 600-602.
- SPIEKER, J. O., AND T. M. YUILL. 1976. *Herpesvirus sylvilagus* in cottontail rabbits: Antibody prevalence and flea burden relationships. *Journal of Wildlife Diseases* 12: 310-314.
- , AND ———. 1977a. *Herpesvirus sylvilagus* in cottontail rabbits: Evidence of shedding but not transplacental transmission. *Journal of Wildlife Diseases* 13: 85-89.
- , AND ———. 1977b. *Herpesvirus sylvilagus* in cottontail rabbits: Attempted laboratory transmission by two insect species. *Journal of Wildlife Diseases* 13: 90-93.

Received for publication 7 November 1991.