



Sparganosis in the Monotremes *Tachyglossus aculeatus* and *Ornithorhynchus anatinus* in Australia

Authors: Whrttington, Richard, Middleton, David, Spratt, David M., Muntz, Fenella, Carmel, Brendan, et al.

Source: Journal of Wildlife Diseases, 28(4) : 636-640

Published By: Wildlife Disease Association

URL: <https://doi.org/10.7589/0090-3558-28.4.636>

BioOne Complete (complete.BioOne.org) is a full-text database of 200 subscribed and open-access titles in the biological, ecological, and environmental sciences published by nonprofit societies, associations, museums, institutions, and presses.

Your use of this PDF, the BioOne Complete website, and all posted and associated content indicates your acceptance of BioOne's Terms of Use, available at www.bioone.org/terms-of-use.

Usage of BioOne Complete content is strictly limited to personal, educational, and non - commercial use. Commercial inquiries or rights and permissions requests should be directed to the individual publisher as copyright holder.

BioOne sees sustainable scholarly publishing as an inherently collaborative enterprise connecting authors, nonprofit publishers, academic institutions, research libraries, and research funders in the common goal of maximizing access to critical research.

Sparganosis in the Monotremes *Tachyglossus aculeatus* and *Ornithorhynchus anatinus* in Australia

Richard Whittington,^{1,10} David Middleton,² David M. Spratt,³ Fenella Muntz,⁴ Brendan Carmel,² Helen E. McCracken,⁵ Michael R. Strakosch,⁶ Jill Stephanson-Shaw,⁷ Peter A. W. Harper,⁸ and W. J. Hartley,⁹ ¹ 47 Menangle Road, Camden 2570, Australia; ² Healesville Sanctuary, P.O. Box 248, Healesville 3777, Australia; ³ Division of Wildlife and Ecology, Commonwealth Scientific and Industrial Research Organisation, P.O. Box 84, Lyneham 2602, Australia; ⁴ University of Melbourne, Veterinary Clinical Centre, Werribee, 3030 Australia; ⁵ Royal Melbourne Zoological Gardens, Parkville, 3052, Australia; ⁶ 49 Walker Street, Helensburgh 2508, Australia; ⁷ Centre for Early Human Development, Monash Medical Centre, Monash University, Clayton 3168, Australia; ⁸ New South Wales Department of Agriculture, Agricultural Research and Advisory Station, Grafton 2460, Australia; ⁹ Taronga Zoo, P.O. Box 20, Mosman 2088, Australia; ¹⁰ Present address: NSW Agriculture, Elizabeth Macarthur Agricultural Institute, PMB 8, Camden 2570, Australia

ABSTRACT: Sparganosis in the echidna, *Tachyglossus aculeatus*, is characterized by large subcutaneous masses that may be confused with neoplasms. Plerocercoids, believed to be *Spirometra erinacei*, were found in the ventral or lateral subcutaneous tissues of three echidnas. In each case there was a prominent fibrous mass ≤ 12 cm in diameter enclosing plerocercoids, which were surrounded by an intense inflammatory infiltrate dominated by plasma cells and lymphocytes, with focal suppuration. Multiple, small (≤ 2 mm) plerocercoids were present in the lungs and pleural cavity of a fourth echidna that died due to severe pneumonitis. Several plerocercoids also were found in the lung of a platypus (*Ornithorhynchus anatinus*) associated with parenchymal compression and focal pneumonia.

Key words: Monotreme, echidna, *Tachyglossus aculeatus*, platypus, *Ornithorhynchus anatinus*, cestodes, *Spirometra erinacei*, plerocercoids, natural infection, pneumonia, pathology, case reports, Australia.

Sparganosis is the infection of a vertebrate with the larval stage, called a plerocercoid or sparganum, of a pseudophyllidean cestode. Carnivorous eutherian mammals are the definitive hosts for *Spirometra erinacei*, the pseudophyllidean cestode most often involved in cases of sparganosis in Australia. Several helminth parasites are known from monotremes; *S. erinacei* is known from the echidna (*Tachyglossus aculeatus*) but has not been reported from the platypus (*Ornithorhynchus anatinus*); its significance in both hosts is unknown (Spratt et al., 1991). We report clinical sparganosis in four echidnas and an incidental infection with spargana in a platypus.

Echidna 1 was a captive, mature female

held at Healesville Sanctuary, Healesville, Victoria, Australia (145°30'E, 37°39'S). In November 1986, a discrete mass 10 cm in diameter and suspected on clinical grounds to be a neoplasm, was noticed on the left flank. This was removed surgically together with numerous smaller satellite lesions. The latter were difficult to dissect from surrounding tissues. The main mass was firm and its cut surface was pale, avascular and had a rough follicular or granular appearance.

Echidna 2 was a wild, mature female presented in June 1987 to Healesville Sanctuary for veterinary assessment. The origin of the animal was not recorded. There was a firm mass 12 cm in diameter on the ventrolateral abdominal wall (Fig. 1) suspected of being neoplastic. The animal was euthanized by intravenous injection of 200 mg/kg pentobarbitone sodium (Apex Laboratories Pty. Ltd., St. Marys, New South Wales, Australia). At necropsy, the mass was located in the subcutis, free of attachment to the skin or deep musculature. It was encapsulated and its cut surface was pale and relatively avascular. No other lesions were observed.

Echidna 3 was a wild, adult female found in November 1984 as a road-kill on Kangaroo Island, South Australia (35°48'S, 136°40'E). A large mass was observed in the subcutis of the ventral abdomen.

Echidna 4 was a mature male that had been held at Royal Melbourne Zoological Gardens, Melbourne, Victoria, Australia (144°58'E, 37°48'S) for at least 18 mo prior to transfer to Ballarat Wildlife and Reptile

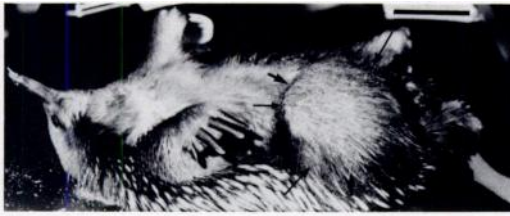

FIGURE 1. Echidna 2. There is a 12 cm diameter, well circumscribed mass in right ventrolateral skin (delimited by arrows). Bar = 7.5 cm.

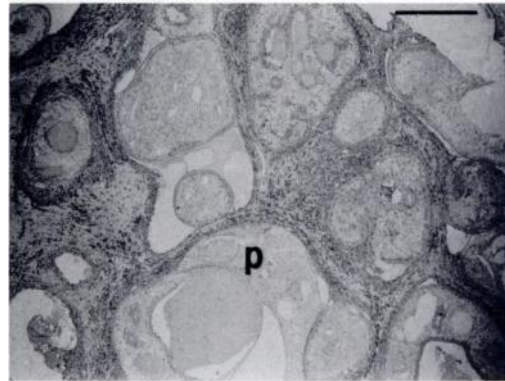


FIGURE 2. Photomicrograph of the subcutaneous mass from echidna 2. Multiple cross sections of pleurocercoid (p) are separated by fibrous tissue and mixed inflammatory infiltrate. H&E. Bar = 450 μ m.

Park, Ballarat, Victoria, Australia (143°53'E, 37°31'S) in September 1990. Self-limiting, mild dyspnea was noted several months prior to transfer, but recurred immediately after transfer. The echidna died 3 wk later, after an episode of severe dyspnea. At necropsy, all lobes of both left and right lungs were consolidated and contained multiple, white, hard foci. There was an increased volume of pale pink, opaque pleural fluid containing vast numbers of white, flocculent particles ≤ 2 mm in diameter; this fluid also contained 82 g/l of protein and 163×10^9 nucleated cells/l (65% neutrophils, 15% lymphocytes, 20% macrophages or mesothelial cells), based on the methods of Benjamin (1978).

The platypus was a wild, mature female found in April 1988 enmeshed in a wire fence in a creek at Figtree, near Wollongong, New South Wales, Australia (34°20'S, 149°10'E). It died 2 days after presentation for veterinary treatment of palmar lacerations. At necropsy, focal consolidation, a white tract, and irregular pale foci were observed in the margin of the left lung.

Portions of the subcutaneous mass or lung of each echidna and lung from the platypus were fixed in 10% neutral buffered formalin, embedded in paraffin, sectioned at 5 μ m and stained with hematoxylin and eosin and by the periodic-acid-Schiff (PAS) reaction (Luna, 1968). Sections were deposited in the non-domestic animal pathology register, Taronga Zoo, Sydney, Australia (B0040, B0055, B0078). For comparative purposes, tissue sections

containing spargana from the cane toad (*Bufo marinus*) and the water rat (*Hydromys chrysogaster*) were provided by Dr. R. Speare, James Cook University, Townsville 4811, Queensland, Australia (File No. 87/661) and Dr. D. Obendorf, Mt. Pleasant Laboratories, Launceston 7249, Tasmania, Australia (File Nos. 82/1524, 82/2090, 82/2548), respectively. Part of a sparganum from the platypus was deposited in the parasite collection, Division of Wildlife and Ecology, Commonwealth Scientific and Industrial Research Organisation, Canberra, Australia (W/L HC No. C677). Fixed pleural cavity plerocercoids from echidna 3 were deposited in the South Australian Museum, Adelaide, Australia (AHC22859).

Histologically, the masses from echidnas 1 and 2 were similar. Each contained multiple sections of plerocercoid (Fig. 2), recognized by their irregular shape; the presence of a thick tegument lined by subtegumental cells, with parenchymal cells, calcareous corpuscles, excretory ducts and muscle fibers; and by the absence of digestive or reproductive tracts (Fig. 3) (von Bonsdorff et al., 1971; Chitwood and Lichtenfels, 1972). Parenchymal tissues of the parasites stained strongly positive with PAS. Viable and non-viable plerocercoids were surrounded by maturing fibrous tissue

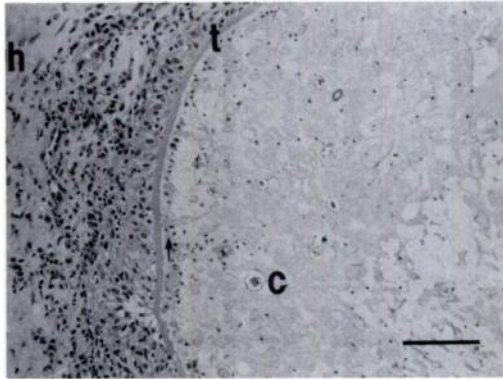


FIGURE 3. Photomicrograph of section of plerocercoid from the subcutaneous mass of echidna 2. Tegument (t), subtegumental cells (arrow), calcareous corpuscles (c), host inflammatory response (h). H&E. Bar = 90 μ m.

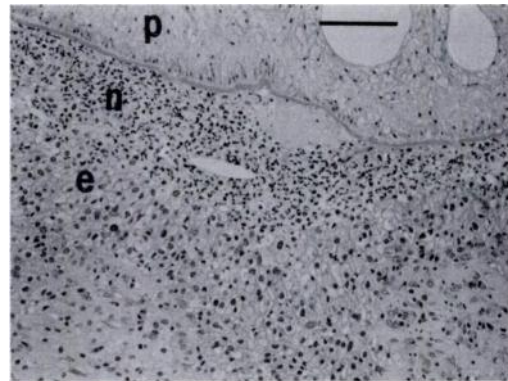


FIGURE 5. Photomicrograph of pyogranulomatous inflammation surrounding a plerocercoid from the subcutaneous mass of echidna 2. Plerocercoid (p), neutrophilic infiltrate (n), epithelioid cells (e). H&E. Bar = 90 μ m.

which was diffusely infiltrated adjacent to the parasites. Infiltrating cells included a large number of plasma cells (Echidna 1) or lymphocytes and plasma cells (Echidna 2) (Fig. 4) accompanied by epithelioid macrophages and polymorphs. Neutrophils were prominent at the host-parasite interface, pooled in the periparasitic space and often were surrounded by a zone of epithelioid cells (Fig. 5). The pyogranulomatous response surrounding sections of non-viable plerocercoid contained a greater proportion of neutrophils than that surrounding viable plerocercoids. Despite

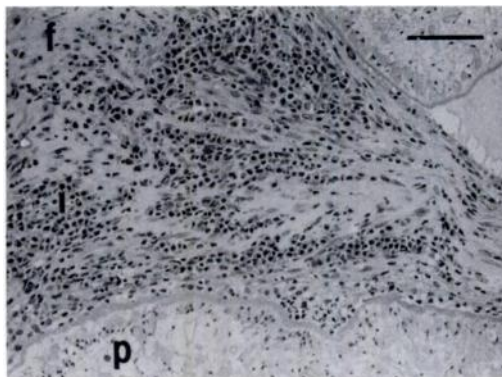


FIGURE 4. Photomicrograph of lymphocytic/plasmacytic infiltrate (i) and fibrous tissue (f) surrounding plerocercoids (p) from the subcutaneous mass of echidna 2. H&E. Bar = 90 μ m.

moderate autolysis of the tissues of Echidna 3 it was apparent that the lesion was similar to those in the other echidnas. However, the plerocercoids all appeared to be degenerate, the fibrous tissue was more mature and inflammatory cells were restricted to focal aggregates of mononuclear cells with lymphocytes predominating.

Little normal lung was present in sections from echidna 4. There was a generalized replacement or compression of parenchyma by numerous small, viable plerocercoids. Foci of suppuration occurred adjacent to small plerocercoids. Diffuse interstitial and intraalveolar mononuclear cell infiltrates dominated by plasma cells extended into larger airways, which also contained small plerocercoids. Alveolar epithelialization, interstitial fibrosis and alveolar edema were present in areas where plerocercoids were less numerous. A large, coiled plerocercoid was located immediately beneath the pleura. The microscopic structures of the small and the large plerocercoids were identical.

Sections of plerocercoid were present in peribronchiolar connective tissue of the platypus. These resulted in compression of parenchyma, and mild focal inflammation. Sections of viable plerocercoid containing extensive areas of PAS-positive ma-

terial were surrounded by an infiltrate of plasma cells, lymphocytes, and macrophages. Adjacent bronchioles contained a similar exudate. Another lesion consisted of an irregularly ovoid, caseous focus diffusely infiltrated by macrophages which contained amorphous, eosinophilic, weakly PAS-positive debris, and by lymphocytes and polymorphs. This was interpreted as being a degenerate plerocercoid.

It is difficult to determine the species of plerocercoid from morphological criteria (Stephanson, 1985). However, we believe that the plerocercoids observed in sections in the cases described here probably were *S. erinacei*. There are two pseudophyllidean cestodes known in non-marine hosts in Australia. The adult of *S. erinacei* occurs in dogs (*Canis familiaris familiaris*), dingoes (*Canis familiaris dingo*), foxes (*Vulpes vulpes*) and cats (*Felis catus*), while the adult of *Diphyllobothrium dendriticum* has been reported in the water rat (Stephanson, 1985; Stephanson et al., 1987). Definitive hosts for both parasites are sympatric with the cases described here, although the dingo is absent from Kangaroo Island. The larval stage of *S. erinacei* occurs in a wide range of amphibian, reptilian and mammalian hosts in Australia (Stephanson, 1985). Conversely, there are no confirmed reports of other plerocercoids in non-marine hosts in Australia. Experimentally, larvae of *D. dendriticum* have limited powers of penetration into host tissues and preferentially invade the tissues of fish (Halvorsen and Wissler, 1973).

Infection of a host with plerocercoids may be due to ingestion either of a copepod containing the first larval stage (proceroid) or of an aquatic, amphibious or terrestrial second intermediate or paratenic host containing a plerocercoid. The natural diet of echidnas consists predominantly of ants and termites, which are not known to be intermediate hosts of pseudophyllidean cestodes. Presumably the echidnas were infected by accidental ingestion of copepods or small amphibians in drinking water. A possible source of in-

fection of the captive echidnas was raw meat, which was included in the diet with other ingredients as a minced slurry. The platypus, which eats a wide range of aquatic invertebrates and sometimes small vertebrates such as tadpoles, frogs, and fish, may have ingested intermediate hosts containing proceroids or plerocercoids.

Factors responsible for the degree of host response and subsequent survival or elimination of plerocercoid parasites are uncertain but a broad spectrum of host responses are recognized (Bylung, 1972; Stephanson, 1985). Following infection of echidnas 1, 2 and 3, plerocercoids migrated to subcutaneous tissues causing dramatic proliferation of fibrous tissue and formation of tumour-like masses, but this response did not consistently destroy the parasites. From the concentration of plasma cells and macrophages around plerocercoids, we inferred a significant antibody-mediated immune response. Specific precipitating antibodies have been demonstrated in the sera of cane toads with chronic inflammatory responses induced by plerocercoids (Bennett, 1978). Due to our bias in this study of selecting echidnas with lesions, it is uncertain whether the responses observed are characteristic of echidnas, or are the extreme. It is interesting to note, however, that in each case the lesions were located on the ventral or lateral body wall, suggesting a degree of tissue tropism.

The pathogenesis of the thoracic lesions containing massive numbers of plerocercoids in echidna 4 is unknown. While synchronous infection with multiple proceroids may be one explanation, another is that plerocercoids may have replicated within the host, in keeping with the rare condition of 'proliferative' sparganosis described in non-human primates and humans (Kuntz et al., 1970; Mueller and Strano, 1974).

The infection in the platypus appeared to be more recent than that in the echidnas. There was evidence that the inflammatory response had destroyed some plerocercoids. There also was indirect evidence of

local antibody production adjacent to plerocercoids in the platypus, as inferred from the presence of plasma cells and macrophages in the cellular infiltrate.

There was no histological evidence of host response surrounding viable plerocercoids in tissues of water rats from Tasmania. Feral pigs, which commonly are infected with plerocercoids in Australia, also do not seem to mount significant inflammatory responses, based on gross observations of spargana in connective tissues (Gordon et al., 1954). In contrast, plerocercoids in thigh muscles of cane toads from Queensland, often were destroyed by severe, chronic, granulomatous inflammation. Consequently, the monotremes seem to be highly reactive in comparison to the responses seen in other hosts infected with plerocercoids in southeastern Australia.

Sparganosis in the echidna causes significant clinical signs and may be confused with cutaneous neoplasia. Due to the spiny pelage of the echidna, cutaneous masses are not apparent until they are very advanced. To prevent sparganosis in captive echidnas, diets free of raw meat or containing appropriately treated meat should be provided as an alternative to current diets (Whittington, 1988). The water supply should be free of copepods and free from contamination by feces of cats, dogs, dingoes and foxes.

Cats and foxes in Australia are believed to be commonly infected with *S. erinacei* (Kelly, 1977), and are widespread and abundant. The prevalence of *S. erinacei* infection in wild monotremes and sympatric definitive hosts requires further assessment, given the potentially serious nature of sparganosis in monotremes.

Drs. Ian Beveridge and Jon Dunsmore gave valuable advice during the preparation of the manuscript.

LITERATURE CITED

- BENJAMIN, M. M. 1978. Outline of veterinary clinical pathology, 3rd ed., The Iowa State University Press, Ames, Iowa, 351 pp.
- BENNETT, L. J. 1978. The immunological responses of amphibians to Australian spargana. *The Journal of Parasitology* 64: 756-759.
- BYLUND, G. 1972. Pathogenic effects of a diphylobothriid plerocercoid on its host fishes. *Commentationes Biologicae* 58: 1-11.
- CHITWOOD, M., AND J. R. LICHTENFELS. 1972. Identification of parasitic metazoa in tissue sections. *Experimental Parasitology* 32: 407-519.
- GORDON, H. MCL., B. A. FORSYTH, AND M. ROBINSON. 1954. Sparganosis in feral pigs in New South Wales. *Australian Veterinary Journal* 30: 135-138.
- HALVORSEN, O., AND K. WISSLER. 1973. Studies of the helminth fauna of Norway XXVIII: an experimental study of the ability of *Diphylobothrium latum* (L.), *D. dendriticum* (Nitzsch), and *D. ditremum* (Creplin) (Cestoda, Pseudophyllidea) to infect paratenic hosts. *Norwegian Journal of Zoology* 21: 201-210.
- KELLY, J. D. 1977. Canine parasitology. Post-Graduate Foundation in Veterinary Science, University of Sydney, Sydney, Australia, 110 pp.
- KUNTZ, R. E., B. J. MYERS, AND A. A. KATZBERG. 1970. Sparganosis and "proliferative" spargana in vervets (*Cercopithecus aethiops*) and baboons (*Papio* sp.) from East Africa. *The Journal of Parasitology* 56: 196-197.
- LUNA, L. G. (ED.). 1968. Manual of histologic staining methods of the Armed Forces Institute of Pathology, 3rd ed. McGraw-Hill Book Company, New York, New York, 258 pp.
- MUELLER, J. F., AND A. J. STRANO. 1974. *Sparganum proliferum*, a sparganum infected with a virus? *The Journal of Parasitology* 60: 15-19.
- SPRATT, D. M., I. BEVERIDGE, AND E. L. WALTER. 1991. A catalogue of Australasian monotremes and marsupials and their recorded helminth parasites. Records of the South Australian Museum, Monograph Series No. 1: 1-105.
- STEPHANSON, J. M. 1985. Biology and immunobiology of *Spirometra* in Western Australia. Ph.D. Thesis. Murdoch University, Murdoch, Western Australia, 247 pp.
- , D. L. OBENDORF, AND G. SHAW. 1987. *Diphylobothrium dendriticum* (Cestoda: Pseudophyllidea) from Tasmania. *Systematic Parasitology* 9: 227-237.
- VON BONSDORFF, C. H., T. FORSTTEN, M. K. S. GUSTAFSSON, AND B. J. WIKGREN. 1971. Cellular composition of plerocercoids of *Diphylobothrium dendriticum* (Cestoda). *Acta Zoologica Fennica* 132: 1-25.
- WHITTINGTON, R. J. 1988. The monotremes in health and disease. In *Australian wildlife. Proceedings of the Post Graduate Committee in Veterinary Science, University of Sydney* 104: 727-787.

Received for publication 16 August 1991.