

Verminous Bronchitis and Bronchiolitis in Potoroid Marsupials Associated with a New *Capillaria* sp.

Authors: Love, Stephen C. J., and Reddacliff, Gary L.

Source: Journal of Wildlife Diseases, 28(4) : 643-645

Published By: Wildlife Disease Association

URL: <https://doi.org/10.7589/0090-3558-28.4.643>

The BioOne Digital Library (<https://bioone.org/>) provides worldwide distribution for more than 580 journals and eBooks from BioOne's community of over 150 nonprofit societies, research institutions, and university presses in the biological, ecological, and environmental sciences. The BioOne Digital Library encompasses the flagship aggregation BioOne Complete (<https://bioone.org/subscribe>), the BioOne Complete Archive (<https://bioone.org/archive>), and the BioOne eBooks program offerings ESA eBook Collection (<https://bioone.org/esa-ebooks>) and CSIRO Publishing BioSelect Collection (<https://bioone.org/csiro-ebooks>).

Your use of this PDF, the BioOne Digital Library, and all posted and associated content indicates your acceptance of BioOne's Terms of Use, available at www.bioone.org/terms-of-use.

Usage of BioOne Digital Library content is strictly limited to personal, educational, and non-commercial use. Commercial inquiries or rights and permissions requests should be directed to the individual publisher as copyright holder.

BioOne is an innovative nonprofit that sees sustainable scholarly publishing as an inherently collaborative enterprise connecting authors, nonprofit publishers, academic institutions, research libraries, and research funders in the common goal of maximizing access to critical research.

Verminous Bronchitis and Bronchiolitis in Potoroid Marsupials Associated with a New *Capillaria* sp.

Stephen C. J. Love¹ and Gary L. Reddacliff,² ¹ Department of Agriculture, Regional Veterinary Laboratory, Private Mail Bag, Armidale, New South Wales 2351, Australia; ² Department of Agriculture, Elizabeth Macarthur Agricultural Institute, Private Mail Bag, Camden, New South Wales 2570, Australia

ABSTRACT: We describe verminous bronchitis and bronchiolitis in potoroid marsupials associated with a new species of *Capillaria* resident in the epithelial lining of bronchi and bronchioles. The parasite was associated with alveolar oedema and emphysema, and a mixed inflammatory cell exudate within and surrounding the airways.

Key words: Bronchitis, bronchiolitis, Potoroidae, *Capillaria* sp., *Aepyprymnus rufescens*, *Bettongia penicillata*, *Potorous tridactylus*, pathology.

Nematodes from the superfamilies Muspiceoidea, Thelazioidea, Metastrongyloidea (Spratt, 1979, 1980, 1984) and more recently Trichinelloidea (Spratt et al., 1991) have been described as occurring in the lungs of Australian marsupials. We report here a new species of *Capillaria* (*Capillaria* sp. n. 7) (Spratt et al., 1991), of the superfamily Trichinelloidea, parasitic in the lungs of potoroid marsupials.

The study was conducted in captive colonies of rufous bettongs (*Aepyprymnus rufescens*) and long-nosed potoroos (*Potorous tridactylus*) at Cowan, New South Wales (NSW) (151°10'E, 33°36'S) in 1982, and at Armidale, NSW (151°30'E, 30°30'S) in 1987. The Cowan colony was established in 1979 with captive-bred rufous bettongs from Blackbutt Reserve, Newcastle, NSW (151°40'E, 32°50'S). Later, animals were added from the Armidale colony and from a local wildlife park. The Armidale colony was established in 1979 with rufous bettongs captured in the surrounding New England region of NSW. Long-nosed potoroos and brush-tailed bettongs (*Bettongia penicillata*) were added later to both colonies. The total population in each colony varied from approximately five to 25 animals. Husbandry conditions were similar in each colony. Enclosures

consisted of a grassed, earthen-floored compound of 1,000 to 1,500 m² subdivided into a number of smaller pens. Within these, grass tussocks and logs were provided for shelter.

Clinical signs in affected animals included dyspnea and coughing, which were exacerbated by exercise, as well as varying degrees of illthrift, nasal discharge and dull demeanor. Moist rales were apparent on thoracic auscultation. Bronchial washings obtained under halothane (Fluothane®, ICI Australia, Melbourne, Australia) anesthesia yielded variable numbers of typical trichinelloid eggs and large numbers of neutrophils. Feces from the three potoroid species in both colonies contained $\leq 1,840$ trichinelloid eggs/g.

Oral treatment of infected animals with fenbendazole (Panacur 10®, Hoechst Australia Limited, Melbourne, Australia) at a dose rate of 25 mg/kg bodyweight once daily for 5 days was followed by a remission of clinical signs over a period of a few weeks and the rapid disappearance of trichinelloid eggs from the feces. *Capillaria* sp. were not detected in one animal with typical pathology which died several weeks after treatment. However, animals with typical clinical signs and pathological changes were found to be infected, presumably reinfected, when necropsied several months after dosing with fenbendazole.

In all, seven affected bettongs and one affected potoroo were necropsied. Lungs were cultured aerobically on 7% sheep blood agar (Oxoid Australia Pty Limited, Melbourne, Australia) and McConkey's agar (Oxoid). Unstained squash preparations of pulmonary lesions and mucus were examined by bright field light microscopy.

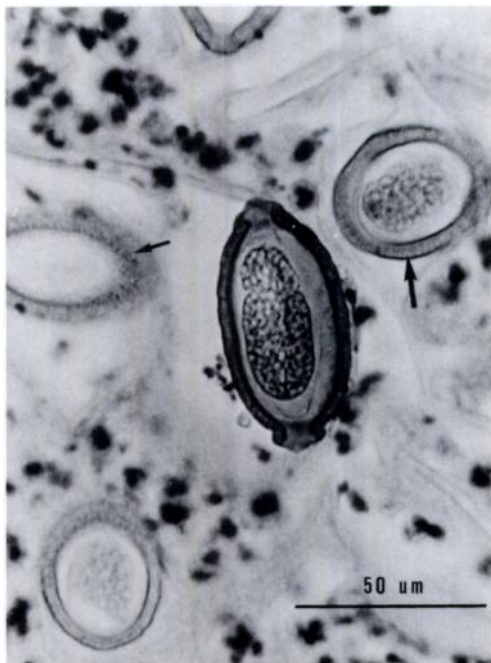

FIGURE 1. Trichinelloid eggs in lumen of bronchiole of *Aepyprymnus rufescens*. Note the surface punctations (small arrow) and the reticulated appearance at the edges (large arrow). (H&E).

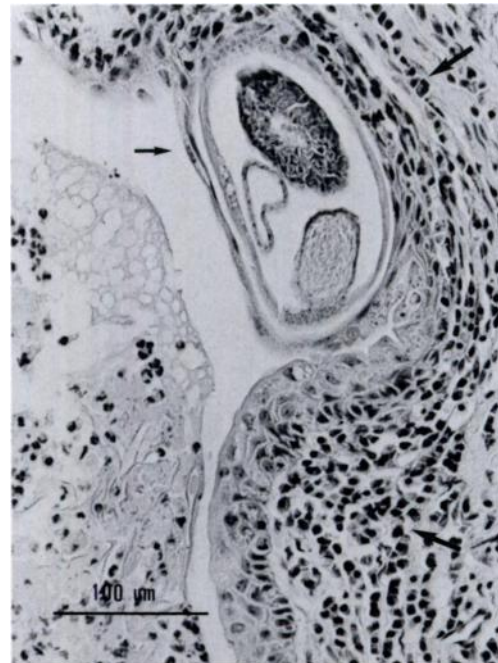


FIGURE 2. Peribronchiolar inflammatory infiltrate (small arrows) and nematode (large arrow) associated with the bronchiolar epithelium of *Aepyprymnus rufescens*. (H&E).

Tissues were fixed in 10% neutral buffered formalin, embedded in paraffin, sectioned at 6 μm and stained with hematoxylin and eosin. Hematology was performed using standard techniques (Benjamin, 1978).

Verminous bronchitis and bronchiolitis were major factors in the death, or the decision to euthanize four bettongs. Euthanasia was by intravenous injection into the lateral tail vein of 325 mg/ml pentobarbitone sodium (Arnolds of Reading Pty Limited, Boronia, Australia). Gross pathological changes in uncomplicated cases were confined to the lungs. The lungs contained many pale yellow-grey slightly raised foci 1 to 5 mm in diameter throughout the parenchyma of all lobes, and contained thick brownish mucus in the airways. No pathogenic bacteria were isolated and no suspect hematologic values were observed. However, numerous eggs, larvae and adult capillariid nematodes were observed in squash preparations of pulmo-

nary lesions and mucus. Similar pathological changes were observed in all lung sections. There was variable congestion and focal to locally extensive alveolar edema and emphysema. However, most changes were centered on the airways, with few bronchi and bronchioles remaining unaffected. Bronchiectasis was evident. Necrotic debris, desquamated epithelial cells, neutrophils, amorphous eosinophilic material, and nematodes and trichinelloid eggs occupied the lumens of bronchi and bronchioles (Fig. 1). Nematodes were located on and within the bronchial and bronchiolar epithelium, causing erosion and necrosis. Infiltrates were present in bronchiolar epithelium and to a greater extent in the lamina propria, muscular layer and adventitia (Fig. 2). The infiltrates were dominated by lymphocytes, macrophages and plasma cells, but not eosinophils. Peribronchiolar lymphocytic nodules also were evident.

Eggs from histological sections, bronchial washings and feces were of typical trichinelloid morphology: barrel-shaped with bipolar plugs and an ornamented surface. Eggs were thick-shelled, 63 to 77 μm long, 29 to 33 μm wide and ornamented with relatively dense punctations, but producing a reticulated appearance at the edges (Fig. 1). This pattern of surface ornamentation on the egg shell is similar to that described by Baylis (1926) for *Capillaria hepatica*. The spicule of the male was 600 μm long, robust, flexible, and similar to that of *C. hepatica*. However the cirrus in males from the lungs of potoroid marsupials was adorned with numerous, large spines, and there was no vulval flap in the females. In contrast, males of *C. hepatica* do not possess a spiny cirrus and females have a bell-shaped, cuticular vulval flap.

The capillariid nematode from potoroids is distinguished from *C. aerophila* which occurs in the epithelial lining of the bronchi and bronchioles of feral cats in Tasmania, by its thicker egg shell and the pattern of ornamentation (fine reticulate pattern of ridges in *C. aerophila* (Butterworth and Beverly-Burton, 1980), the robust and sclerotised form of the spicule (fine and not sclerotised in *C. aerophila*) and the short rectum (300 μm in females from potoroids, 520 to 750 μm in *C. aerophila*) in the female. The species from potoroids can be distinguished from other species of *Capillaria* known to occur in Australian marsupials (D. M. Spratt, pers. comm.). This new *Capillaria* sp. is not considered to be a known capillariid in an aberrant host and is recognized as an undescribed species, *Capillaria* sp. nov. 7, parasitic in potoroids (Spratt et al., 1991).

We thank Dave Spratt, Division of Wildlife & Ecology, CSIRO for determination of and advice concerning the parasite concerned, Bill Johns of RVL Armidale for his work on the photography and parasitology, Ray Williams of the University of NSW, Cowan Field Station for bringing the first animals to our attention, Stuart Green, Peter Jarman and Ian Wallis of The University of New England, Armidale for their cooperation in the investigation of the problem, and Taronga Zoo, Sydney, where the initial investigations into the Cowan colony were performed.

LITERATURE CITED

- BAYLIS, H. A. 1926. A new species of *Hepaticola* from the rat's stomach. *Journal of Tropical Medicine and Hygiene* 29: 226-229.
- BENJAMIN, M. M. 1978. Outline of veterinary clinical pathology. The Iowa State University Press, Ames, Iowa, U.S.A.
- BUTTERWORTH, E. W. AND M. BEVERLY-BURTON. 1980. The taxonomy of *Capillaria* spp. (Nematoda: Trichuroidea) in carnivorous mammals from Ontario, Canada. *Systematic Parasitology* 1: 211-236.
- SPRATT, D. M. 1979. A taxonomic revision of the lungworms (Nematoda: Metastrongyloidea) from Australian marsupials. *Australian Journal of Zoology, Supplementary Series*, No. 67, pp. 1-45.
- SPRATT, D. M. 1980. *Metathelazia neghiensis* sp. n. (Nematoda: Pneumospiruridae) from the long-nosed bandicoot, *Perameles nasuta* (Marsupialia). *The Journal of Parasitology* 66: 1032-1035.
- SPRATT, D. M. 1984. Further studies of lung parasites (Nematoda) from Australian marsupials. *Australian Journal of Zoology* 32: 283-310.
- SPRATT, D. M., I. BEVERIDGE, AND E. L. WALTER. 1991. A catalogue of Australasian monotremes and marsupials and their recorded helminth parasites. Records of the South Australian Museum, Monograph Series, No. 1. South Australian Museum, Adelaide, Australia. 105 pp.

Received for publication 11 October 1991.