



Phocine Distemper in a Harp Seal (*Phoca groenlandica*) from the Gulf of St. Lawrence, Canada

Authors: Daoust, P.-Y., Haines, D. M., Thorsen, J., Duignan, P. J., and Geraci, J. R.

Source: Journal of Wildlife Diseases, 29(1) : 114-117

Published By: Wildlife Disease Association

URL: <https://doi.org/10.7589/0090-3558-29.1.114>

BioOne Complete (complete.BioOne.org) is a full-text database of 200 subscribed and open-access titles in the biological, ecological, and environmental sciences published by nonprofit societies, associations, museums, institutions, and presses.

Your use of this PDF, the BioOne Complete website, and all posted and associated content indicates your acceptance of BioOne's Terms of Use, available at www.bioone.org/terms-of-use.

Usage of BioOne Complete content is strictly limited to personal, educational, and non - commercial use. Commercial inquiries or rights and permissions requests should be directed to the individual publisher as copyright holder.

BioOne sees sustainable scholarly publishing as an inherently collaborative enterprise connecting authors, nonprofit publishers, academic institutions, research libraries, and research funders in the common goal of maximizing access to critical research.

Phocine Distemper in a Harp Seal (*Phoca groenlandica*) from the Gulf of St. Lawrence, Canada

P.-Y. Daoust,¹ D. M. Haines,² J. Thorsen,³ P. J. Duignan,⁴ and J. R. Geraci,⁴ ¹ Department of Pathology and Microbiology, Atlantic Veterinary College, University of Prince Edward Island, Charlottetown, Prince Edward Island, Canada C1A 4P3; ² Department of Veterinary Microbiology, Western College of Veterinary Medicine, University of Saskatchewan, Saskatoon, Saskatchewan, Canada S7N 0W0; ³ Department of Veterinary Microbiology and Immunology, Ontario Veterinary College, University of Guelph, Guelph, Ontario, Canada N1G 2W1; ⁴ Department of Pathology, Ontario Veterinary College, University of Guelph, Guelph, Ontario, Canada N1G 2W1

ABSTRACT: The first case of phocine distemper in a seal from Canadian waters and the first case of clinical phocine distemper in a harp seal, *Phoca groenlandica*, is reported. A two-month-old female harp seal stranded on Prince Edward Island in May 1991. Significant clinical findings were lethargy and severe conjunctivitis. Pulmonary congestion was the main necropsy finding, and histological lesions included diffuse demyelinating nonsuppurative encephalitis and mild multifocal interstitial pneumonia. Acidophilic intracytoplasmic and intranuclear inclusions were present in cerebral neurons and astrocytes. Immunoperoxidase staining confirmed phocine distemper virus (PDV) antigen in the cytoplasm and nuclei of neurons, bronchiolar gland epithelium and transitional epithelium of the bladder. Infectivity titers of canine distemper virus (CDV) (Onderstepoort strain) and a morbillivirus isolated from a grey seal were significantly reduced by serum from the harp seal.

Key words: *Phoca groenlandica*, harp seal, morbillivirus, phocine distemper, nonsuppurative encephalitis, immunoperoxidase staining, serum neutralization titer, first case.

We report the first case of clinical phocine distemper in a harp seal, *Phoca groenlandica*, from the Gulf of St. Lawrence, Canada. Phocine distemper, an infectious disease caused by a morbillivirus, was responsible for the death of approximately 17,000 harbor seals, *Phoca vitulina*, and a few hundred grey seals, *Halichoerus grypus*, around the coast of northwestern Europe in 1988 (Kennedy, 1990). The source of the virus and the reasons for its emergence have not been clearly determined (Harwood and Grenfell, 1990; Markussen and Have, 1992). Nucleotide sequence analysis showed that the phocine distemper virus, now called PDV 1, was distinct from other members of the genus,

including canine distemper virus (CDV), rinderpest virus and human measles virus (MV) (Curran et al., 1990; Orvell and Sheshberadaran, 1991). Since the European epizootic, there have been several serological surveys conducted on pinniped populations worldwide. Antibodies to a morbillivirus have been found in a small number of harbor seal sera collected prior to 1988 (Osterhaus et al., 1989), in Greenland harp seals (*Phoca groenlandica*), and ringed seals (*Phoca hispida*) (Dietz et al., 1989), harp seals from Spitzbergen and Jan Mayen Island (Markussen and Have, 1992), harbor seals and grey seals caught on Sable Island, Nova Scotia, Canada (Ross et al., 1992), Antarctic crabeater seals, *Lobodon carcinophagus*, and leopard seals, *Hydrurga leptonyx* (Bengtson et al., 1991). Thus, one or more strains of morbillivirus are enzootic in several pinniped populations.

On 14 May 1991 wardens from a national park on the north shore of Prince Edward Island, in the Gulf of St. Lawrence, Canada (46°25'N, 63°10'W), reported the stranding of a moribund female harp seal that was a pup-of-the-year and approximately 2-mo-old (Seargant, 1976). It was observed for almost one week before it was taken to the Atlantic Veterinary College, University of Prince Edward Island. The seal was lethargic and had severe congestion and edema of the conjunctiva of both eyes and cyanosis of the buccal mucosa. There were a few small cutaneous lesions on the dorsum that probably were caused by gulls. Radiographic examination of the thorax revealed increased density in both lungs. The seal was euthanized by a

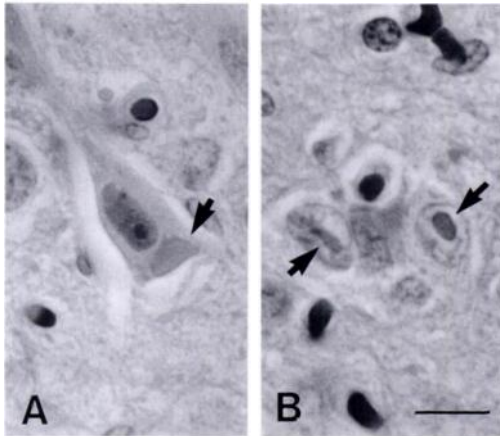


FIGURE 1. A) Degenerated neuron (angular cytoplasmic borders, condensed nuclear chromatin) containing an intracytoplasmic inclusion body (arrow). B) Two swollen astrocytes with intranuclear inclusion bodies (arrows). Cerebral cortex. H&E. Bar = 10 μ m.

15 ml injection of pentobarbital (240 mg/ml) (Livingston Pharmaceuticals, Moncton, New Brunswick, Canada) into the extradural intravertebral vein. On postmortem examination, the carcass was in good condition with 3 to 4 cm of blubber. The lungs were congested but normal in consistency, while the digestive tract was empty apart from nematodes, tentatively identified as *Contracecum osculatum*, attached to the gastric mucosa. Tissue samples were fixed in 10% neutral buffered formalin, embedded in paraffin, sectioned, and stained with hematoxylin and eosin (H&E).

Diffuse demyelinating nonsuppurative encephalitis was the most significant histological finding. Acidophilic intracytoplasmic and intranuclear inclusions of variable size were present in neurons and astrocytes (Fig. 1). Degenerated neurons and swollen astrocytes were common, and there was a moderate degree of astrogliosis in the more severely affected areas. Perivascular cuffs composed of histiocytes, and to a lesser extent lymphocytes, were present around some blood vessels. Lesions of demyelination consisted of multiple large vacuoles in the white matter, many

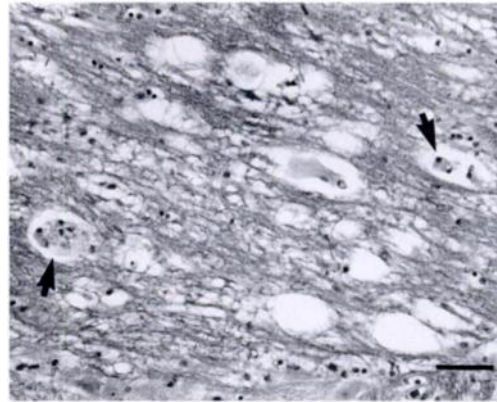


FIGURE 2. Lesions of demyelination in the cerebral cortex. Several large vacuoles, representing swollen myelin sheaths, are present. Some of these vacuoles are filled with histiocytes (arrows). H&E. Bar = 50 μ m.

of which were filled with large histiocytes (Fig. 2). Inclusion bodies were not seen in other organs. The cranial and ventromedial regions of the lungs were atelectatic and congested and contained small multifocal areas of Type II pneumocyte proliferation. Syncytia were not observed.

An avidin biotin complex (ABC) immunoperoxidase histochemical stain was used to demonstrate the presence of morbillivirus antigens in formalin-fixed paraffin-embedded sections of brain (Haines and Chelak, 1991). The sections were stained with 1/8,000 and 1/16,000 dilutions of a polyclonal rabbit antiserum to human measles virus. This antiserum previously had been used to detect MV, CDV and PDV by immunohistochemical staining (Haines and Clark, 1991; Haines, unpubl.). Specificity of the procedure was controlled by staining serial sections with similar dilutions of a rabies virus antiserum raised in rabbits. Antiserum specificity for CDV was controlled by absorption of the primary antiserum with CDV vaccine (Vanguard, Norden Laboratories, Calgary, Alberta, Canada) or an irrelevant virus vaccine (Rabguard, Norden Laboratories) (Polak and Van Noorden, 1986). Brain tissue from a ferret with CDV was used as a positive control for the primary antise-

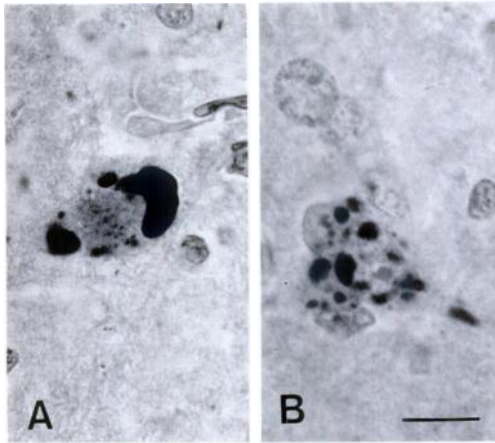


FIGURE 3. Neurons from the cerebral cortex contain a few large (A) or several small (B) densely staining aggregates demonstrating morbillivirus antigen. Avidin-biotin complex immunoperoxidase stain, using an antiserum to human measles virus. Bar = 10 μm .

rum and absorbed sera. Sections of harp seal brain had discrete staining in the cytoplasm and nuclei of neurons that corresponded to inclusions (Fig. 3). No staining occurred with an irrelevant primary antiserum or CDV-absorbed measles antiserum while preabsorption with rabies vaccine had no effect on staining intensity or distribution.

We used a similar ABC technique with monoclonal antibodies to the hemagglutinin protein of PDV (clones 2.55, 2.80 and 2.1) to demonstrate PDV antigen in brain, bladder, lung and gastric mucosa. Tissues from a striped dolphin, *Stenella coeruleoalba*, with known morbillivirus infection (Duignan et al., 1992), a harbor seal with PDV infection (P. J. Duignan and J. R. Geraci, unpubl.), and a virus-free pilot whale, *Globicephala melaena*, were used respectively as positive and negative controls. Specificity of the monoclonal antibodies was controlled by using tissues from a raccoon with CDV infection. Some PDV antigen was detected in the cytoplasm of bronchiolar gland epithelium, gastric crypt epithelium, and transitional epithelium of the bladder (Fig. 4), and associated with intracytoplasmic and intranuclear inclusions in neurons of the cerebrum.

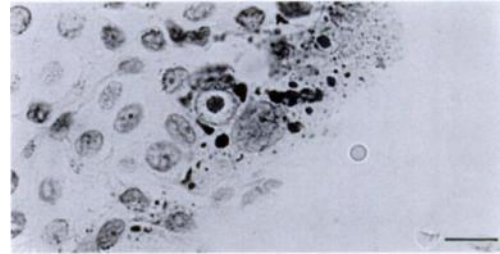


FIGURE 4. Transitional epithelial cells of the urinary bladder contain intracytoplasmic and intranuclear staining aggregates demonstrating morbillivirus antigen. Avidin-biotin complex immunoperoxidase stain, using monoclonal antibodies to the hemagglutinin protein of phocine distemper virus. Bar = 10 μm .

Serum was tested for neutralizing activity (Hsiung, 1982) with CDV Onderstepoort strain, and with a distemper virus isolated from a grey seal in the colony at the University of Guelph (Thorsen, unpubl.). Infectivity titers of CDV and of the grey seal distemper virus were reduced by $10^{4.75}$ and $10^{4.5}$ TCID₅₀, respectively, by harp seal serum diluted 1:10 in phosphate buffered saline (PBS). This was indicative of a strong immune response to CDV or a close antigenic relative. We are attempting to isolate the virus from brain and lung tissue by inoculating cell suspensions onto monolayers of Vero cells, bovine fetal lung cells and canine alveolar macrophages.

This is the first report of clinical PDV infection in a seal from Canadian waters and the first case of PDV disease in a harp seal. Phocine distemper virus infection, without apparent mortality, is now believed to be enzootic in Arctic harp seals with up to 98% of sampled animals seropositive in serum neutralization tests (Dietz et al., 1989; Markussen and Have, 1992). These recent findings have significance for coastal pinnipeds, such as harbor and grey seals, in eastern Canada and New England that may be immunologically naive. Transfer of morbilliviruses from harp seals to other more susceptible species is becoming increasingly plausible now that populations of northern species are expanding, extending southward, and stranding well below their normal range. Recent strand-

ing records show Arctic species such as harp and hooded seals, *Cystophora cristata*, appearing as far south as Florida (Odell, 1991). Furthermore, the New England stranding network has recorded an increase in the number of stranded harp seals since December 1990 that were seropositive for CDV, or a closely related morbillivirus (Greg Early, New England Aquarium, pers. comm.). Most of these strandings occurred between December 1990 and August 1991 which coincides with winter months when harp seal strandings are more frequent and also with the late spring distribution of young-of-the-year.

The epizootiology of morbillivirus infection in pinnipeds of the northwestern Atlantic is undoubtedly complex. We are currently conducting retrospective serological and histopathological studies on stored seal sera and tissues as well as detailed prospective studies on strandings to establish the prevalence, distribution, host range and significance of infection in these species.

We thank the wardens of Prince Edward Island National Park for their excellent cooperation and Dr. P. Hogan for interpretation of radiographs. Dr. B. Ziola, Department of Microbiology, Health Sciences, University of Saskatchewan, kindly supplied measles antiserum, and monoclonal antibodies to PDV were provided by Carol Lyons, Dr. A. Trudgett and Dr. B. K. Rima, Department of Genetic Engineering, The Queen's University of Belfast, N. Ireland.

LITERATURE CITED

- BENGTSON, J. L., P. BOVENG, U. FRANZEN, P. HAVE, M.-P. HEIDE-JØRGENSEN, AND T. L. HÄRKÖNEN. 1991. Antibodies to canine distemper virus in Antarctic seals. *Marine Mammal Science* 7: 85-87.
- CURRAN, M. D., C. O'LOAN, B. K. RIMA, AND S. KENNEDY. 1990. Nucleotide sequence analysis of phocine distemper virus reveals its distinctness from canine distemper virus. *The Veterinary Record* 127: 430-431.
- DIETZ, R., C. T. ANSEN, P. HAVE, AND M.-P. HEIDE-JØRGENSEN. 1989. Clue to seal epizootic? *Nature* 338: 627.
- DUIGNAN, P. J., J. R. GERACI, J. A. RAGA, AND N. CALZADA. 1992. Pathology of morbillivirus infection in striped dolphins (*Stenella coeruleoalba*) from Valencia and Murcia, Spain. *Canadian Journal of Veterinary Research* 56: 242-248.
- HAINES, D. M., AND B. J. CHELACK. 1991. Technical considerations for developing enzyme immunohistochemical staining procedures on formalin-fixed paraffin-embedded tissues for diagnostic pathology. *Journal of Veterinary Diagnostic Investigation* 3: 101-112.
- , AND E. G. CLARK. 1991. Enzyme immunohistochemical staining of formalin-fixed tissues for diagnosis in veterinary pathology. *Canadian Veterinary Journal* 32: 295-302.
- HARWOOD, J., AND B. GRENFELL. 1990. Long term risks of recurrent seal plagues. *Marine Pollution Bulletin* 21: 284-287.
- HSIUNG, G. D. 1982. *Diagnostic virology*, 3rd ed. Yale University Press, New Haven, Connecticut, 276 pp.
- KENNEDY, S. 1990. A review of the 1988 European seal morbillivirus epizootic. *The Veterinary Record* 127: 563-567.
- MARKUSSEN, N. H., AND P. HAVE. 1992. Phocine distemper virus infection in harp seals (*Phoca groenlandica*). *Marine Mammal Science* 8: 19-26.
- ODELL, D. K. 1991. A review of the southeastern United States Marine Mammal Stranding Network 1978-1987. *Marine Mammal Strandings in the United States*, J. E. Reynolds and D. K. Odell (eds.). NOAA Technical Report NMFS 98: 19-24.
- ORVELL, C., AND H. SHESHBERADARAN. 1991. Phocine distemper virus is phylogenetically related to canine distemper virus. *The Veterinary Record* 129: 267-269.
- OSTERHAUS, A. D. M. E., J. GROEN, F. G. C. M. UYTDE-HAAG, I. K. G. VISSER, E. J. VEDDER, J. CROWTHER, AND C. J. BOSTOCK. 1989. Morbillivirus infection in European seals before 1988. *The Veterinary Record* 125: 326.
- POLAK, J. M., AND S. VAN NOORDEN. 1986. *Immunocytochemistry: Modern methods and applications*, 2nd ed. Wright, Bristol, United Kingdom, 736 pp.
- ROSS, P. S., I. K. G. VISSER, H. W. J. BROEDERS, M. W. G. VAN DE BILDT, W. D. BOWEN, AND A. D. M. E. OSTERHAUS. 1992. Antibodies to phocine distemper virus in Canadian seals. *The Veterinary Record* 130: 514-516.
- SEARGANT, D. E. 1976. History and present status of populations of harp and hooded seals. *Biological Conservation* 10: 95-118.

Received for publication 21 May 1992.