



## **Demodicosis in black bears (*Ursus americanus*) from Florida**

Authors: Forrester, Donald J., Spalding, Marilyn G., and Wooding, John B.

Source: Journal of Wildlife Diseases, 29(1) : 136-138

Published By: Wildlife Disease Association

URL: <https://doi.org/10.7589/0090-3558-29.1.136>

---

BioOne Complete ([complete.BioOne.org](https://complete.BioOne.org)) is a full-text database of 200 subscribed and open-access titles in the biological, ecological, and environmental sciences published by nonprofit societies, associations, museums, institutions, and presses.

Your use of this PDF, the BioOne Complete website, and all posted and associated content indicates your acceptance of BioOne's Terms of Use, available at [www.bioone.org/terms-of-use](https://www.bioone.org/terms-of-use).

Usage of BioOne Complete content is strictly limited to personal, educational, and non - commercial use. Commercial inquiries or rights and permissions requests should be directed to the individual publisher as copyright holder.

---

BioOne sees sustainable scholarly publishing as an inherently collaborative enterprise connecting authors, nonprofit publishers, academic institutions, research libraries, and research funders in the common goal of maximizing access to critical research.

## Demodicosis in black bears (*Ursus americanus*) from Florida

Donald J. Forrester,<sup>1</sup> Marilyn G. Spalding,<sup>1</sup> and John B. Wooding,<sup>2</sup> <sup>1</sup>Department of Infectious Diseases, College of Veterinary Medicine, University of Florida, Gainesville, Florida 32610, USA; <sup>2</sup>Florida Game and Fresh Water Fish Commission, Wildlife Research Laboratory, 4005 South Main Street, Gainesville, Florida 32601, USA

**ABSTRACT:** Demodicosis was diagnosed in five black bears (*Ursus americanus*) from north-central Florida. The first bear examined, a 5-yr-old male, had severe alopecia except for the dorsal neck, paws, and ears. The skin was characterized by moderate orthokeratotic hyperkeratosis, and mild to moderate follicular hyperkeratosis. Superficial dermatitis, follicular pustules, and epidermal pustules were present, but rare. Specimens of *Demodex* sp. were seen most commonly within hair follicles devoid of hair and at the infundibulum of sebaceous glands. Four additional bears from the same area also had some degree of alopecia and skin scrapings were positive for *Demodex* sp. This mite may be common, although its prevalence is not known.

**Key words:** Demodicosis, *Demodex* sp., black bear, *Ursus americanus*, Florida, case report.

Since 1976 black bears (*Ursus americanus*) which were killed by vehicles or died of other causes in Florida (USA) have been examined at necropsy to obtain various biological information (Brady and Maehr, 1985; Wooding and Brady, 1987). Ages were determined by the cementum annuli in a premolar tooth (Willey, 1974). Between June 1990 and January 1992 five such bears were found to have varying degrees of hair loss.

The first bear was a 5-yr-old male weighing 95.6 kg from Bradford County in north-central Florida (30°02'N, 82°05'W). The bear was sparsely haired except for normal pelage on the dorsal neck, paws, and ears (Fig. 1). The skin was gray, smooth, and mildly scaly except on the head and forelimbs which were rougher and scallier than elsewhere. Internally there were lesions consistent with blunt trauma, probably due to the bear being struck by a vehicle. Peripheral and intestinal lymph nodes were enlarged, irregular, firm, and contained cortical white nodules up to 5

mm on the cut surfaces. The spleen and liver were irregular and contained nodules up to 3 cm across, some with necrotic and pustular centers. A single such nodule was found in the lung. The liver contained a 6-cm focus of multiple fluid-filled cysts that were up to 1 cm in diameter.

Tissues from skin, liver, spleen, kidney, and lymph nodes were fixed in 10% neutral buffered formalin, sectioned at 6  $\mu$ m thickness, and stained with hematoxylin and eosin. Microscopically, the skin lesions were characterized by moderate orthokeratotic hyperkeratosis, and mild to moderate follicular hyperkeratosis. Most hair follicles were in telogen and catagen phases. Mild acanthosis was present only on the forearms. Infected follicles usually had no inflammatory infiltrate associated with them. Superficial dermatitis and follicular pustules were seen rarely. Mites (*Demodex* sp.) (Fig. 2) were seen within hair follicles (Fig. 3) and at the infundibulum of sebaceous glands in skin from the head, ears, forearms, back, and ventrum. The mites were most numerous on the back, ears, and forearms. More than 20 mites were seen in cross sections of some follicles (Fig. 3). They appeared most commonly in follicles that were devoid of hair and had variable degrees of follicular hyperkeratosis and plugging. Occasionally a mite was seen within the follicular epithelium, and in one case a mite was associated with inflammation at the dermoepidermal junction. Granulomas in the spleen and liver contained centrally located eggs similar to those of the ascaroid nematode *Lagochilascaris sprengi*, a parasite which has been reported previously from black bears in Florida (Conti et al., 1983). The lung lesion was not examined histologically. Biliary

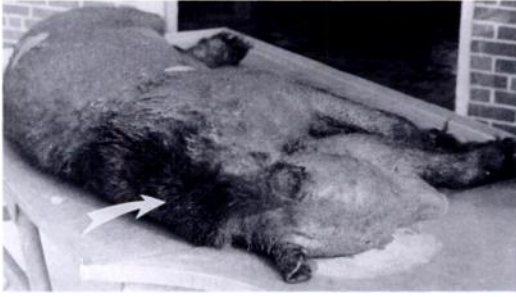

FIGURE 1. Adult male black bear from Florida with severe alopecia. Note normal pelage on neck region (arrow).

cysts were present in the liver at a single focus. There was mild chronic interstitial nephritis. Nodules in the cortex of lymph nodes consisted of focal areas of follicular hyperplasia. Specimens of *Demodex* were not seen in peripheral lymph nodes.

Subsequent to examination of the bear discussed above, specimens of *Demodex* sp. were found in skin scrapings from four other black bears killed by collisions with vehicles in north-central Florida. One was a 7-yr-old, 71.8 kg female from Marion County (29°12'N, 81°55'W) which had extensive areas of hair-loss on her chest, legs, and head. A third bear was a 1-yr-old, 49.1 kg female from Lake County (28°57'N, 81°33'W) which had normal pelage except for mild alopecia on the forearms. Two additional bears from Marion County had mild to moderate hair-loss on the chest and facial areas; one was a 10 to 11-mo-old male weighing 9.5 kg (29°12'N, 81°56'W) and the other was a 4-yr-old female weighing 56.7 kg (29°11'N, 81°53'W).

Three of the above cases of mange were

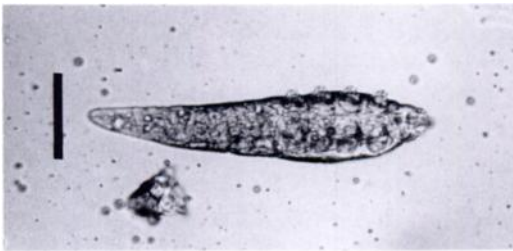

FIGURE 2. Specimen of *Demodex* sp. from skin scraping of a black bear in Florida. Bar = 50  $\mu$ m.

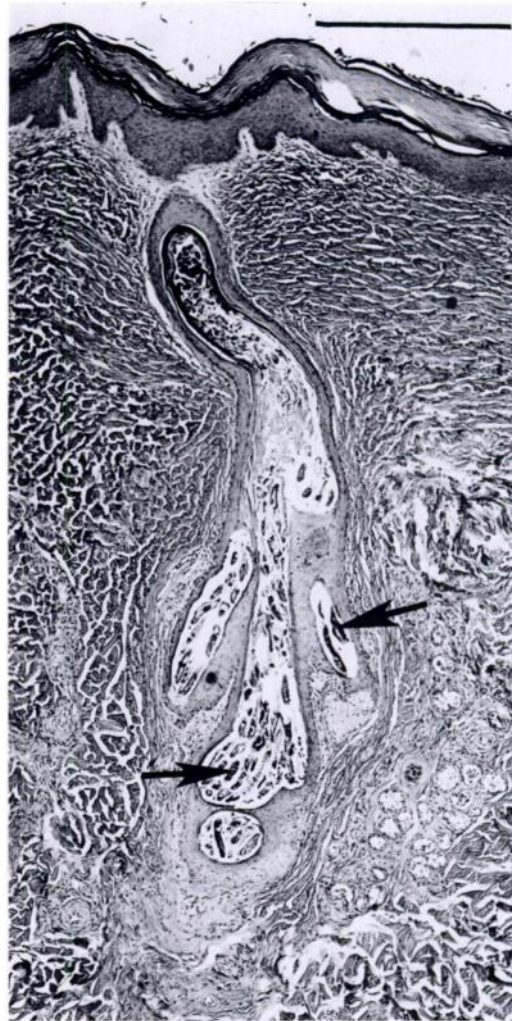


FIGURE 3. Hair follicle of a black bear from Florida containing numerous specimens (arrows) of *Demodex* sp. H&E. Bar = 500  $\mu$ m.

mentioned briefly elsewhere (Forrester, 1992), but no histopathologic details were given. Manville (1978) found two specimens of *Demodex* sp. in one of 113 black bears live-trapped in northern Wisconsin. The bear was partially alopecic and mites were recovered from scab tissue, an observation which differs from our findings. Manville (1978) also observed mange in five other live-trapped bears, but did not show that this condition was related to *Demodex*. The disease in the Florida bears reported herein was not similar to demo-

dicosis in domestic dogs. In the latter host, lesions range from lymphocytic-plasmacytic perifolliculitis to generalized follicular plugging, neutrophilic folliculitis, secondary bacterial infection, and deep pyoderma (Jubb et al., 1985).

The five Florida black bears with *Demodex* infections represent the first cases in which alopecia was noted in 310 carcasses examined from 1976 to 1991. Currently the distribution of black bears in Florida is fragmented because of habitat loss (Brady and Maehr, 1985). Four of the five bears with *Demodex* were from the Ocala bear population, one of the state's four major concentrations of bears. The fifth bear was killed in Bradford County in an area of marginal habitat located approximately midway between the Ocala population and the Osceola population which is located 120 km to the north.

The recent detection of demodicosis in Florida bears and the restricted distribution of individuals with alopecia indicate that additional investigation is needed to determine the distribution, prevalence, and significance of this condition in Florida black bears. In addition, the species of *Demodex* involved should be determined, since it may represent an undescribed species.

Representative specimens of *Demodex* sp. and preserved skin samples from the first bear have been deposited in the U.S. National Parasite Collection, Beltsville, Maryland 20705, USA (Accession No. 82218).

The technical assistance of G. W. Foster, S. R. Telford, Jr., and J. B. Lowe is gratefully acknowledged. We also thank E. M. Addison for his generous assistance with the literature on black bears. This research was supported in part by a contract from the Florida Game and Fresh Water Fish Commission and is a contribution of Federal Aid to Wildlife Restoration, Florida Pittman-Robertson Project W-41. Florida Agricultural Experiment Stations Journal Series No. R-02225.

#### LITERATURE CITED

- BRADY, J. R., AND D. S. MAEHR. 1985. Distribution of black bears in Florida. *Florida Field Naturalist* 13: 1-7.
- CONTI, J. A., D. J. FORRESTER, AND J. R. BRADY. 1983. Helminths of black bears in Florida. *Proceedings of the Helminthological Society of Washington* 50: 252-256.
- FORRESTER, D. J. 1992. Parasites and diseases of wild mammals in Florida. University Press of Florida, Gainesville, Florida, 459 pp.
- JUBB, K. V. F., P. C. KENNEDY, AND N. PALMER. 1985. Pathology of domestic animals, 3rd ed., Vol. 1. Academic Press, Inc., Orlando, Florida, 574 pp.
- MANVILLE, A. M. 1978. Ecto- and endoparasites of the black bear in northern Wisconsin. *Journal of Wildlife Diseases* 14: 97-101.
- WILLEY, C. N. 1974. Aging black bears from first premolar tooth sections. *The Journal of Wildlife Management* 38: 97-100.
- WOODING, J. B., AND J. R. BRADY. 1987. Black bear roadkills in Florida. *Proceedings of the Annual Conference of the Southeastern Association of Fish and Wildlife Agencies* 41: 438-442.

*Received for publication 24 February 1992.*