

Asexually Proliferous Tetrathyridia of Mesocestoides sp. in the Hepatic Portal System of the Prairie Rattlesnake (*Crotalus viridis viridis*)

Authors: Engen, Paul C., and Widmer, Elmer A.

Source: Journal of Wildlife Diseases, 29(1) : 150-152

Published By: Wildlife Disease Association

URL: <https://doi.org/10.7589/0090-3558-29.1.150>

BioOne Complete (complete.BioOne.org) is a full-text database of 200 subscribed and open-access titles in the biological, ecological, and environmental sciences published by nonprofit societies, associations, museums, institutions, and presses.

Your use of this PDF, the BioOne Complete website, and all posted and associated content indicates your acceptance of BioOne's Terms of Use, available at www.bioone.org/terms-of-use.

Usage of BioOne Complete content is strictly limited to personal, educational, and non - commercial use. Commercial inquiries or rights and permissions requests should be directed to the individual publisher as copyright holder.

BioOne sees sustainable scholarly publishing as an inherently collaborative enterprise connecting authors, nonprofit publishers, academic institutions, research libraries, and research funders in the common goal of maximizing access to critical research.

Asexually Proliferous Tetrathyridia of *Mesocestoides* sp. in the Hepatic Portal System of the Prairie Rattlesnake (*Crotalus viridis viridis*)

Paul C. Engen¹ and Elmer A. Widmer,^{2,3} ¹ Department of Anatomy, School of Medicine, Loma Linda University, Loma Linda, California 92350-0002, USA; ² Department of Biology, College of Arts and Sciences, La Sierra University, Riverside, California 92515-8247, USA. ³ Author to whom correspondence and reprint requests should be addressed

ABSTRACT: A female prairie rattlesnake (*Crotalus viridis viridis*) was gastric intubated with 250 tetrathyridia of *Mesocestoides* sp. The snake was killed 12 wk postinfection; a portion of the liver was examined histologically for evidence of tetrathyridia. Five tetrathyridia were seen in two hepatic portal triad vessels. We propose that a blood-borne metastasis of tetrathyridia in reptiles and rodents may occur.

Key words: Prairie rattlesnake, *Crotalus viridis viridis*, *Mesocestoides* sp., tetrathyridium, hepatic portal system, experimental infection.

The invasiveness of the asexually proliferative tetrathyridia of *Mesocestoides* sp. has been experimentally demonstrated in the Great Basin fence lizard (*Sceloporus occidentalis longipes*) by Specht and Voge (1965), and in the prairie rattlesnake (*Crotalus viridis viridis*) by Widmer and Specht (1991). When intraperitoneal inoculation was used in *S. occidentalis longipes*, tetrathyridia penetrated the liver (Specht and Voge, 1965). Gastric intubation of tetrathyridia into *C. viridis viridis* resulted in their migration into the gastrointestinal tract, mesenteries, kidneys, liver and peritoneal cavity; specific migration routes for this distribution have not been determined (Hanson, 1976; Hanson and Widmer, 1985; Widmer and Specht, 1991).

We report evidence that asexually proliferative tetrathyridia (*Mesocestoides* sp.) could invade the hepatic portal system of the prairie rattlesnake (*C. viridis viridis*). If so, this finding would indicate a secondary or perhaps primary migratory route for the distribution of this metacestode to the viscera of certain reptiles.

The female snake used in this experiment was one of 54 prairie rattlesnakes used in a project designed to demonstrate

asexual reproduction of the tetrathyridia of *Mesocestoides* sp. in an experimentally infected ectothermic host (Hanson and Widmer, 1985). Field collection data, methods used for gastric intubation, general maintenance and necropsy procedures were reported by Hanson and Widmer (1985). This snake was one of 18 maintained at 25 C. Twelve wk following gastric intubation the snake was killed and a portion of the liver removed and fixed in Bouin's fixative. The tissue was embedded in *n*-butyl methacrylate and paraffin as described by Engen and Wheeler (1978). The tissue block was serially sectioned through a thickness of about 2.1 mm. Sections were cut at 2 μ m with every fifth section mounted for microscopic examination. Most sections were stained with hematoxylin (H) (Hine, 1981) and triosin (T) (Galigher and Kozloff, 1971). Orcein (Sheehan and Hrapchak, 1980) and 1% fast green FCF functioned as supplemental stains.

Serial sections ($n = 225$) were evaluated to determine the presence and anatomical distribution of tetrathyridia. Two tetrathyridia were seen in one portal triad vein and three in an adjoining branch, near the bifurcation of the large parent vessel. Three of the tetrathyridia had individual invaginated scoleces, one had a binary scolex (both divisions invaginated) and one was acephalic. The tetrathyridium with a binary scolex (Fig. 1) was evidence for the asexual reproductive capability of this metacestode. It was not possible to determine whether this proliferative process occurred prior to or after invasion of the portal system. If the process occurred *in situ*, asexual reproduction in other vessels

of the general circulatory system could be postulated.

Identification of the hepatic portal veins was based on recognition of the portal triads and the histological appearance of the vessel walls. The portal triad sections, containing the tetrathyridia, were surrounded by normal hepatic parenchyma. Hepatocytes located adjacent to the parasites had no evidence of pressure distortion or atrophy.

Based on observation of tetrathyridia in the hepatic portal system, we propose that this vascular route may facilitate their dissemination to the liver, kidneys, and perhaps other viscera. It is not known whether intraperitoneal inoculations would result in infections at the same anatomical sites.

Kagei et al. (1974) reviewed ten human cases diagnosed as harboring adult *Mesocestoides*. He suggested that the practice of eating raw hearts and raw blood of snakes (*Agkistrodon halys* and *Elaphe quadrivirgata*) may have been a possible source of infection for these patients. Our findings further support the feasibility of such a mode of transmission.

Asexually proliferous tetrathyridia have been experimentally transferred to certain rodent hosts. Gastric intubation of laboratory mice (*Mus musculus*) resulted in direct penetration of the tetrathyridia through the wall of the small intestine into the peritoneal cavity and liver (Specht and Voge, 1965; White et al., 1983). Using the same gastric transfer technique on the same host animal, the direct penetration route was implied for infection seen in the lungs of males and females (White et al., 1981), uterine and vaginal walls of infected females (Conn and Etges, 1983), and mammary glands of nonpregnant and pregnant females (Williams and Conn, 1985).

Most experimental studies in mice have involved the intraperitoneal route. This procedure has added the scrotum (Specht and Widmer, 1972), abdominal musculature, epididymis, kidney, and seminiferous tubules to the list of metastatic infection sites (Todd et al., 1978). We are not

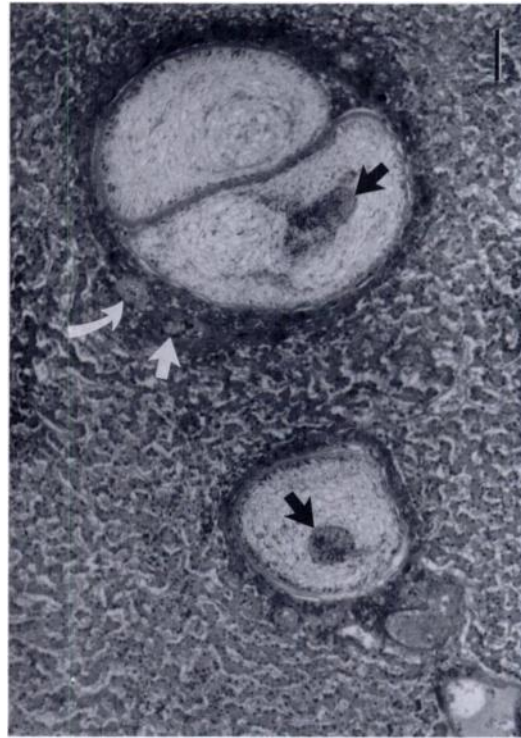


FIGURE 1. Two tetrathyridia of *Mesocestoides* sp. in the lumina of two adjacent portal vessels in the liver of *Crotalus viridis viridis*. The tetrathyridium in the upper vein has a binary scolex. Note suckers (black arrows), hepatic artery (curved white arrow) and bile ductule (straight white arrow). H&T. Bar = 50 μ m.

aware that work with any of the other susceptible animals has extended the list of anatomical sites where asexual reproducing tetrathyridia have been identified (Novak, 1972; Barton et al., 1984).

Based on the invasiveness of this parasite and its broad anatomical distribution in rodent hosts, we believe that invasion of the hepatic portal system may also occur in mammals. Further observations are needed to substantiate or refute this hypothesis.

The authors acknowledge the technical assistance of Burton N. Brin, Wayne Harlow, Thomas E. Smith and Stuart A. Wakefield.

LITERATURE CITED

- BARTON, A. M., E. A. WASHINGTON, A. C. STEWART, AND W. L. NICHOLAS. 1984. *Mesocestoides corti*

- in the rat: Comparisons of *Mesocostoides corti* infections in rats and mice. *International Journal for Parasitology* 14: 391-394.
- CONN, D. B., AND F. J. ETGES. 1983. Maternal transmission of asexually proliferative *Mesocostoides corti* tetrathyridia (Cestoda) in mice. *The Journal of Parasitology* 69: 922-925.
- ENGEN, P. C., AND R. WHEELER. 1978. *N*-butyl methacrylate and paraffin as an embedding medium for light microscopy. *Stain Technology* 53: 17-22.
- GALIGHER, A. E., AND E. N. KOZLOFF. 1971. *Essentials of practical microtechnique*, 2nd ed. Lea and Febiger, Philadelphia, Pennsylvania, 531 pp.
- HANSON, G. B. 1976. Immunological responses in the prairie rattlesnake *Crotalus viridis viridis* Rafinesque 1818, to laboratory infection with tetrathyridia of *Mesocostoides corti* Hoenpli 1925 (Eucestoda: Mesocostoididea). Ph.D. Dissertation. Loma Linda University, Loma Linda, California, 61 pp.
- , AND E. A. WIDMER. 1985. Asexual multiplication of tetrathyridia of *Mesocostoides corti* in *Crotalus viridis viridis*. *Journal of Wildlife Diseases* 21: 20-24.
- HINE, I. F. 1981. Block staining of mammalian tissues with hematoxylin and eosin. *Stain Technology* 56: 119-123.
- KAGEI, N., M. KIHATA, S. SHIMIZU, M. URABE, AND A. ISHII. 1974. The 10th case of human infection with *Mesocostoides lineatus* (Cestoda: Cyclophyllidea) in Japan. *Japanese Journal of Parasitology* 23: 376-382.
- NOVAK, M. 1972. Quantitative studies on the growth and multiplication of tetrathyridia of *Mesocostoides corti* Hoenpli, 1925 (Cestoda: Cyclophyllidea) in rodents. *Canadian Journal of Zoology* 50: 1189-1196.
- SHEEHAN, D. C., AND B. B. HRAPCHAK. 1980. *Theory and practice of histotechnology*, 2nd ed. C. V. Mosby Company, St. Louis, Missouri, 481 pp.
- SPECHT, D., AND M. VOGEL. 1965. Asexual multiplication of *Mesocostoides* tetrathyridia in laboratory animals. *The Journal of Parasitology* 51: 268-272.
- , AND E. A. WIDMER. 1972. Response of mouse liver to infection with tetrathyridia of *Mesocostoides* (Cestoda). *The Journal of Parasitology* 58: 431-437.
- TODD, K. S., JR., J. SIMON, AND J. A. DIPIETRO. 1978. Pathological changes in mice infected with tetrathyridia of *Mesocostoides corti*. *Laboratory Animals* 12: 51-53.
- WHITE, T. R., R. C. A. THOMPSON, D. A. PASS, W. J. PENHALE, AND J. STEPHANSON. 1981. Pathological phenomena associated with *Mesocostoides corti* infection in mice. *Journal of Helminthology* 55: 161-171.
- , ———, AND W. J. PENHALE. 1983. Factors influencing the establishment of *Mesocostoides corti* in mice following oral inoculation of tetrathyridia. *Journal of Helminthology* 57: 197-203.
- WIDMER, E. A., AND H. D. SPECHT. 1991. Asynchronous capsule formation in the gastrointestinal tract of the prairie rattlesnake (*Crotalus viridis viridis*) induced by *Mesocostoides* sp. tetrathyridia. *Journal of Wildlife Diseases* 27: 161-163.
- WILLIAMS, C. A., AND D. B. CONN. 1985. Localization and associated histopathology of asexually proliferative *Mesocostoides corti* tetrathyridia (Cestoda) infecting mouse mammary glands. *International Journal for Parasitology* 15: 245-248.

Received for publication 5 May 1992.