



Severe Moniliformiasis (Acanthocephala: Moniliformidae) in a Gray Squirrel, *Sciurus carolinensis*, from Arkansas, USA

Authors: Singleton, Jeurel, Richardson, Dennis J., and Lockhart, J. Mitchell

Source: Journal of Wildlife Diseases, 29(1) : 165-168

Published By: Wildlife Disease Association

URL: <https://doi.org/10.7589/0090-3558-29.1.165>

BioOne Complete (complete.BioOne.org) is a full-text database of 200 subscribed and open-access titles in the biological, ecological, and environmental sciences published by nonprofit societies, associations, museums, institutions, and presses.

Your use of this PDF, the BioOne Complete website, and all posted and associated content indicates your acceptance of BioOne's Terms of Use, available at www.bioone.org/terms-of-use.

Usage of BioOne Complete content is strictly limited to personal, educational, and non - commercial use. Commercial inquiries or rights and permissions requests should be directed to the individual publisher as copyright holder.

BioOne sees sustainable scholarly publishing as an inherently collaborative enterprise connecting authors, nonprofit publishers, academic institutions, research libraries, and research funders in the common goal of maximizing access to critical research.

Severe Moniliformiasis (Acanthocephala: Moniliformidae) in a Gray Squirrel, *Sciurus carolinensis*, from Arkansas, USA

Jeurel Singleton, Dennis J. Richardson, and J. Mitchell Lockhart, Department of Biological Sciences, University of Arkansas, Fayetteville, Arkansas 72701, USA

ABSTRACT: Three hundred and seventy-five acanthocephalans, *Moniliformis clarki*, were removed from the small and large intestines of a gray squirrel from Arkansas County, Arkansas (USA). This is the first report of *M. clarki* from Arkansas. Enteric lesions, including distension, perforating ulcers, enteritis, crypt hypertrophy, goblet cell hyperplasia, and occlusions of the intestinal tract were observed, indicating the pathogenic potential of this parasite.

Key words: Gray squirrel, *Sciurus carolinensis*, *Moniliformis clarki*, acanthocephala, Arkansas.

The intestines of a hunter-shot male gray squirrel (*Sciurus carolinensis*) from Arkansas County, Arkansas (USA) (34°22'N, 91°32'W) were evaluated for acanthocephala. The squirrel had been killed by a gunshot wound to the head. The general body condition of the squirrel was unknown because only the intestine was submitted. Three hundred and seventy-five acanthocephalans were removed from the lumen of the gut and the container in which the intestinal tract was submitted. The intestinal tract was distended and occluded by acanthocephalans. The small intestine had twenty-five focal ulcerative lesions that measured 5.0 to 10.0 mm in diameter and had perforated the wall of the gut, primarily on its anti-mesenteric aspect. *Moniliformis clarki* parasites in different developmental stages were found protruding through perforating ulcers into the container. The ratio of adult female to male acanthocephalans was 1.4:1. Females averaged 125 mm (range 105 to 195 mm) long and represented 47% ($n = 175$) of the total population of acanthocephalans recovered. The mean length of males was 95 mm (range 60 to 125 mm). The males represented 33% ($n = 124$) of the population. Juveniles averaged 45 mm (range

30 to 75 mm) in length and represented 20% ($n = 75$) of the total acanthocephalan population recovered. No other parasites were found in the intestinal tract. The intestinal chyme contained eggs of *M. clarki*, beetle body fragments, and acorn and bark fragments. No other insect fragments were found. Blood-stained fecal material was evident in the rectum.

Acanthocephalans recovered from the intestinal tract and peritoneal cavity of the squirrel conformed to the description of *Moniliformis clarki* (Ward, 1917; Van Cleave, 1924) given by Van Cleave (1953) and Petrochenko (1958). Representative specimens were deposited in the Harold W. Manter Laboratory, Division of Parasitology, University of Nebraska State Museum, Lincoln, Nebraska: HWML Collection Number 34232.

Sections of the small and large intestines (about 15 × 15 mm) were fixed in 10% neutral buffered formalin, embedded in paraffin, sectioned at 5 to 7 μm and stained with Harris' hematoxylin and eosin (H&E) for light microscope examination. Microscopic examination of intestinal tract sections revealed enteritis, characterized by infiltration of the mucosa and submucosa with lymphocytes, macrophages, giant cells, and scattered eosinophils (Figs. 1–3). Thick-walled ova of the parasite were common in the lumen of the guts and often were surrounded by fibrinopurulent exudate, mononuclear phagocytes, plasma cells and eosinophils (Fig. 1). Multifocal ulcerations and desquamation of the mucosa were extensive in the small and large intestines (Fig. 3). Hypertrophy of crypts and goblet cell hyperplasia were prominent (Figs. 1–3). A number of goblet cells appeared to have released most of their

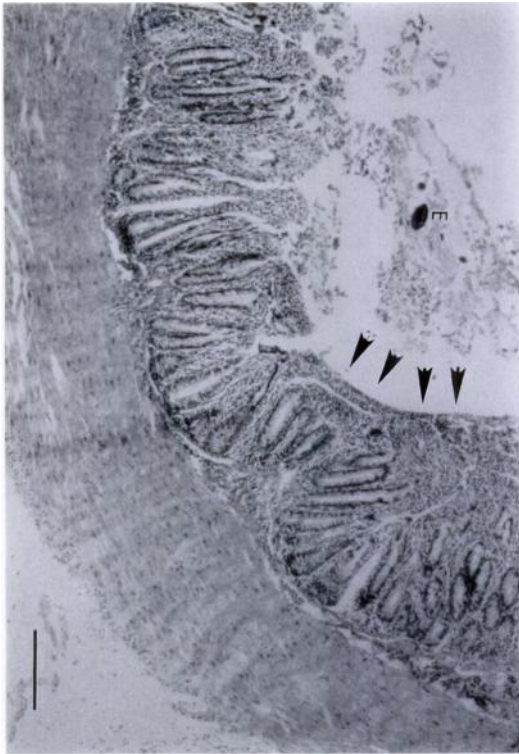


FIGURE 1. A section through *M. clarki*-infected gray squirrel small intestine showing villus atrophy, crypt hypertrophy and infiltration of the lamina propria with inflammatory cells (predominantly eosinophils). A thick-walled ovum (E) in the intestinal lumen is surrounded by fibrinopurulent exudate. An area of epithelial cell compression (arrows) at a point of acanthocephalan attachment. H&E. Bar = 200 μ m.

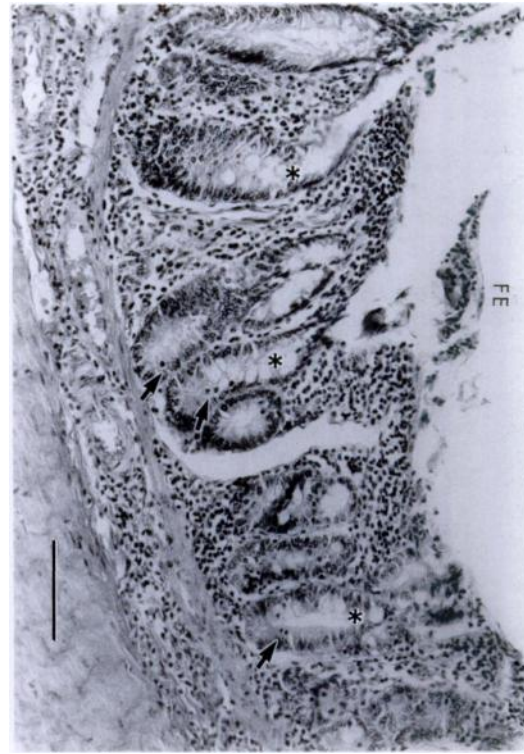

FIGURE 2. A section through the distal small intestine of the *M. clarki*-infected gray squirrel at an area near an acanthocephalan attachment site. There is lymphocyte and neutrophil infiltration in the lamina propria and submucosa, goblet cell hyperplasia, goblet cell exhaustion (asterisks), epithelial cell proliferation (arrows) and apolarization of enterocytes. Eosinophils and neutrophils are noted in the fibrinopurulent exudate (FE) in the gut lumen. H&E. Bar = 50 μ m.

secretion (Fig. 2). Acanthocephalan attachment areas in the small intestine were noted by epithelial cell compression (Fig. 1) and an abundance of eosinophils, neutrophils and giant cells. Epithelial cell abnormalities included elongation, atrophy, nuclear apolarity and disorganization (Figs. 1, 2). Capillaries of the submucosa and tunica muscularis were dilated. Hemorrhagic areas and mild leukocytic infiltration were found near perforating ulcers. Hematomas also were visible on the serosal aspect of the intestinal tract. The gut walls were flaccid and the mucosa and submucosa were atrophied at the intestinal-caecal juncture.

Singhvi and Crompton (1982) reported

an increase in the size and length of the small intestine in laboratory rats experimentally infected with *Moniliformis dubius*. Varute and Patil (1971) noted intestinal lesions in the epithelium, lamina propria, muscularis mucosa and submucosa around *M. dubius* proboscis attachment sites in the intestine. A scanning electron microscope study of the attachment sites of *M. dubius* to the intestinal wall of the rat showed pits around the everted proboscis, craters around the neck, and evidence of host goblet cell exhaustion (Martin et al., 1983). Davidson (1976) reported fatal peritonitis in flying squirrels (*Glau-*

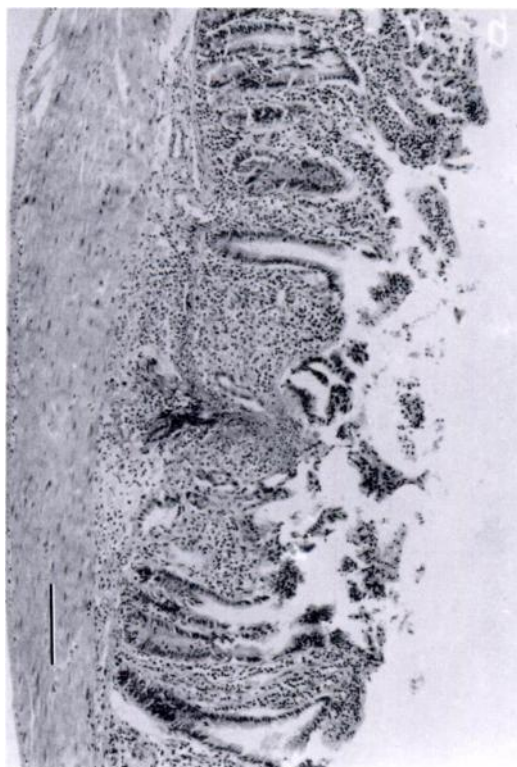


FIGURE 3. A section through an area of the colon in the *M. clarki*-infected gray squirrel. Note central focal area of ulceration and necrosis, accompanied by an intense inflammatory cell infiltration and a patchy loss of crypts. H&E. Bar = 200 μ m.

comys volans) due to a heavy *M. clarki* infection and suggested that, because of its large size, *M. clarki* might occlude the intestinal lumen if present in high numbers. Davidson (1976) did not find lesions attributable to *M. clarki* in infected gray squirrels in the southeastern United States. The pathogenic potential of *M. clarki* has been considered low because of the infrequent and localized occurrence of the parasite (Chandler, 1947; Parker, 1971; Welborn, 1975). Enteric lesions, including enteritis and perforating ulcers associated with infection by *M. clarki* have not been reported in wild gray squirrels prior to this investigation.

Moniliformis clarki has been recorded from a number of species of mammals, mostly rodents, including *Sciurus caroli-*

nensis by Chandler (1921, 1947), Conti et al. (1984), Davidson (1976), Fish (1972), Petrochenko (1958), Pfaffenberger et al. (1985), and Van Cleave (1953). Conti et al. (1984) found a 25% prevalence and a 16% mean intensity of *Moniliformis clarki* in urban gray squirrels in Florida. These previous reports provided no data on pathological manifestations of *Moniliformis clarki* infections. This report documents the first record of *M. clarki* from Arkansas and an extension of the known geographic range of this parasite.

The authors thank Dr. Eugene Schmidt of the Department of Biological Sciences, University of Arkansas, for reviewing and editing the manuscript. We thank Mr. Tim Moser, Waterfowl Research Biologist of the Arkansas Game and Fish Commission for the specimen used in this study. We also thank Dr. Joseph N. Beasley of the Department of Animal and Poultry Sciences, University of Arkansas for his help with the histopathological examination of the intestine.

LITERATURE CITED

- CHANDLER, A. C. 1921. Notes on the occurrence of *Moniliformis* sp. in Texas rats. *The Journal of Parasitology* 7: 179-183.
- . 1947. Notes on *Moniliformis clarki* in North American squirrels. *The Journal of Parasitology* 33: 278-281.
- CONTI, J. A., D. J. FORRESTER, R. K. FROHLICK, G. L. HOFF, AND W. J. BISLER. 1984. Helminths of urban gray squirrels in Florida. *The Journal of Parasitology* 70: 142-144.
- DAVIDSON, W. R. 1976. Endoparasites of selected populations of gray squirrels (*Sciurus carolinensis*) in the southeastern United States. *Proceedings of the Helminthological Society of Washington* 43: 211-217.
- FISH, P. G. 1972. Notes on *Moniliformis clarki* (Ward) (Acanthocephala: Moniliformidae) in west central Indiana. *The Journal of Parasitology* 58: 147.
- MARTIN, J., D. W. T. CROMPTON, AND A. SINGHVI. 1983. Mucosal lesions in the rat associated with the attachment of *Moniliformis* (Acanthocephala). *Journal of Helminthology* 57: 85-90.
- PARKER, J. C. 1971. Protozoans, helminth and arthropod parasites of the gray squirrel in southwestern Virginia. Ph.D. Thesis. Virginia Polytechnic Institute, Blacksburg, Virginia, 262 pp.

- PETROCHENKO, V. I. 1958. Acanthocephala of domestic and wild animals, Vol. 2. Akademii Nauk SSSR, Moscow. (English translation: Israel Program for Scientific Translations, Jerusalem, Israel, 1971.)
- PFÄFFENBERGER, G. S., K. KEMETHER, AND D. DE BRUIN. 1985. Helminths of sympatric population of kangaroo rats (*Dipodomys ordii*) and grasshopper mice (*Onychomys leucogaster*) from the High Plains of Eastern New Mexico. *The Journal of Parasitology* 71: 592-595.
- SINGHVI, A., AND D. W. T. CROMPTON. 1982. Increase in size of the small intestine of rats infected with *Moniliformis* (Acanthocephala). *International Journal of Parasitology* 12: 173-178.
- VAN CLEAVE, H. J. 1924. A critical study of the Acanthocephala described and identified by Joseph Leidy. *Proceedings of the Academy of Natural Sciences of Philadelphia* 76: 279-334.
- . 1953. Acanthocephala of North American mammals. The University of Illinois Press, Urbana, Illinois, 179 pp.
- VARUTE, A. T. AND V. A. PATIL. 1971. Histopathology of the alimentary tract of rats infected with *Moniliformis dubius* (Acanthocephala): Part I. Histological alterations and changes in nuclei and mucopolysaccharide distribution. *Indian Journal of Experimental Biology* 9: 195-199.
- WARD, H. B. 1917. *Echinorhynchus moniliformis* in North America. *The Journal of Parasitology* 3: 182.
- WELBORN, T. C. 1975. Some physiological parameters and gastrointestinal helminths of the gray squirrel (*Sciurus carolinensis*) in Tennessee. M.S. Thesis. University of Tennessee, Knoxville, Tennessee, 84 pp.

Received for publication 25 June 1991.