

LIZARD ERYTHROCYTIC VIRUS IN EAST AFRICAN CHAMELEONS

Authors: Telford, Sam R., and Jacobson, Elliott R.

Source: Journal of Wildlife Diseases, 29(1) : 57-63

Published By: Wildlife Disease Association

URL: <https://doi.org/10.7589/0090-3558-29.1.57>

The BioOne Digital Library (<https://bioone.org/>) provides worldwide distribution for more than 580 journals and eBooks from BioOne's community of over 150 nonprofit societies, research institutions, and university presses in the biological, ecological, and environmental sciences. The BioOne Digital Library encompasses the flagship aggregation BioOne Complete (<https://bioone.org/subscribe>), the BioOne Complete Archive (<https://bioone.org/archive>), and the BioOne eBooks program offerings ESA eBook Collection (<https://bioone.org/esa-ebooks>) and CSIRO Publishing BioSelect Collection (<https://bioone.org/csiro-ebooks>).

Your use of this PDF, the BioOne Digital Library, and all posted and associated content indicates your acceptance of BioOne's Terms of Use, available at www.bioone.org/terms-of-use.

Usage of BioOne Digital Library content is strictly limited to personal, educational, and non-commercial use. Commercial inquiries or rights and permissions requests should be directed to the individual publisher as copyright holder.

BioOne is an innovative nonprofit that sees sustainable scholarly publishing as an inherently collaborative enterprise connecting authors, nonprofit publishers, academic institutions, research libraries, and research funders in the common goal of maximizing access to critical research.

LIZARD ERYTHROCYTIC VIRUS IN EAST AFRICAN CHAMELEONS

Sam R. Telford, Jr.¹ and Elliott R. Jacobson²

¹ Florida Museum of Natural History, University of Florida, Gainesville, Florida 32611, USA

² Department of Small Animal Clinical Sciences, College of Veterinary Medicine, Box J-126, Health Sciences Center, University of Florida, Gainesville, Florida 32610, USA

ABSTRACT: Giemsa-stained peripheral blood films from 9 of 50 flap-necked chameleons, *Chamaeleo dilepis*, and 1 of 18 Fischer's chameleons, *Bradypodion fischeri*, collected in Tanzania had intraerythrocytic inclusions. In *C. dilepis*, acidophilic inclusions were associated with the albuminoid vacuoles reported in typical pirhemocytonosis of saurians. Under transmission electron microscopy, the acidophilic inclusions were aggregations of partially or completely formed viral particles consistent with those of the family Iridoviridae. Enveloped viral particles were 140 to 180 nm in diameter, with a mean of 159 nm (SD, 12). Albuminoid vacuoles were not seen in the *B. fischeri* infection, in which erythrocytes contained multiple acidophilic inclusions of variable shape. Viral particles in *B. fischeri* were 156.3 to 200.0 nm in diameter; the mean was 180 nm (SD, 18). This represents the first confirmation of the viral identity of pirhemocyton in a lizard. We recommend that the epithet pirhemocyton no longer be used as a generic name under the International Code of Zoological Nomenclature, and that future reports of the etiologic agent refer to it as Lizard Erythrocytic Virus.

Key words: *Chamaeleo dilepis*, *Bradypodion fischeri*, Tanzania, ultrastructure, Iridoviridae, pirhemocytonosis, Lizard Erythrocytic Virus.

INTRODUCTION

Pirhemocytonosis has been reported in lizards many times since the description of *Pirhemocyton tarentolae* by Chatton and Blanc (1914). There also are reports from snakes and turtles (Johnston, 1975; Telford, 1984). Over ten "species" have been described from Europe, Africa, and Brazil, often only on the basis of finding the infection in a different host species (Rousselot, 1953). Typically, the infection is seen in Giemsa-stained erythrocytes as single, reddish inclusions that enlarge as the infection progresses, often accompanied by an unstained albuminoid vacuole (body), or "globoid" (Chatton and Blanc, 1914; Brumpt and Lavier, 1935). The increase in diameter of the acidophilic inclusions as an infection progresses indicates that small, uniformly sized inclusions are characteristic of early infection. As an infection develops, host cell nuclei may become karyorrhectic, followed by karyolysis and cytolysis.

For many years, *Pirhemocyton* was considered to be a piroplasm, despite the lack of valid evidence to support this classification. Subsequently, Blanc and Ascione (1958) suggested that it might be a virus.

Although Brygoo (1963) was able to transmit *Pirhemocyton* to chameleons by intraperitoneal inoculation of infected blood, he was unable to infect them with a filtrate following lysis of infected blood with distilled water, and therefore concluded that a viral nature was unlikely. Stehbens and Johnston (1966), however, by ultrastructural study, established the identity of a *Pirhemocyton* from Australian geckoes as a DNA-type, icosahedral virus, similar to Sericesthis and Tipula iridescent viruses. The visible "parasite" in the host cell represented the "assembly pool" of the virus infection. Similar appearing intraerythrocytic inclusions have been seen in the anurans *Rana catesbeiana*, *R. septentrionalis*, and *R. clamitans*, and by electron microscopy; particles consistent with those of members of the family Iridoviridae have been described as Frog Erythrocytic Virus (FEV) (Gruia-Gray et al., 1989). Despite the clear identification of *Pirhemocyton* as a virus, Arcay de Peraza and de la Roca (1971) considered their *Pirhemocyton iguanae* to be a protozoan similar to piroplasms on the basis of cytochemistry. As recently as two years ago, still another "species" of *Pirhemocyton* was described

by light microscopy (Mutinga and Dipeolu, 1989), with the authors classifying it as a protistan parasite.

Here we present ultrastructural findings from infections in chameleon hosts as the first confirmation of the viral identity of *Pirhemocytos*, established by Stehbens and Johnston (1966). We recommend a more appropriate designation for the etiologic agent of pirhemocytosis, and report an unusual manifestation of the infection in one of the host species.

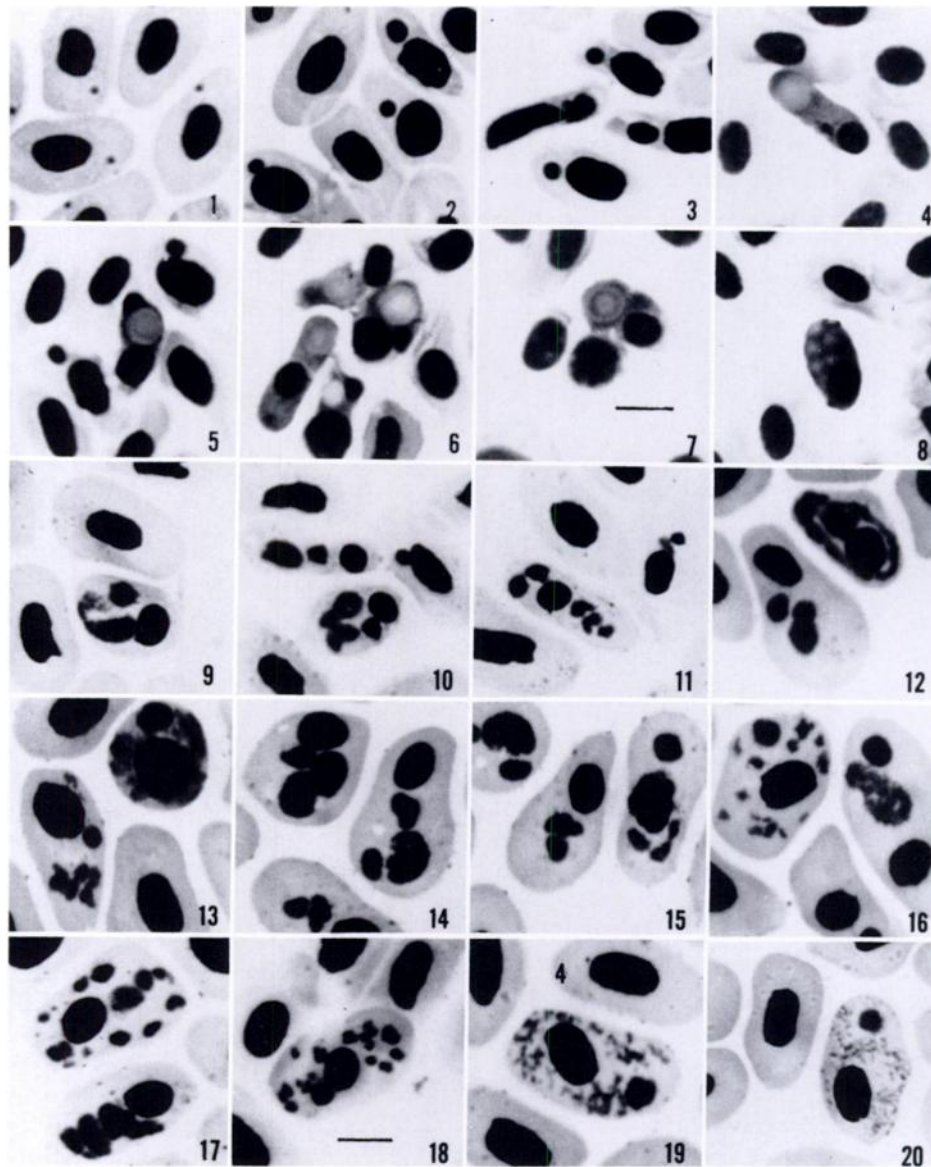
MATERIALS AND METHODS

Chameleons collected in Tanzania from 1981 to 1985 by the senior author were bled from clipped toe nails; thin blood films were prepared and stained for 1 hr by the Giemsa method at a dilution of 1:10 in distilled water buffered to pH 7.0 (Telford, 1988). Some chameleons were examined at irregular intervals over periods of several months, but the data presented were obtained from the initial slide, except in the case of one lizard that showed an apparently fully developed infection. Several drops of blood from one flap-necked chameleon, *Chamaeleo dilepis*, collected in the vicinity of Morogoro (6°51'S, 37°38'E), and one Fischer's chameleon, *Bradypodion fischeri*, collected in the Western Usambara Mountains (4°49'S, 38°31'E), were expressed from toes directly into 1 ml of a phosphate buffered 4% formalin-1% glutaraldehyde mixture (McDowell and Trump, 1976), and were later prepared for transmission electron microscopy (TEM) by the procedures of Hyatt (1986). Additional *B. fischeri* were collected in the Eastern Usambara Mountains (5°5'S, 38°38'E). Viremias were estimated from counts of at least 300 erythrocytes, and the diameters of inclusions visible under light microscopy were measured by calibrated ocular micrometer.

RESULTS

Nine of 50 flap-necked chameleons from the vicinity of Morogoro had intracytoplasmic punctate to ovoid inclusions within their erythrocytes. In two chameleons with high viremias (86 to 89%), most erythrocytes contained small acidophilic inclusions measuring 0.5 to 1.5 μm (Fig. 1). Two inclusions were present in 5% of the infected cells. Host cell nuclei appeared normal, showing neither pyknosis nor karyorrhexis. Both erythrocytes and poly-

chromatophilic proerythrocytes were infected, but no infections were seen in basophilic proerythrocytes or erythroblasts. Inclusions in two other chameleons were similar in size to the heavy infections, but their viremias were far lower (8 to 12%). In three chameleons with viremias of 6 to 13%, very small, red intracytoplasmic inclusions also were observed, but the usual size was 2 to 3 μm (Figs. 2, 3). Associated with these larger inclusions usually were albuminoid vacuoles (bodies) (Figs. 4, 5). These were absent in those infections where the acidophilic inclusions did not exceed 2.0 μm in diameter, but when present occurred in 11 to 41% of the infected erythrocytes. The albuminoid vacuoles often were similar in staining characteristics to the erythrocyte cytoplasm, but were surrounded by a narrow, clear margin. Some albuminoid vacuoles reached the large size of 4 to 6 μm (Figs. 6, 7, 8). While most vacuoles were an opaque, gray-green color, some had a clear margin and a purplish edge surrounding a purple-green center (Fig. 7). Several of the larger albuminoid vacuoles were associated with one or two small acidophilic bodies, and the cytoplasm of one erythrocyte was nearly filled with six similar but smaller albuminoid vacuoles (Fig. 8). In a second blood film taken 12 days following the initial slide from this chameleon with an apparently fully developed infection, 18% of the infected cells contained prominent albuminoid vacuoles, but had no trace of the red-stained area. Many erythrocytes had pyknotic nuclei. The infections in two chameleons were at very low viremias ($\leq 1\%$), and the number of infected cells containing the albuminoid vacuoles had decreased to 7% in one host, and to zero in the other. However, some of the acidophilic inclusions in the host that still had albuminoid vacuoles remained near maximum size, while 18% of the infected cells had vacuoles but had no visible virions. The acidophilic inclusions in the host without any albuminoid vacuoles were smaller, uniform in size, stained less in-



FIGURES 1–20. Erythrocytes of two chameleon species infected with Lizard Erythrocytic Virus. Giemsa. Bar = 10 μ m. Fig. 1: Early infection in *Chamaeleo dilepis* no. 2, with 86% viremia. Figs. 2 to 5: Infection in *C. dilepis* no. 5, with 13% viremia. Figs. 6 to 8: Infection in *C. dilepis* no. 7, with 9% viremia. Note multiple albuminoid bodies in erythrocyte of Fig. 8. Figs. 9 to 20: Infection in *Bradypodion fischeri*. Figs. 9 to 18 at initial examination, with 17% viremia; Figs. 19 and 20 with 1% viremia, 16 days later.

tensely than in infections at higher viremia, and often were barely visible. No erythrocytes with karyorrhectic nuclei were observed, although nuclei often were displaced and pycnotic.

In one of three Fischer's chameleons obtained on 21 March 1984 in the Western

Usambara Mountains, 17% of the erythrocytes contained multiple irregular inclusions (Figs. 9 to 18) which stained similarly to inclusions of *C. dilepis*. Fifteen *B. fischeri* from the Eastern Usambara Mountains were negative for intraerythrocytic inclusions. In infected red blood cells of

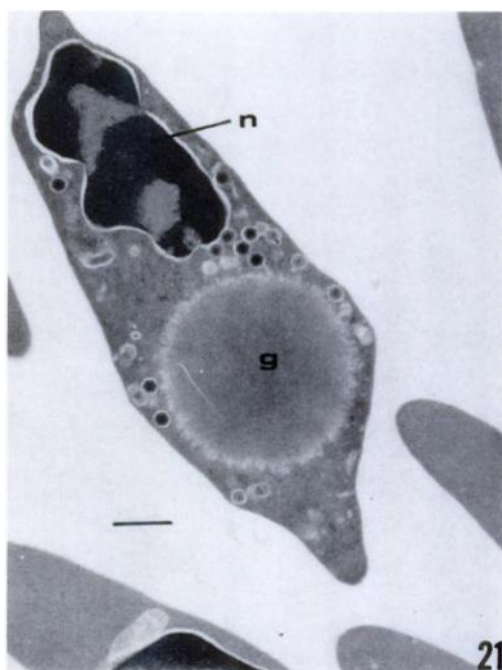


FIGURE 21. Transmission electron micrograph of infected erythrocyte of *C. dilepis* no. 5. The host cell nucleus (n) and an albuminoid vacuole (g) can be seen. Bar = 650 nm.

the Fischer's chameleon, no albuminoid vacuoles were seen. In the first blood sample examined, 80% of the infected erythrocytes contained two to 30 acidophilic inclusions, 2 to 7 μm , in diameter; 94% of the infected cells had multiple inclusions on each of the two subsequent slides from the same animal. Inclusions usually were larger when only two or three were present (Figs. 10, 12, 15), than when there were ≥ 6 inclusions (Figs. 11, 17, 18), and sometimes were larger than the erythrocyte nucleus (Figs. 9, 14, 16). Although both immature (Fig. 13) and mature erythrocytes were infected, most infected cells were mature. In the groups of acidophilic inclusions, one inclusion often stained more intensely than the others, and had either a dark dot in the center of the inclusion, or two to three refractile, dark dots along the periphery. Viremia declined on subsequent blood films to 5% on 30 March, to 1% on 7 April, and to $<0.01\%$ on 15 April,

the last day on which infected cells could be found. On the final positive slide, the larger inclusions were less intensely stained with a less compact form, and some clearly were fading away, resembling an aggregation of red or pink strands in the erythrocyte cytoplasm (Figs. 19, 20). Infected erythrocyte nuclei were pycnotic, but none were karyorrhectic.

By electron microscopy, the area of the red blood cells of *C. dilepis* that stained deep red with Giemsa contained viral particles in varying degrees of assembly (Figs. 21, 22). Most viral particles had icosahedral outlines, a trilaminar structure, an electron dense core, an envelope, and measured 140 to 180 nm, with a mean of 159.1 nm (SD, 12). The envelope consisted of two electron dense layers separated by a layer of less electron dense material (Fig. 22). Viral particles either were distributed in loose groupings within the cytoplasm of the host cell (Fig. 21), or were concentrated in single masses adjacent to a virus assembly pool containing partially assembled virus particles (Fig. 22). While there was a single such aggregation of viral particles in the flap-necked chameleon, multiple aggregations of tightly packed particles were present in the Fischer's chameleon (Fig. 23), which corresponded to the multiple areas of red-staining material seen under light microscopy (Figs. 9 to 18). Assembled viral particles in the erythrocytes of *B. fischeri* ranged from 156 to 200 nm, and had a mean of 180 nm (SD, 18); these particles were larger than those present in *C. dilepis*. The albuminoid vacuole, present in some of the infected cells in *C. dilepis* (Fig. 21) contained a fine granular material of moderate electron density; the margins were not sharply defined. Similar structures were not observed in infected red blood cells of the Fischer's chameleon.

DISCUSSION

Inclusions within red blood cells in *C. dilepis* were typical of piroplasmidosis.

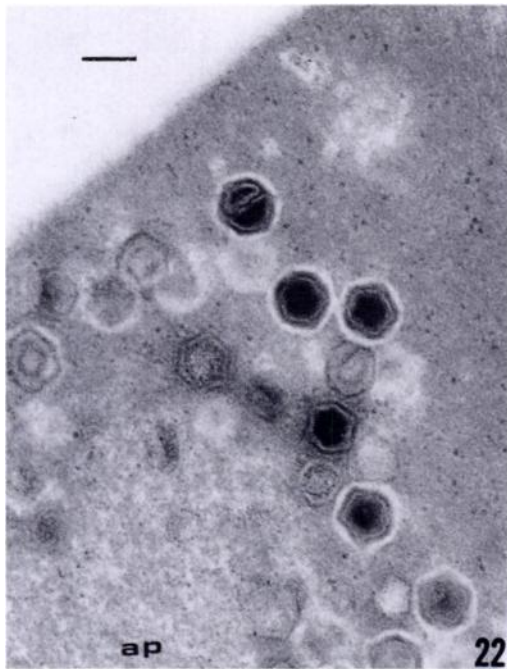


FIGURE 22. Transmission electron micrograph of infected erythrocyte of *C. dilepis* no. 5. Enveloped particles are present adjacent to an assembly pool (ap) containing developing virus. Bar = 160 nm.

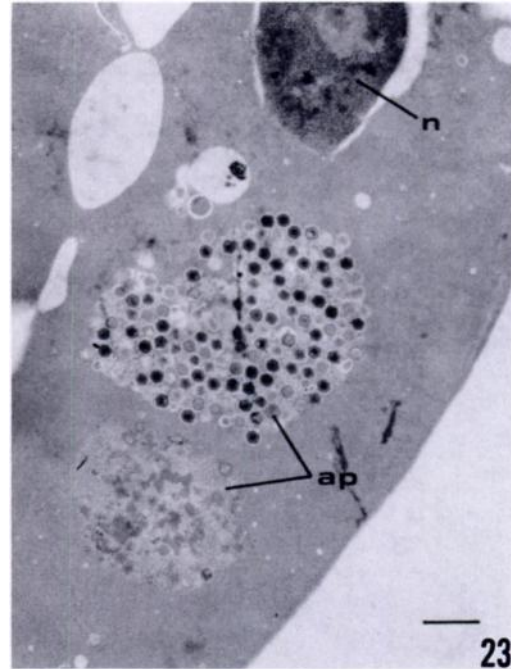


FIGURE 23. Transmission electron micrograph of an infected erythrocyte of *B. fischeri*. Two assembly pools (ap) and the host cell nucleus (n) are visible within the cell. Bar = 700 nm.

in other reptile hosts; they rarely had more than a single, circular acidophilic area in the host cell, and corresponded closely to those identified in Madagascan chameleons by Brygoo (1963) as "*Pirhemocytion chamaeleonis*." Particularly noteworthy in his report and in the material studied here (Figs. 4, 6) were the spindle-shaped or elongated, narrow erythrocytes that appeared at the peak of infection. In two *C. dilepis* examined, these unique erythrocytes disappeared before the terminal phase of the infection. In the infected *B. fischeri*, red blood cells contained multiple, highly irregular inclusions and were distinct from anything described in the literature of lower vertebrate parasitology. Some bodies within infected erythrocytes could have been confused with haemsporidian or haemogregarine parasites.

There was little apparent difference in the ultrastructure of the viral inclusions in both chameleon species reported here,

from those described by Stehbens and Johnston (1966) in Australian geckoes, nor from the Frog Erythrocytic Virus (FEV) studied by Gruia-Gray et al. (1989). The latter authors, however, reported the presence of a membrane-bound, elongate body in the cytoplasm of host cells infected by FEV, and concentric lamellar membranes surrounding some single virions. These have not been seen in saurian infections. Stehbens and Johnston (1966) reported two types of albuminoid vacuoles under electron microscopy. One had indefinite margins and contained a small amount of granular material with very light density. The other, with more distinct margins, contained a homogeneous material of moderate electron density. Gruia-Gray et al. (1989) reported the presence of albuminoid vacuoles in erythrocytes infected by FEV, but did not mention their ultrastructural appearance. The albuminoid vacuoles in the red blood cells of infected *C.*

dilepis were similar to the second type described by Stehbens and Johnston (1966) in Australian geckoes; they were filled with a homogeneous, finely granular material of moderate electron density, but their margins were not precisely defined. These vacuoles were not evident under light or electron microscopy in the infection of *B. fischeri*. Using TEM, one ultrastructural difference between the two infections was the presence of multiple foci of viroplasm in *B. fischeri*, and single foci in infected cells of *C. dilepis*. These represent the multiple and single acidophilic inclusions visible under light microscopy in the two species. Based on the difference in mean diameter of the viral particles in *C. dilepis* (159 nm) and those in *B. fischeri* (179 nm), we believe that either two distinct viruses were present, or a single viral strain had a different size in different hosts. Viral particles in both chameleon species were smaller than those described by Stehbens and Johnston (1966) for geckoes in Australia.

Our observations were consistent with those used by Stehbens and Johnston (1966) to establish the viral nature of *Pirhemocyton*. Based upon size, location, and morphogenesis, these viruses are consistent with members of the family Iridoviridae. Because of the viral nature of this disease, we recommend that the epithet *Pirhemocyton* no longer be used. The name *Pirhemocyton* has no validity under the International Code of Zoological Nomenclature, and should not appear italicized in the manner of valid taxonomic designations. We recommend, therefore, that henceforth reports and discussions of this characteristic viral parasite of saurians refer to it as Lizard Erythrocytic Virus (LEV), the etiologic agent of pirhemocytonosis.

Unlike the pox virus-chlamydial infections of monocytes in *C. dilepis* (Jacobson and Telford, 1990), no mortality could be attributed to infection by LEV in the Tanzanian chameleons. Brygoo (1963) experimentally infected three chameleon species (*C. verrucosus*, *C. oustaleti*, and *C.*

lateralis) by inoculation of 0.25 ml of infected blood or a broth comprised of mosquitoes fed upon infected lizards 6 days earlier. Death occurred in 16 days. Brygoo (1963) believed, however, that natural infections were less likely to be fatal because viremias were consistently low (10 to 20%). The prevalence of natural infections by LEV in *C. lateralis* was 14% ($n = 250$), but prevalence was far lower in *C. oustaleti* (2%, $n = 104$) and *C. pardalis* (1%, $n = 57$) (Brygoo, 1963). In Tanzania, 9 of 50 *C. dilepis* (18%) were infected with the typical form of LEV. Only 1 (6%) of 18 *B. fischeri* was infected with the LEV that produced multiple foci of viroplasm in erythrocytes.

Despite the similarity under light microscopy to infection caused by LEV, Daly et al. (1980) found intraerythrocytic basophilic inclusions associated with albuminoid bodies in water snakes to resemble oncornaviruses in their ultrastructure, rather than iridoviruses. Future studies on the supposed cases of pirhemocytonosis in snakes and turtles will require ultrastructural data to demonstrate their viral nature, and then molecular biological analysis to prove affinity with, or their distinction from LEV.

ACKNOWLEDGMENTS

Published as Florida Experiment Station Journal Series No. R-02036.

LITERATURE CITED

- ARCAY DE PERAZA, L., AND C. D.-M. DE LA ROCA. 1971. The "paranuclear corpuscles" in poikilothermic vertebrates: Description of a new species of *Pirhemocyton* in *Iguana iguana* of Venezuela, with remarks on the nature of these organisms and their relation to allied parasites. *Memorias do Instituto Oswaldo Cruz* 69: 57-69.
- BLANC, G., AND L. ASCIONE. 1958. Sur un parasite endoglobulaire du lézard *Eremias guttulatus olivieri* Audoin de la région de Marrakech (Maroc). *Bulletin de la Société Pathologie Exotique* 51: 508-511.
- BRUMPT, E., AND G. LAVIER. 1935. Sur un hématozoaire nouveau du lézard vert, *Pirhemocyton lacertae* n. sp. *Annales de Parasitologie Humaine et Comparée* 13: 537-543.

- BRYGOO, E. R. 1963. Contribution a la connaissance de la parasitologie des cameleons malgaches. II. Annales de Parasitologie Humaine et Comparée 38: 525-739.
- CHATTON, E., AND G. BLANC. 1914. Sur un hématozoaire nouveau, *Pirhemocyton tarentolae*, du gecko *Tarentola mauritanica*, et sur les altérations globulaires qu'il détermine. Comptes Rendu de la Societe Biologie 77: 496-498.
- DALY, J. J., M. MAYHUE, J. H. MENNA, AND C. H. CALHOUN. 1980. Viruslike particles associated with *Pirhemocyton* inclusion bodies in the erythrocytes of a water snake, *Nerodia erythrogaster flavigaster*. The Journal of Parasitology 66: 82-87.
- GRUIA-GRAY, J., M. PETRIC, AND S. DESSER. 1989. Ultrastructural, biochemical and biophysical properties of an erythrocytic virus of frogs from Ontario, Canada. Journal of Wildlife Diseases 25: 497-506.
- HYATT, M. A. 1986. Basic techniques for transmission electron microscopy. Academic Press, New York, New York, 411 pp.
- JACOBSON, E. R., AND S. R. TELFORD. 1990. Chlamydial and poxvirus infections of circulating monocytes of a flap-necked chameleon (*Chamaeleo dilepis*). Journal of Wildlife Diseases 26: 572-577.
- JOHNSTON, M. R. L. 1975. Distribution of *Pirhemocyton* Chatton & Blanc and other, possibly related, infections of poikilotherms. Journal of Protozoology 22: 529-535.
- MCDOWELL, E. M., AND B. F. TRUMP. 1976. Historical fixative suitable for diagnostic light and electron microscopy. Archives of Pathology and Laboratory Medicine 100: 405-414.
- MUTINGA, M. J., AND O. O. DIPEOLU. 1989. Saurian malaria in Kenya: description of new species of hameoproteid and haemogregarine parasites, Anaplasma-like and Pirhemocyton-like organisms in the blood of lizards in West Pokot District. Insect Science and Its Application 10: 401-412.
- ROUSSELOT, R. 1953. Notes de parasitologie tropicale. I. Parasites du sang des animaux. Vigot, Paris, France, 152 pp.
- STEBBENS, W. E., AND M. R. L. JOHNSTON. 1966. The viral nature of *Pirhemocyton tarentolae*. Journal of Ultrastructural Research 15: 543-554.
- TELFORD, S. R., JR. 1984. Haemoparasites of reptiles. In Diseases of amphibians and reptiles, G. L. Hoff, F. L. Frye, and E. R. Jacobson (eds.). Plenum Publishing Corporation, New York, New York, pp. 385-517.
- . 1988. Studies on African saurian malarias: Five *Plasmodium* species from chameleons of the Uzungwe Mountains, Tanzania. International Journal for Parasitology 18: 197-219.

Received for publication 23 January 1992.