

Prevalence of Encephalitozoon cuniculi Antibodies in Terrestrial Mammals in Iceland, 1986 to 1989

Authors: Hersteinsson, P., Gunnarsson, E., Hjartardóttir, S., and Skímisson, K.

Source: Journal of Wildlife Diseases, 29(2) : 341-344

Published By: Wildlife Disease Association

URL: <https://doi.org/10.7589/0090-3558-29.2.341>

BioOne Complete (complete.BioOne.org) is a full-text database of 200 subscribed and open-access titles in the biological, ecological, and environmental sciences published by nonprofit societies, associations, museums, institutions, and presses.

Your use of this PDF, the BioOne Complete website, and all posted and associated content indicates your acceptance of BioOne's Terms of Use, available at www.bioone.org/terms-of-use.

Usage of BioOne Complete content is strictly limited to personal, educational, and non - commercial use. Commercial inquiries or rights and permissions requests should be directed to the individual publisher as copyright holder.

BioOne sees sustainable scholarly publishing as an inherently collaborative enterprise connecting authors, nonprofit publishers, academic institutions, research libraries, and research funders in the common goal of maximizing access to critical research.

Prevalence of *Encephalitozoon cuniculi* Antibodies in Terrestrial Mammals in Iceland, 1986 to 1989

P. Hersteinsson,¹ E. Gunnarsson,² S. Hjartardóttir,² and K. Skírnisson,² ¹The Wildlife Management Institute, Hlemmi 3, P.O. Box 5032, IS-125 Reykjavík, Iceland; ²Institute for Experimental Pathology, P.O. Box 8540, IS-128 Reykjavík, Iceland

ABSTRACT: Antibodies to *Encephalitozoon cuniculi* were found in wild arctic foxes (*Alopex lagopus*), feral mink (*Mustela vison*), wood mice (*Apodemus sylvaticus*) and house mice (*Mus musculus*) in Iceland. Animals with antibodies were found throughout the country. No lesions attributable to encephalitozoonosis were found in adult animals necropsied. However, one arctic fox cub with a neurological disorder had pathological and serological evidence of encephalitozoonosis.

Key words: *Encephalitozoon cuniculi*, arctic fox, *Alopex lagopus*, feral mink, *Mustela vison*, *Apodemus*, *Mus*, population dynamics.

Encephalitozoonosis is an infectious disease caused by *Encephalitozoon (Nosema) cuniculi* (Microsporidia, Protozoa) (Lainson et al., 1964; Weiser, 1964; Mohn, 1983). Its geographic distribution is widespread and *E. cuniculi* has been found in a large number of laboratory and domestic mammals (Wilson, 1979).

Furthermore, *E. cuniculi* has been confirmed in some carnivores bred for their fur, such as American mink (*Mustela vison*) (Nordstoga and Loftsgaard, 1986) and arctic foxes (*Alopex lagopus*) (Vávra and Blazek, 1971; Nordstoga, 1972) and various wild mammals in captivity, including African hunting dogs (*Lycaon pictus*) (van Heerden et al., 1989).

Encephalitozoonosis causes high mortality of arctic fox pups on fox farms, whereas adults have no clinical signs (Nordstoga et al., 1974; Mohn, 1983; Henriksen, 1985). Mortality is rare or absent in mink with serologic evidence of exposure (Nordstoga and Loftsgaard, 1986). Infection may cause eye cataracts in mink (Bjerkås, 1989).

In fur farms the most important routes of transmission are believed to be via food contaminated by rodents, from mother to offspring in utero and possibly by milk,

and from male to female during copulation (Kangas, 1982; Mohn et al., 1982). The urine of infected foxes contains a large number of the parasites and spores (Nordstoga et al., 1974).

Encephalitozoonosis was diagnosed once on a fox farm in Iceland, but the route of transmission was not determined (Gunnarsson, unpubl.). In addition, encephalitozoonosis was diagnosed among arctic foxes taken as pups from the wild to an experimental fur-farm in Iceland (Gunnarsson et al., 1987).

The prevalence of encephalitozoonosis among free-ranging carnivores has not received much attention. The objective of our study was to determine the serological prevalence of *E. cuniculi* among arctic foxes, American mink, wood mice (*Apodemus sylvaticus*) and house mice (*Mus musculus*) in Iceland.

Carcasses of 372 adult arctic foxes, 311 mink and 244 mice from throughout Iceland were submitted by hunters and farmers to the authors in all seasons, 1986 to 1989. The first 50 mice received were not identified to species.

Animals killed near Reykjavík (64°10'N, 21°50'W) usually were received fresh. Carcasses from more distant regions were frozen within 2 to 3 days of death.

Upon arrival, carcasses were stored at -20 C. After several days to 6 mo, carcasses were thawed for necropsy and removal of blood samples.

One live arctic fox pup with stunted growth and signs of a neurological disorder was examined together with one litter-mate and the carcass of their father. The affected pup died <48 hr after arrival. Following gross examination, a cross section of the heart was fixed in neutral buffered 10% formalin. Paraffin sections were

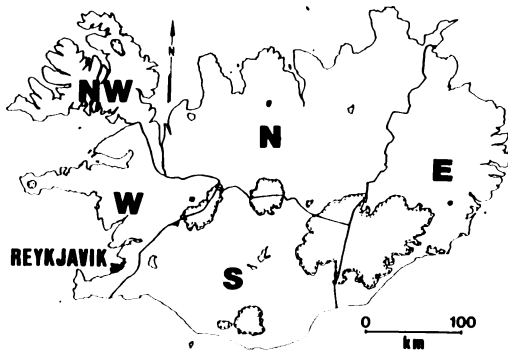


FIGURE 1. Five geographic areas of Iceland from which wild mammals were collected to determine antibody prevalence of *Encephalitozoon cuniculi*, 1986 to 1989. W, West; NW, Northwest; N, North; E, East; S, South.

stained with hematoxylin-eosin and Van Gieson's stain (Drury and Wallington, 1967).

The heart and kidneys from all other fox carcasses, but not mink and mouse carcasses, were examined grossly for encephalitozoonosis lesions.

Blood was removed by glass capillary tubes via incision of the heart. Serum from all carcasses was tested for the presence of antibodies against *E. cuniculi* with the carbon immunoassay (CIA) test (Waller and Bergquist, 1982) using the direct modification of the test (Pakes and Lai, 1985) as recommended by the manufacturer of the antigen (Testman, Uppsala, Sweden); a titer of 1:20 was considered positive.

Since 1958, hunters have been em-

ployed to search all known arctic foxes breeding dens in Iceland annually for signs of occupancy and to kill the inhabitants. Similar rules with regard to mink are in force but are not as strictly followed. The Wildlife Management Unit has collected information on arctic fox and mink hunts in Iceland, for five major areas of the country (Fig. 1). Host population trends and serum antibody prevalence of *E. cuniculi* were compared for the five areas. A chi-square test of independence (Sokal and Rohlf, 1969) was used to test whether prevalences of *E. cuniculi* antibodies differed among hosts between these five areas in Iceland.

Antibodies to *E. cuniculi* were found in all species examined (Table 1). No significant difference in prevalence was found between the species of mice. Mice were then combined for comparison with arctic foxes and mink. Antibody prevalence did not differ significantly between foxes, mink and mice.

Antibody prevalence varied significantly between areas in Iceland for foxes ($P < 0.0001$) and for mink ($P < 0.05$), but not for mice. Prevalence was highest in mink samples from northwestern and eastern Iceland and in arctic foxes from northern and eastern Iceland.

On gross examination of the adult foxes with serologic evidence of exposure to *E. cuniculi*, we found no significant lesions.

The arctic fox pup with the neurological disorder at the time of capture died <48

TABLE 1. Area-specific serum antibody prevalence of *Encephalitozoon cuniculi* in mammals from Iceland, 1986 to 1989.

Area	<i>Alopex lagopus</i>	<i>Mustela vison</i>	<i>Apodemus sylvaticus</i>	<i>Mus musculus</i>	Unspecified mice*
West	2/105 (2) ^b	6/66 (9)	0/27 (0)	0/8 (0)	ND ^c
Northwest	6/80 (8)	3/23 (13)	0/23 (0)	ND	ND
North	16/59 (27)	5/105 (5)	2/34 (6)	ND	0/1 (0)
East	13/50 (26)	11/67 (16)	4/41 (10)	1/4 (25)	5/49 (10)
South	4/78 (5)	1/50 (2)	0/22 (0)	3/35 (9)	ND
Total	41/372 (12)	26/311 (8)	6/147 (4)	4/47 (9)	5/50 (10)

* No differentiation was made between *A. sylvaticus* and *M. musculus* early in the study.

^b Number positive/number tested (percent positive).

^c ND, no data.

hr after arrival. The animal had a severe inflammation of the kidneys, with white nodules lining the coronary grooves, and edema of the cortical membranes. There was a nodular eccentric inflammation in the coronary arteries. The inflammation was restricted primarily to the adventia but sometimes extended into the muscular layer with destruction of the vessel wall and a thrombotic occlusion of the lumen. In some lesions, fresh necrosis with acute inflammatory reaction was noted; but in general the inflammation was more chronic with fibrosis. The changes are consistent with periarteritis or polyarteritis nodosa, and are diagnostic for encephalitozoonosis (Nordstoga and Westbye, 1976). Serum from this animal had an antibody titer of 1:40 but was not diluted further.

The litter-mate, which appeared healthy, survived and had no symptoms of encephalitozoonosis. The litter-mate and their father had serologic titers against *E. cuniculi* of 1:5,400 and 1:40, respectively.

Serologic evidence of exposure to *E. cuniculi* occurred in all areas and in all three species examined. We conclude that the parasite is widespread in Iceland.

Encephalitozoonosis is known to decrease the survival of arctic fox pups in captivity (Kangas, 1982). We found evidence that it could cause mortality in one pup in the wild as well. Adults have no clinical signs, but pregnant vixens may reabsorb litters or abort (Kangas, 1982). Affected adult arctic foxes never have been observed in the wild. However, this does not preclude the parasite's potential as a factor in the demography of arctic foxes in certain areas or at certain times.

Since the hunting effort is very stable from year to year, trends in hunting kill serve as an index to arctic fox population trends (Hersteinsson et al., 1989; Hersteinsson, 1992). In western Iceland, where antibody prevalence in foxes was only 2%, fox kill had increased six-fold in the last 10 to 15 yr, indicating a sharp rise in population size (Fig. 2). No clear population trend was observed in northern and east-

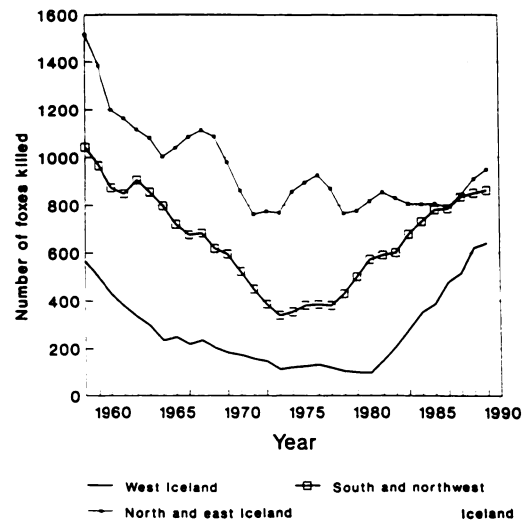


FIGURE 2. Three-year running means of the annual hunter take of arctic foxes during 1958 to 1989 in Iceland.

ern Iceland where the antibody prevalence was over 25%. In the south and northwest, where fox catches doubled from the mid-1970's to the late 1980's, antibody prevalences were 5 and 8%, respectively, during 1986 to 1989 (Fig. 2).

Although the causes of the observed long-term fluctuations in arctic fox population size are unknown, it is possible that encephalitozoonosis contributed to the initial decline in population size by depressing fetal and pup survival. This may explain why there has been an increase in population size only in those parts of Iceland where the rate of exposure of foxes to *E. cuniculi* was low in the late 1980's.

Although we did not compare mink kill and prevalence of antibody in mink, there was no evidence that *E. cuniculi* affected the population dynamics or geographic distribution of mink. Observed effects of the parasite on mink in fur-farms are relatively minor.

Both mink and arctic foxes feed on *Apo-demus sylvaticus* in Iceland (Skirnisson, 1980; Hersteinsson, 1984). Arctic foxes also occasionally kill mink (Hersteinsson, unpubl.). We propose that mice are a potential reservoir for *E. cuniculi* from which

both foxes and mink can be reinfected if the parasite goes extinct in the carnivore population.

This study was financed in part by grants from the Icelandic Council of Science and the National Research Council of Iceland. We are grateful to the many hunters and farmers in Iceland who supplied carcasses for the study.

LITERATURE CITED

- BJERKÅS, I. 1989. Some protozoan infections in carnivores. Neuropathology and host-parasite relationships. Dr. Med. Vet. Thesis. Norwegian College of Veterinary Medicine, Oslo, Norway, 92 pp.
- DRURY, R. A. B., AND E. A. WALLINGTON (editors). 1967. Carleton's histological technique, 4th ed. Oxford University Press, Oxford, England, 432 pp.
- GUNNARSSON, E., P. HERSTEINSSON, S. ADALSTEINSSON, AND S. HJARTARDOTTIR. 1987. A serological survey of nosematosis among Icelandic arctic foxes (*Alopex lagopus*). *Scientifur* 10: 297-298.
- HENRIKSEN, P. 1985. Nosematose hos farmræve. *Dansk Veterinær Tidsskrift* 68: 371-373.
- HERSTEINSSON, P. 1984. The behavioural ecology of the arctic fox (*Alopex lagopus*) in Iceland. D. Phil. Thesis. University of Oxford, Oxford, England, 286 pp.
- . 1992. Demography of the arctic fox (*Alopex lagopus*) population in Iceland. In *Wildlife 2001: Populations*, D. R. McCullough and R. H. Barrett (eds.). Elsevier, London, England, pp. 954-964.
- , A. ANGERBJÖRN, K. FRAFJORD, AND A. KAIKUSALO. 1989. The arctic fox in Fennoscandia: Management problems. *Biological Conservation* 49: 67-81.
- KANGAS, J. 1982. Sjukdomar hos räv och mårddhund. *Finlands Pälsdursuppfödarens Förbund*, Helsinki, Finland, 91 pp.
- LAINSON, R., P. C. C. GARNHAM, R. KILLICK-KENDRICK, AND R. G. BIRD. 1964. Nosematosis, a microsporidian infection of rodents and other animals, including man. *British Medical Journal* 2: 470-472.
- MOHN, S. F. 1983. Encephalitozoonosis in the blue fox (*Alopex lagopus*). Dissertation. National Veterinary Institute, Oslo, Norway, 107 pp.
- , K. NORDSTOGA, AND O. M. MØLLER. 1982. Experimental encephalitozoonosis in the blue fox. Transplacental transmission of the parasite. *Acta Veterinaria Scandinavica* 24: 99-108.
- NORDSTOGA, K. 1972. Nosematosis in blue foxes. *Nordisk Veterinær Medicin* 24: 21-24.
- , AND G. LOFTSGAARD. 1986. Nosematosis (encephalitozoonosis) in mink. Preliminary epidemiological and pathological investigations. *Scientifur* 10: 79.
- , S. F. MOHN, AND G. LOFTSGAARD. 1974. Nosematosis hos blaarev. Proceedings of the Nordic Veterinary Congress 12: 183-186.
- , AND K. WESTBYE. 1976. Polyarteritis nodosa associated with nosematosis in blue foxes. *Acta Pathologica Microbiologica et Immunologica Scandinavica Section A* 84: 291-296.
- PAKES, S., AND W. C. LAI. 1985. Carbon immunoassay—A simple and rapid serodiagnostic test for feline toxoplasmosis. *Laboratory Animal Science* 35: 370-372.
- SKIRNISSON, K. 1980. Food habits of mink (*Mustela vison* Schreber) at River Sog, South Iceland (in Icelandic with English summary). *Náttúrufræðingurinn* 50: 46-56.
- SOKAL, R. R., AND F. J. ROHLF. 1969. *Biometry*. W. H. Freeman and Company, San Francisco, California, 776 pp.
- VAN HEERDEN, J., N. BAINBRIDGE, R. E. J. BURROGHS, AND N. P. J. KRIEK. 1989. Distemper-like disease and encephalitozoonosis in Wild dogs (*Lycacoon pictus*). *Journal of Wildlife Diseases* 25: 70-75.
- VÁVRA, J., AND K. BLAZEK. 1971. Nosematosis in carnivores. *The Journal of Parasitology* 58: 923-924.
- WALLER, T., AND N. R. BERGQUIST. 1982. Rapid simultaneous diagnosis of toxoplasmosis and encephalitozoonosis in rabbits by carbon immunoassay. *Laboratory Animal Science* 32: 515-517.
- WEISER, J. 1964. On the taxonomic position of the genus *Encephalitozoon* Levaditi, Nicolau and Schoen, 1923 (Protozoa: Microsporidia). *Parasitology* 54: 749-751.
- WILSON, J. M. 1979. The biology of *Encephalitozoon cuniculi*. *Medical Biology* 57: 84-101.

Received for publication 28 October 1991.