

EXPERIMENTAL INFECTION OF DOMESTIC DUCKS AND RODENTS BY NOTOCOTYLUS ATTENUATUS (TREMATODA: NOTOCOTYLIDAE)

Authors: Graczyk, Thaddeus K., and Shiff, Clive J.

Source: Journal of Wildlife Diseases, 29(3) : 434-439

Published By: Wildlife Disease Association

URL: <https://doi.org/10.7589/0090-3558-29.3.434>

The BioOne Digital Library (<https://bioone.org/>) provides worldwide distribution for more than 580 journals and eBooks from BioOne's community of over 150 nonprofit societies, research institutions, and university presses in the biological, ecological, and environmental sciences. The BioOne Digital Library encompasses the flagship aggregation BioOne Complete (<https://bioone.org/subscribe>), the BioOne Complete Archive (<https://bioone.org/archive>), and the BioOne eBooks program offerings ESA eBook Collection (<https://bioone.org/esa-ebooks>) and CSIRO Publishing BioSelect Collection (<https://bioone.org/csiro-ebooks>).

Your use of this PDF, the BioOne Digital Library, and all posted and associated content indicates your acceptance of BioOne's Terms of Use, available at www.bioone.org/terms-of-use.

Usage of BioOne Digital Library content is strictly limited to personal, educational, and non-commercial use. Commercial inquiries or rights and permissions requests should be directed to the individual publisher as copyright holder.

BioOne is an innovative nonprofit that sees sustainable scholarly publishing as an inherently collaborative enterprise connecting authors, nonprofit publishers, academic institutions, research libraries, and research funders in the common goal of maximizing access to critical research.

EXPERIMENTAL INFECTION OF DOMESTIC DUCKS AND RODENTS BY *NOTOCOTYLUS ATTENUATUS* (TREMATODA: NOTOCOTYLIDAE)

Thaddeus K. Graczyk and Clive J. Shiff

The Johns Hopkins University School of Hygiene and Public Health, Department of Immunology and Infectious Diseases, 615 North Wolfe Street, Baltimore, Maryland 21205, USA

ABSTRACT: In order to study transmission patterns of *Notocotylus attenuatus* five 3-wk-old domestic ducks, five 8-wk-old rats and ten 4-wk-old mice were infected with the parasite. All ducks became infected and all flukes were recovered from the intestinal ceca. Worms moved down the length of the cecum during development and as the parasites grew they changed their method of attachment. Flukes became gravid by day 16 post-infection, after which growth ceased. Egg filaments appear to play a role in the formation and movement of worm egg clusters from the distal portion of the cecum to the lumen of small intestine. Rodents also became infected with the parasite producing granulomatous nodular lesions in the lower small intestine but all flukes in the granulomata were dead. It is unlikely that transmission of this trematode can depend on mice and rats.

Key words: *Notocotylus attenuatus*, experimental infection, Peking ducks, transmission.

INTRODUCTION

As migratory routes for wildfowl become restricted, the role of refuges in sustaining these flight paths and the birds which use them assume significant roles in sustaining this important component of global avifauna. Similarly, concentrations of these migrants in the refuges improve opportunities for interaction between potential hosts and numerous parasitic species. The potential for severe epizootics of parasite modulated disease is increasing and it is important to understand the hazards to bird migrants which may be developing.

Notocotylus attenuatus is a trematode inhabiting the intestinal ceca of birds, causing pathology, severe disease and death of waterfowl and domestic fowl (Lapage, 1961; Persson et al., 1974). Transmission of *N. attenuatus* is efficient because the parasite does not require a second intermediate host, and the metacercariae remain viable for up to 3 mo (Graczyk and Shiff, 1993). Severe infections of domestic fowl may occur in the areas where they feed in close proximity to waterfowl.

The Wildfowl Trust of North America maintains a bird sanctuary with several ponds near Grasonville, eastern Maryland (USA) called Horsehead Sanctuary (38°58'N, 76°12'E). These ponds are located in the

established migratory pathways of waterfowl. We have found ≤ 35 cysts/cm² of metacercarial cysts of *N. attenuatus* there. Our objective was to determine the pattern of development of the trematode in domestic ducks and to assess its possibility of transmission by rats and mice.

MATERIALS AND METHODS

Physa acuta (Gastropoda: Pulmonata) were collected in Duckhead Pond at Horsehead Sanctuary. Infected snails were placed in aquaria with small pieces of polyethylene sheeting to provide a convenient surface for encystment of emerging cercariae (Fried, 1970). Cysts were scraped off the polyethylene within 7 days post-encystment and treated in 3% NaHCO₃ for 15 min (Fried, 1970). Two hundred cysts were fed to each of five 3-wk-old domestic ducklings (Peking strain), similarly 200 cysts per animal also were administered per os to five 8-wk-old rats (Sprague Dawley strain), and 100 cysts per animal were fed to ten 4-wk-old mice (CD-1, Charles River strain). One animal of each species was not infected and was used as the control.

Ducks and rodents were examined daily for changes in behavior and/or physical appearance. Feces were examined daily from day 10 post-infection (PI) for the presence of parasite eggs using wet smear and Sheather's sugar flotation method (Ash and Orihel, 1987). Eggs were counted under a dissecting microscope (25×) and an estimate was made of ova per gram of feces. Animals (one per each time period) were anesthetized lightly with ether and killed by cervical dislocation at 3, 9, 16, 24, 35 days PI. At necropsy, in situ, the cecum was ligated by

surgeon's silk thread into three segments: anterior, median and posterior with respect to the cecal-intestinal junction. The first ligature was made where the muscular layer of the cecum became thin; the remainder of the cecum then was ligated again at the middle of its remaining length. The intestinal tract was rapidly removed and outlined on tracing paper to determine the external dimensions of the ceca. Each cecum was weighed and opened longitudinally in 0.85% saline (40 C) and worm recovery per segment was noted. The contents of the cecum and large intestine were examined for the presence of parasite eggs in the same manner as the feces.

Five resident mallard ducks (*Anas platyrhynchos*) from Duckhead Pond were examined for the presence of adult *N. attenuatus* in the ceca. The birds were euthanized by cervical dislocation after being anesthetized with ether; the intestinal tissue was partitioned in the same manner as experimentally infected ducks.

Worms which were recovered were placed for 30 min in 4 ml of 0.85% saline with a drop of saturated menthol solution added for relaxation (Malek, 1951). Worms then were transferred to a glass slide and a coverslip rimmed with vaseline (Fried and Rosa-Brunet, 1991) was placed gently on the flukes prior to fixation. Flukes were fixed in hot (80 C) alcohol-formalin-acetic acid, stained in aceto-carmin, dehydrated in a graded alcohol series, cleared in toluene, and mounted in Permount (Ash and Orihel, 1987). Measurements of body lengths and maximum widths were made on fixed specimens with a calibrated ocular micrometer. A chi-square test and *t*-test (Sokal and Rohlf, 1981) were used for group comparisons. Differences were considered significant if $P \leq 0.05$.

Identification of fixed specimens was based on descriptions by Skrjabin (1964), Dawes (1968) and McDonald (1981). Voucher specimens were deposited in the U.S. National Parasite Collection, Beltsville, Maryland, voucher No. 82601.

RESULTS

All experimental ducks became infected. All flukes recovered were from the intestinal ceca. Parasite intensity ranged from 43 to 60 per bird with a mean (\pm SE) of 52 (\pm 3.2) worms. Intensity of infection was not significantly different between animals by a chi-square test. Similarly, the differences in worm recovery between left and right cecum as well as between total number of worms recovered from left and right ceca were not statistically significant by a chi-square test, $P \geq 0.01$ (Table 1).

TABLE 1. Infectivity and growth of *Notocotylus attenuatus* in experimentally infected Peking ducks.

Days post-infection	Numbers of worms recovered			Body length of worms* (mm)	Midacetabular width of worms* (mm)
	Left cecum	Right cecum	Recovery %		
3	24	29	27	1.15 (0.06)	0.21 (0.02)
9	24	19	22	3.67 (0.18)	0.93 (0.05)
16	26	31	29	5.25 (0.28)	1.15 (0.07)
24	33	27	30	4.92 (0.31)	1.34 (0.06)
35	21	26	24	4.89 (0.24)	1.47 (0.08)

* Based on 30 randomly selected specimens.

Ducks exhibited no sign of overt disease. No changes in feather coat were observed. However, changes in fecal composition were observed. Fecal consistency initially was soft and changed to diarrhea over the course of the infection. There was no obvious relationship between fecal consistency and level of trematode egg production. At necropsy on days 3 and 9 PI internal organs appeared normal; however, on days 16, 24, and 35 PI, ballooning of the ceca occurred and a reduction in the length of the anterior part of this organ was observed. The muscular layer was flabby which increased the space of the cecal lumen, particularly of the anterior portion.

Juvenile (3-day-old) and young (9-day-old) worms were found in close association with the cecal villi in the anterior ceca. At day 3 PI, seven viable metacercariae with fragments of the rest of external cyst walls were found in the anterior portions of the ceca. From day 16 PI, worms were found only in the lumen of the posterior ceca and there was no evidence of attachment to the mucosa. Flukes were found singly. Cecal lengths ranged from 161 to 245 mm and weights from 18 to 21 g. There were no significant ($P > 0.05$) differences in total cecal lengths or in total cecal weights among individual birds by a *t*-test. However, differences in left and right cecal lengths and left and right cecal weights were significant ($P < 0.05$) between animals by a *t*-test.

Notocotylus attenuatus flukes become

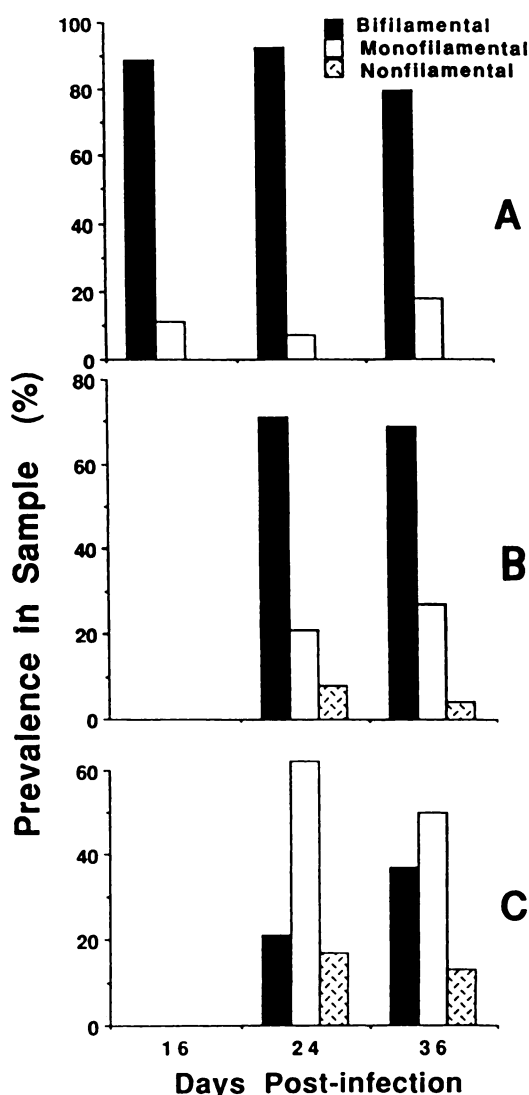


FIGURE 1. Types of *Notocotylus attenuatus* eggs recovered by wet smear method from the ceca (A), intestines (B), and from the feces (C) of experimentally infected Peking ducks. Each value represents the mean of three replicates with 300 ± 25 eggs per replicate.

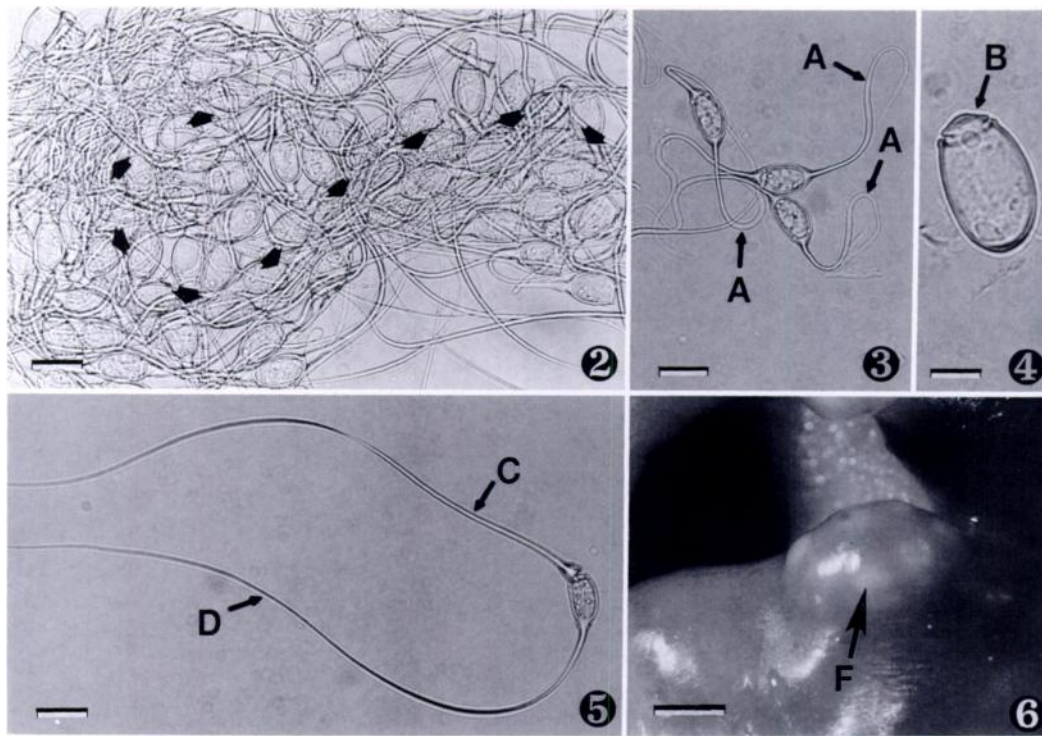
gravid by day 16 PI, and growth stopped after attaining sexual maturity (Table 1). The first eggs were detected in contents of the posterior cecum at day 16 PI (Fig. 1). At days 24 and 36 PI, egg clusters were found in the median and posterior cecum but were not detected in the anterior cecum. Egg clusters detected in the cecum

maintained the shape of the worm uterus (Fig. 2). Eggs in the intestine and in feces, detected at days 24 and 35 PI, were represented also by monofilament and non-filament types (Figs. 3, 4); however, most eggs in the ceca were bifilamental (Fig. 5). Most of the fecal eggs at days 24 and 35 PI had only one filament (Fig. 1).

Approximately 125 *N. attenuatus* eggs per gram of feces (range 111 to 136) were present in three replicate 1 g fecal samples at day 24 PI, and 139 eggs (120 to 158) were present at day 36 PI. Eggs removed from the worm uterus had curved filaments (Fig. 3) which aggregated all the eggs together from the beginning of uterus to the genital pore. Filaments became straight after egg expulsion, but remained matted (Fig. 2).

In the infected rodents all mice and rats had granulomatous nodular lesions on the small intestine (Table 2, Fig. 6). Granulomata containing *N. attenuatus* were found between 48 and 67 cm posterior to the stomach in the rats, and between 15 and 22 cm in mice. The total length of the intestine ranged from 26 to 31 cm in mice ($\bar{x} = 28.3$ cm, SE = 4.5), and in rats, 89 to 96 cm ($\bar{x} = 92.2$ cm, SE = 1.3). Granulomata were not observed in the cecum. The granulomata were globular in shape and their size corresponded to the size of the excysted metacercariae. All trematodes inside the lesions were dead. The lamina propria adjacent to the nodules was infiltrated by plasma cells, lymphocytes and heterophils. Degeneration of the tunica muscularis with heterophil infiltration was observed. The inner portion of the granuloma was formed from the tunica muscularis of the small intestines in direct contact with the parasites. Intestinal villi of the lesion were wider and shorter than villi in uninfected areas.

All five resident 2-yr-old mallard ducks from Duckhead Pond were negative for *N. attenuatus* and other cecal trematodes. The appearance, size and weight of the ceca did not indicate previous monostomiasis or amphistomiasis.



FIGURES 2–6. Photomicrographs of *Notocotylus attenuatus* eggs and a granulomatous nodular lesion produced by *N. attenuatus* in the small intestine of experimentally infected rats. Figure 2. Egg cluster recovered from the distal aspect of a duck cecum; note shape of egg cluster (arrows) remaining from the looped uterus of the fluke. Figure 3. Eggs removed from the proximal part of the fluke uterus; A, small filaments with sticky, curved ends. Figure 4. Nonfilamental egg recovered from the duck feces; B, operculum. Figure 5. Bifilamental egg recovered from the small intestine of a duck; C, opercular filament, D, unopercular filament; note the opercular filament coming off the egg shell. Figure 6. Granulomatous nodular lesion containing *N. attenuatus* in the small intestine of a rat; F, individual worm in granuloma. Scale bar = 25 μ m in Figures 2, 3, 5; 10 μ m in Figure 4; and 1,500 μ m in Figure 6.

DISCUSSION

The process of invasion of the intestinal tract by *N. attenuatus* has not been described. Radlett (1979) suggested that metacercariae excyst in the lower intestine and the larvae actively migrate to the ceca; however, no explanation or description of this movement was given. Such migration, however, would be extremely difficult considering intestinal peristalsis and the lack of adhesive organs on the larva. Furthermore, the only previous record of the site-seeking behavior of a notocotylid fluke, *Catantropis johnsoni*, by Martin (1956) does not give details. Based on the fact that we observed seven viable metacercarial cysts with intact external cyst walls which were

in the proximal cecum at day 3 PI, we conclude that excystation may occur in the lower intestine. Additionally, the random distribution of worms between left and right cecum which we observed indicates that the larvae very likely enter the ceca with intestinal contents by peristalsis. A similar distribution was found by Fried and Nelson (1978) in domestic chicks infected with the cecal fluke *Zygocotyle lunata*.

Within the cecum we found that *N. attenuatus* worms move distally during development. Furthermore it appears that the close association of worms with cecal villi described by Fried and Gainsburg (1980) occurs only with juvenile and young

TABLE 2. The occurrence of granulomatous nodular lesions containing *Notocotylus attenuatus* in the small intestine of experimentally infected rodents.

Rodents	Number of granulomas per rodent		Distance of granulomas from stomach (%)		Size of granulomas (mm)		Number of worms in granulomas Range
	Mean	Range	Mean	Range	Mean	Range	
Mice (n = 10)	14	13-21	64	52-75	2.7	2.1-3.2	3-8
Rats (n = 5)	21	16-25	61	53-71	4.4	3.4-5.2	6-13

parasites which were in the proximal part of the cecum where such villi exist and the expulsive forces are strong. The villi may protect the parasites from expulsion by movement of the cecal contents. Radlett (1980) concluded that adult flukes in the cecum use their ventral papillae as holdfast organs, freeing the oral sucker for feeding. Contrary to this observation we always found adult flukes in the lumen of the distal ceca feeding on cecal debris.

Movements of the eggs probably were influenced by the long filamental processes characteristic of the species. We propose that the curved filaments cause adherence and formation of egg clusters (Fig. 2) which then are more subject to cecal expulsive forces than single eggs. Thus filaments may not only enhance the infection of snails (Erkina, 1954; Dawes, 1968; Wright, 1971; Schell, 1985), but also may facilitate movement of eggs through the cecum and intestine.

Infection with *N. attenuatus* did not produce changes in the mass and size of duck ceca such as found by Fried and Nelson (1978) in cecal amphistomiasis caused by *Zygocotyle lunata*. However, the flaccidity of the muscular layer of the proximal part of the cecum as well as ballooning of the whole organ which we observed may affect the functioning of this organ. Such an effect would permit passage of worm eggs to the intestinal lumen and allow the invasion of this organ by other cecal parasites.

In mice and rats excystation of *N. attenuatus* cysts occurred in the lower in-

testine. However, parasites were not observed to mature. Thus conditions may exist in these rodents to allow excystation but not to support development of the parasite. These results were unexpected because of previous findings of experimental infections of rodents with other, closely related notocotylid species (Herber, 1942). From the gross and histopathologic changes of the rodent intestine it is apparent that the parasites penetrated the tissue and were sequestered and walled off in granulomata. The mechanical damage produced by the large nodular lesions may be responsible for the changes of the fecal consistency and heavy infections of rodents may result in malnutrition following interruption of peristalsis and the inability to absorb food. In the wild, this species of parasite may not use rats and mice as definitive hosts, but other rodents such as muskrats (*Ondatra zibethica*) should also be investigated as possible hosts for transmission. The production of granulomata by cecal parasites which invade abnormal hosts is valuable information on the cues used by such parasites in establishing themselves within their hosts.

Finally, it is necessary to consider the role of pond residents such as mallards in the epizootiology of the parasite. Despite an abundance of *N. attenuatus* metacercariae in the ponds with permanent resident mallards, birds sampled from there were not infected. Similar observations also were made by Roscoe and Huffman (1983). Huffman and Roscoe (1986) demonstrated that *A. platyrhynchos* can acquire resis-

tance to reinfection with flukes. The presence of a stable parasite population which is not supported in wild resident birds or mammals is evidence that this parasite is using migratory waterfowl temporarily resident in the ponds as the main definitive host population.

ACKNOWLEDGMENTS

We are grateful to Mr. Benedict J. Hren and to The Wildfowl Trust of North America for providing *Physa acuta* snails. Grateful thanks are due Dr. Jane E. Huffman who reviewed the manuscript. This work was supported in part by AKC Fund of New York.

LITERATURE CITED

- ASH, L. R., AND T. C. ORIHIEL. 1987. Parasites, a guide to laboratory procedures and identification. American Society of Clinical Pathologists, Chicago, Illinois, 328 pp.
- DAWES, B. 1968. The Trematoda. Cambridge University Press, Cambridge, London, England, 644 pp.
- ERKINA, N. G. 1954. Developmental cycle of the trematode *Notocotylus chionis*, a parasite of water birds. Lectures of Academy of Sciences of the U.S.S.R. 97: 559-560.
- FRIED, B. 1970. Infectivity, growth, development, excystation and transplantation of *Zygocotyle lunata* (Trematoda) in the chick. The Journal of Parasitology 56: 44-47.
- , AND D. M. GAINSBURG. 1980. Concurrent infection of cecal trematodes, *Zygocotyle lunata*, and *Notocotylus* sp., in the domestic chick and observations on host-parasite relationships of *Notocotylus* sp. The Journal of Parasitology 66: 502-505.
- , AND P. D. NELSON. 1978. Host-parasite relationships of *Zygocotyle lunata* (Trematoda) in the domestic chick. Parasitology 77: 49-55.
- , AND L. C. ROSA-BRUNET. 1991. Cultivation of excysted metacercariae of *Echinostoma caproni* (Trematoda) to ovigerous adult on the chick chorioallantois. The Journal of Parasitology 77: 568-571.
- GRACZYK, T. K., AND C. J. SHIFF. 1993. Excystment in vitro of *Notocotylus attenuatus* (Rudolphi, 1809) (Trematoda: Notocotylidae) metacercariae. The Journal of Parasitology 79: 92-97.
- HERBER, E. C. 1942. Life history studies on two trematodes of the subfamily Notocotylinae. The Journal of Parasitology 28: 179-196.
- HUFFMAN, J. E., AND D. E. ROSCOE. 1986. Acquired resistance in mallard duck (*Anas platyrhynchos*) to the infection with *Sphaeridiotrema globulus* (Trematoda). The Journal of Parasitology 72: 958-959.
- LAPAGE, G. 1961. A list of the parasitic protozoa, helminths and arthropoda from species of the family Anatidae. Parasitology 51: 1-109.
- MALEK, E. T. A. 1951. Menthol relaxation of helminths before fixation. The Journal of Parasitology 37: 321.
- MARTIN, W. E. 1956. The life cycle of *Catantropis johnsoni* n. sp. (Trematoda: Notocotylidae). Transactions of the American Microscopical Society 75: 117-128.
- MCDONALD, M. E. 1981. Key to trematodes reported in waterfowl. Fish and Wildlife Service Resource Publication 142, Washington, D.C., 156 pp.
- PERSSON, L., K. BORG, AND H. FALT. 1974. On the occurrence of endoparasites in eider ducks in Sweden. Vitrevy 9: 1-24.
- RADLETT, A. J. 1979. Excystation of *Notocotylus attenuatus* (Rudolphi, 1809) Kossack, 1911 (Trematoda: Notocotylidae) and their localization in the cecum of the domestic fowl. Parasitology 79: 411-416.
- . 1980. The structure and possible function of the ventral papillae of *Notocotylus attenuatus* (Rudolphi, 1809) Kossack, 1911 (Trematoda: Notocotylidae). Parasitology 80: 241-246.
- ROSCOE, D. E., AND J. E. HUFFMAN. 1983. Fatal enteritis caused by *Sphaeridiotrema globulus* (Trematoda: Psilostomatidae) in a whistling swan. Journal of Wildlife Diseases 19: 370-371.
- SCHELL, S. C. 1985. Trematodes of North America. University Press of Idaho, Moscow, Idaho, 263 pp.
- SKRJABIN, K. I. 1964. Keys to the trematodes of animals and man. University of Illinois Press, Urbana, Illinois, 351 pp.
- SOKAL, R. R., AND F. J. ROHLF. 1981. Biometry, 2nd ed. W. H. Freeman and Company, New York, New York, 859 pp.
- WRIGHT, C. A. 1971. Flukes and snails. Science of biology series, No. 4. George Allen and Unwin Ltd., London, United Kingdom, 168 pp.

Received for publication 6 November 1992.