



Phocine Distemper in Harbor Seals (*Phoca vitulina*) from Long Island, New York

Authors: Duignan, Padraig J., Sadove, Samuel, Saliki, Jeremiah T., and Geraci, Joseph R.

Source: Journal of Wildlife Diseases, 29(3) : 465-469

Published By: Wildlife Disease Association

URL: <https://doi.org/10.7589/0090-3558-29.3.465>

BioOne Complete (complete.BioOne.org) is a full-text database of 200 subscribed and open-access titles in the biological, ecological, and environmental sciences published by nonprofit societies, associations, museums, institutions, and presses.

Your use of this PDF, the BioOne Complete website, and all posted and associated content indicates your acceptance of BioOne's Terms of Use, available at www.bioone.org/terms-of-use.

Usage of BioOne Complete content is strictly limited to personal, educational, and non - commercial use. Commercial inquiries or rights and permissions requests should be directed to the individual publisher as copyright holder.

BioOne sees sustainable scholarly publishing as an inherently collaborative enterprise connecting authors, nonprofit publishers, academic institutions, research libraries, and research funders in the common goal of maximizing access to critical research.

SHORT COMMUNICATIONS

Journal of Wildlife Diseases, 29(3), 1993, pp. 465-469
© Wildlife Disease Association 1993

Phocine Distemper in Harbor Seals (*Phoca vitulina*) from Long Island, New York

Padraig J. Duignan,^{1,4} Samuel Sadove,² Jeremiah T. Saliki,³ and Joseph R. Geraci,¹ ¹ Department of Pathology, Ontario Veterinary College, University of Guelph, Guelph, Ontario, Canada N1G 2W1; ² Okeanos Ocean Research Foundation, Incorporated, 278 East Montauk Highway, Hampton Bays, New York 11946, USA; ³ National Veterinary Services Laboratories, Foreign Animal Disease Diagnostic Laboratory, Greenport, New York 11944, USA. ⁴ Author for reprint requests

ABSTRACT: The first occurrence of phocine distemper (PD) disease in harbor seals (*Phoca vitulina*) from the United States is reported. Two seals stranded on Long Island, New York (USA) in February 1992 with clinical signs of respiratory distress, fever, and depression. Pneumonia and diffuse pulmonary congestion were the most significant post mortem findings. On histologic examination one seal had a diffuse broncho-interstitial pneumonia with formation of syncytia. The principal lesion in the second animal was nonsuppurative meningoencephalitis. Using immunoperoxidase staining, PD viral antigen was found in the cytoplasm of bronchiolar epithelium and cerebral cortex neurons. With a differential virus neutralization test, there were higher titers against phocine distemper virus (PDV) than against canine distemper virus. Thus, PDV is the most likely agent responsible for the observed lesions.

Key words: *Phoca vitulina*, harbor seal, *Morbillivirus*, phocine distemper, broncho-interstitial pneumonia, syncytia, nonsuppurative meningoencephalitis, immunoperoxidase staining, virus neutralization titer, first case.

We report the first occurrence of clinical phocine distemper (PD) disease in harbor seals, *Phoca vitulina*, from the east coast of the United States. Morbilliviruses, particularly the recently discovered phocine distemper virus (PDV), have emerged as the most pathogenic infectious agents in marine mammals. In 1987, a virus closely related to canine distemper virus (CDV), tentatively called PDV 2, killed over 10,000 baikal seals (*Phoca sibirica*) in Lake Baikal, USSR (Grachev et al., 1989; Visser et al., 1990). This epizootic was followed in 1988 by the most devastating marine

mammal mass-mortality event ever recorded; it claimed almost 18,000 harbor seals and several hundred gray seals (*Halichoerus grypus*) in northwestern Europe (Harwood, 1989; Kennedy, 1990). Based on monoclonal antibody cross-reactivity (Cosby et al., 1988; Trudgett et al., 1991; Orvell and Sheshberadaran, 1991), DNA-RNA hybridization (Mahy et al., 1988), and nucleotide sequence analysis (Curran et al., 1990), the virus, named PDV 1, was distinct from other members of the *Morbillivirus* genus. Based on retrospective serological surveys conducted on pinniped populations worldwide since 1988, morbillivirus infection may be widespread without necessarily causing high mortality. Serum neutralizing antibodies to CDV were found in the sera of both Greenland harp seals (*Phoca groenlandica*) and ringed seals (*Phoca hispida*), collected in 1985 and 1986 (Dietz et al., 1989), and in Antarctic crabeater seals (*Lobodon carcinophagus*) and leopard seals (*Hydrurga leptonyx*) (Bengtson et al., 1991). A high prevalence of PDV-neutralizing antibodies also was found in harp seals from the Barents Sea and north of Jan Mayen (West Ice) (Markussen and Have, 1992) and in a small sample of gray and harbor seals from Sable Island, Nova Scotia, Canada (Ross et al., 1992). Serology on seals that have stranded on the New England (USA) and New York (USA) coasts since 1988 has shown positive titers to CDV, or a closely related morbillivirus, but no evidence of clinical disease

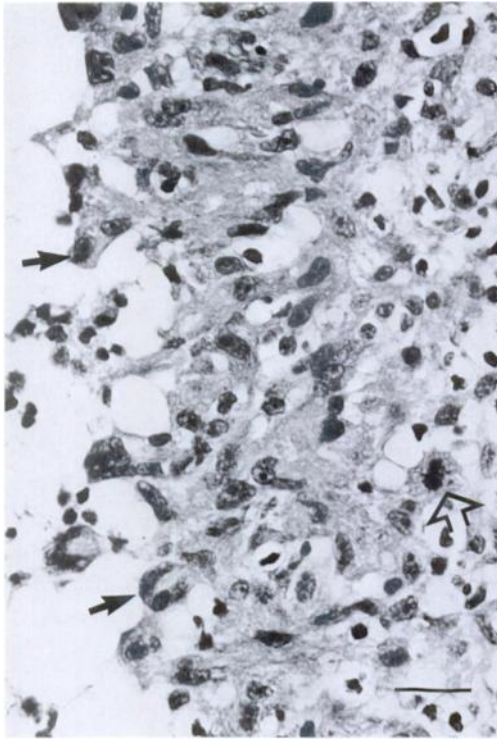


FIGURE 1. Bronchiole of a harbor seal with phocine distemper. Epithelial hyperplasia is shown by the mitotic figure (open arrow). Syncytia are forming in the epithelium and shedding into the lumen (dark arrows). H&E. Bar = 20 μ m.

(Duignan and Geraci, unpubl.; Early, pers. comm.; Sadove and Saliki, unpubl.).

In February and March 1992, an increase was noted in the number of pinnipeds stranded on Long Island, New York. Two of these animals were juvenile (<2 yr old) female harbor seals found in February on Fire Island (40°44'N, 72°49'W; 40°38'N, 73°08'W) showing signs of fever, depression, and respiratory distress. Both seals were taken to the Okeanos rehabilitation facility, Hampton Bays, New York, where a whole blood sample was collected from the extra-dural vein for serology. The first seal died after 4 days in captivity and the second after a week. On post mortem examination the principal finding was pulmonary congestion, edema, and interstitial emphysema with focal areas of consolidation in all lung lobes. Tissue samples

from the respiratory, nervous, gastrointestinal, lymphoreticular, and urinary systems were fixed in 10% neutral buffered formalin, treated with alcohol and xylene, and embedded in paraffin. Sections were cut at 5 μ m and stained with hematoxylin and eosin (H&E) for light microscopy.

In the first seal, the most significant histological lesion was subacute diffuse broncho-interstitial pneumonia characterized by hyperplasia and dysplasia of bronchiolar epithelium with formation of syncytia (Fig. 1). Peribronchiolar glands were ectatic, containing mucus, neutrophils, and necrotic debris, and often lined by focally necrotic or attenuated epithelium. Proliferation of type II pneumocytes and formation of syncytia were evident in many lobules and there was a peribronchiolar infiltration of lymphocytes. Lung lesions in the second seal consisted of lobular pyogranulomatous pneumonia associated with a nematode tentatively identified as *Otstrongylus circumlitus*. In this animal the most significant lesion was nonsuppurative meningoencephalitis of the cerebrum. There was multifocal or laminar necrosis of neurons with gliosis and hypertrophy of capillary endothelium in the subpial grey matter. Necrotic neurons were shrunken and rounded with pyknotic nuclei and neuronophagic nodules were common. Small discrete eosinophilic intracytoplasmic and intranuclear inclusion bodies were observed in some neurons and glial cells. Perivascular and meningeal cell infiltrate consisted of lymphocytes, plasma cells, macrophages, and some neutrophils.

An avidin biotin complex (ABC) immunoperoxidase staining technique was used to test for the presence of morbillivirus antigen in formalin-fixed paraffin-embedded tissues (Duignan et al., 1992; Daoust et al., 1993). Monoclonal antibodies (mAb's) to epitopes of the hemagglutinin (H) protein of PDV (clones 1.3, 2.80, and 2.1) were used as the primary antibody. The other reagents used were part of a commercially available kit (Vectastain®, Elite ABC kit, Vector Laboratories, Bur-

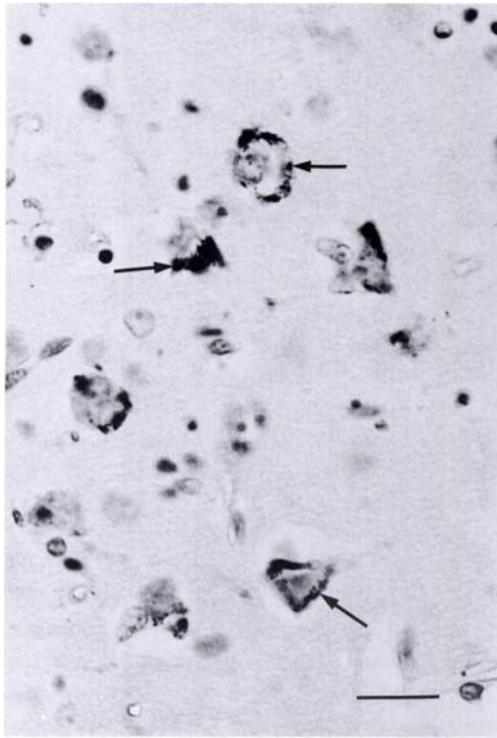


FIGURE 2. Cerebral cortex of a harbor seal with phocine distemper. Immunoperoxidase staining of morbillivirus antigen in neuronal cytoplasm (arrows). Mayer's hematoxylin counterstain. Bar = 20 μm .

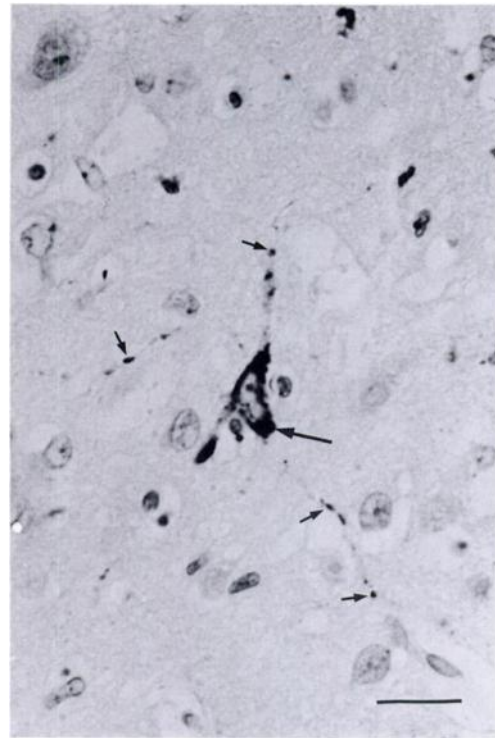


FIGURE 3. Cerebral cortex; harbor seal with phocine distemper. Immunoperoxidase staining of morbillivirus antigen in neuronal cytoplasm and processes (arrows). Mayer's hematoxylin counterstain. Bar = 20 μm .

lingame, California, USA). Tissues from a harp seal with a known morbillivirus infection and a normal harbor seal were used respectively as positive and negative controls (Daoust et al., 1993). Test sections were also stained without a primary antibody and using irrelevant primary antibodies. All sections were lightly counterstained in Mayer's hematoxylin prior to mounting (Luna, 1968). Specificity of the mAbs was confirmed by using tissues from a CDV-infected raccoon (*Procyon lotor*) as a control. Clone 1.3 binds to both CDV and PDV whereas clones 2.80 and 2.1 are PDV-specific (Trudgett et al., 1991). Positive staining of morbillivirus antigen was observed with all mAbs, but clone 1.3 gave the strongest response. Canine distemper virus antigen in raccoon tissue stained only when clone 1.3 was used as primary antibody and no staining was observed in the

negative-control seal tissue or with irrelevant primary antibodies. Phocine distemper virus antigen was detected in the cytoplasm of peribronchiolar gland epithelium from the first seal. In the second seal individual neurons throughout the cerebrum and groups of neurons, often arranged in a laminar pattern, stained positively (Fig. 2). Staining was largely confined to the peripheral cytoplasm of neurons and frequently extended along axons and dendrites (Fig. 3).

Serum from both seals was tested for neutralizing activity with CDV (Onderstepoort strain) and PDV 1 (PDV 1-2-6A) using a micromethod described for other morbilliviruses (Rossiter et al., 1985). Briefly, two-fold dilutions of sera were made in minimum essential medium supplemented with 5% fetal bovine serum and

dispensed in duplicate into wells of 96-well microtiter plates. An equal volume (50 μ l) of virus containing approximately 100 tissue culture infective doses (TCID₅₀) was added to each well and the plates incubated at 37 C for 1 hr. One hundred μ l containing 10⁴ Vero cells (American Type Culture Collection, Rockville, Maryland, USA) then were added to each well and the plates were incubated at 37 C in 5% carbon dioxide. After both 3 and 8 days the Vero cell monolayers were examined for cytopathic effects (CPE). Titers were expressed as log₂ of the reciprocal of the highest dilution of serum that completely neutralized CPE in duplicate wells. Virus neutralization titers against PDV were 4 and 7 for the first and second seals, respectively, while corresponding titers against CDV were 2 and 4.

Based on immunohistochemistry and differential virus neutralization, these harbor seals were infected by a morbillivirus similar, if not identical, to PDV 1. This is the first report of clinical disease caused by this virus in North American harbor seals and it follows recent confirmation of clinical morbillivirus infection in a harp seal from eastern Canada (Daoust et al., 1993). We do not know how the harbor seals contracted PDV infection. The virus may have been transmitted directly, or indirectly, from harp seals in which the infection is thought to be enzootic and largely sub-clinical (Dietz et al., 1989; Markussen and Have, 1992). Now that populations of Arctic pinnipeds are expanding (Roff and Bowen, 1986; Bowen et al., 1987), such transfer of viruses is becoming increasingly plausible. Furthermore, greater numbers of juvenile animals are dispersing southward each year, a trend that is reflected in pinniped stranding records from New England, Long Island, New York, and Florida (USA) (Odell, 1991).

Further discussion on the origin, relationships, and significance of morbillivirus in North American pinnipeds is speculative without more extensive studies. The

relationship of the morbillivirus in the western Atlantic to PDV 1 is not yet known; however, characterization of an isolate is underway. We currently are conducting a multidisciplinary epidemiological investigation, in conjunction with government agencies in the United States and Canada and marine mammal stranding networks, to determine prevalence, host range, and significance of infection on the Atlantic coast.

The authors thank M. E. McLaughlin, DVM, for medical care at the Okeanos Foundation, Helga Hunter and Ted Eaton, OVC, for technical and photographic assistance. Monoclonal antibodies were donated by Carol Lyons, Dr. A. Trudgett, and Dr. B. Rima, The Queen's University, Belfast, Northern Ireland. The work was funded in part by New York State Department of Environmental Conservation, the Office of Protected Resources, The National Marine Fisheries Service, USA, and the Natural Sciences and Engineering Research Council of Canada (Grant #400-29 to JRG).

LITERATURE CITED

- BENGTSON J. L., P. BOVENG, U. FRANZEN, P. HAVE, M. P. HEIDE-JORGENSEN, AND T. L. HARKONEN. 1991. Antibodies to canine distemper virus in Antarctic seals. *Marine Mammal Science* 7: 85-87.
- BOWEN, W. D., R. A. MYERS, AND K. HAY. 1987. Abundance estimation of a dispersed dynamic population: Hooded seals (*Cystophora cristata*) in the northwest Atlantic. *Canadian Journal of Fisheries and Aquatic Science* 44: 282-295.
- COSBY, S. L., S. MCQUAID, N. DUFFY, C. LYONS, B. K. RIMA, G. M. ALLEN, S. J. MCCULLOUGH, S. KENNEDY, J. A. SMYTH, F. MCNEILLY, AND C. ORVELL. 1988. Characterization of a seal morbillivirus. *Nature* 336: 115-116.
- CURRAN, M. D., C. O'LOAN, B. K. RIMA, AND S. KENNEDY. 1990. Nucleotide sequence analysis of phocine distemper virus reveals its distinctness from canine distemper virus. *The Veterinary Record* 127: 430-431.
- DAOUST, P.-Y., D. M. HAINES, J. THORSEN, P. J. DUGNAN, AND J. R. GERACI. 1993. Phocine distemper in a harp seal (*Phoca groenlandica*) from the Gulf of St. Lawrence, Canada. *Journal of Wildlife Diseases* 29: 114-117.

- DIETZ, R., C. T. ANSEN, P. HAVE, AND M. P. HEIDE-JORGENSEN. 1989. Clue to seal epizootic? *Nature* 338: 627.
- DUIGNAN, P. J., J. R. GERACI, J. A. RAGA, AND N. CALZADA. 1992. Pathology of morbillivirus infection in striped dolphins (*Stenella coeruleoalba*) from Valencia and Murcia, Spain. *Canadian Journal of Veterinary Research* 56: 242-248.
- GRACHEV, M. A., V. P. KUMAREV, L. V. MAMEV, V. L. ZORIN, L. V. BARANOVA, N. N. DENEKINA, S. I. BELIKOVA, E. A. PETROV, V. S. KOLESNIK, V. N. DOROFEEV, A. M. BEIM, V. N. KUDELIN, F. G. NAGIEVA, AND V. N. SIDOROV. 1989. Distemper virus in Baikal seals. *Nature* 338: 209.
- HARWOOD, J. 1989. Lessons from the seal epidemic. *New Scientist* 121: 38-42.
- KENNEDY, S. 1990. A review of the 1988 European seal morbillivirus epizootic. *The Veterinary Record* 127: 563-567.
- LUNA, L. G. 1968. Manual of histologic staining methods of the Armed Forces Institute of Pathology, 3rd ed. McGraw-Hill Book Company, New York, New York, 33 pp.
- MAHY, B. W. J., T. BARRETT, S. EVANS, E. C. ANDERSON, AND C. J. BOSTOCK. 1988. Characterization of a seal morbillivirus. *Nature* 336: 115.
- MARKUSSEN, N. H., AND P. HAVE. 1992. Phocine distemper virus infection in harp seals (*Phoca groenlandica*). *Marine Mammal Science* 8: 19-26.
- ODELL, D. K. 1991. A review of the Southeastern United States Marine Mammal Stranding Network 1978-1987. In *Marine mammal strandings in the United States*, J. E. Reynolds and D. K. Odell (eds.). National Oceanic and Atmospheric Administration Technical Report, National Marine Fisheries Service 98; U.S. Department of Commerce, Springfield, Virginia, pp. 19-24.
- ORVELL, C., AND H. SHESBERADARAN. 1991. Phocine distemper virus is phylogenetically related to canine distemper virus. *The Veterinary Record* 129: 267-269.
- ROFF, D. A., AND W. D. BOWEN. 1986. Further analysis of population trends in the northwest Atlantic harp seal (*Phoca groenlandica*) from 1967-1985. *Canadian Journal of Fisheries and Aquatic Science* 43: 553-564.
- ROSS, P. S., I. K. G. VISSER, H. W. J. BROEDERS, M. W. G. VAN DE BILT, W. D. BOWEN, AND A. D. M. E. OSTERHAUS. 1992. Antibodies to phocine distemper virus in Canadian seals. *The Veterinary Record* 130: 514-516.
- ROSSITER, P. B., D. M. JESSETT, AND W. P. TAYLOR. 1985. Microneutralization system for use with different strains of peste des petits ruminants and rinderpest virus. *Tropical Animal Health and Production* 17: 75-81.
- TRUDGETT, B. A., C. LYONS, M. J. WELSH, N. DUFFY, S. J. MCCULLOUGH, AND F. MCNEILLY. 1991. Analysis of a seal and a porpoise morbillivirus using monoclonal antibodies. *The Veterinary Record* 128: 61.
- VISSER, I. K. G., V. P. KUMAREV, C. ORVELL, P. DE VRIES, H. W. J. BROEDERS, M. W. G. VAN DE BILT, J. GROEN, J. S. TEPPEMA, M. C. BURGER, F. G. C. M. UYTDEHAAG, AND A. D. M. E. OSTERHAUS. 1990. Comparison of two morbilliviruses isolated from seals during outbreaks of distemper in northwest Europe and Siberia. *Archives of Virology* 111: 148-164.

Received for publication 10 November 1992.