

Epizootic Mortality of Free-living Green Turtles, *Chelonia mydas*, Due to Coccidiosis

Authors: Gordon, A. N., Kelly, W. R., and Lester, R. J. G.

Source: Journal of Wildlife Diseases, 29(3) : 490-494

Published By: Wildlife Disease Association

URL: <https://doi.org/10.7589/0090-3558-29.3.490>

BioOne Complete (complete.BioOne.org) is a full-text database of 200 subscribed and open-access titles in the biological, ecological, and environmental sciences published by nonprofit societies, associations, museums, institutions, and presses.

Your use of this PDF, the BioOne Complete website, and all posted and associated content indicates your acceptance of BioOne's Terms of Use, available at www.bioone.org/terms-of-use.

Usage of BioOne Complete content is strictly limited to personal, educational, and non - commercial use. Commercial inquiries or rights and permissions requests should be directed to the individual publisher as copyright holder.

BioOne sees sustainable scholarly publishing as an inherently collaborative enterprise connecting authors, nonprofit publishers, academic institutions, research libraries, and research funders in the common goal of maximizing access to critical research.

Epizootic Mortality of Free-living Green Turtles, *Chelonia mydas*, Due to Coccidiosis

A. N. Gordon,^{1,3} W. R. Kelly,¹ and R. J. G. Lester,² ¹ Department of Veterinary Pathology, The University of Queensland, Brisbane, Queensland 4072, Australia; ² Department of Parasitology, The University of Queensland, Brisbane, Queensland 4072, Australia. ³ Author to whom all correspondence should be addressed.

ABSTRACT: At least 70 wild green sea turtles, *Chelonia mydas*, died in the Moreton Bay area of southeast Queensland, Australia over 6 wk in spring 1991. Based on the necropsy of 24 turtles, there was a severe enteritis or encephalitis associated with *Caryospora cheloniae*, a coccidial pathogen previously recorded only in farm-reared *Ch. mydas* hatchlings. Infection was characterized by the presence of coccidia in extra-intestinal lesions. Oocysts were observed to sporulate, after which sporozoites escaped into seawater to form a novel stellate configuration. We conclude that *C. cheloniae* is pathogenic for life stages other than hatchling *Ch. mydas* and that naturally-occurring coccidiosis is a significant disease of free-living *Ch. mydas*.

Key words: Coccidiosis, *Caryospora cheloniae*, green turtle, *Chelonia mydas*.

Although mass mortalities of sea turtles have been reported (Rueda, 1990), the causes of these events are rarely determined. Fibropapillomatosis (Balazs and Pooley, 1991) and spirorchidiasis (Glazebrook et al., 1989) are two diseases with a high prevalence in certain populations of green turtles (*Chelonia mydas*), but are associated with only sporadic mortalities. Coccidiosis due to *Caryospora cheloniae* was the cause of epizootic mortality of farm-reared *Ch. mydas* hatchlings in the West Indies (Rebell et al., 1974). We describe the first reported epizootic of coccidiosis in free-living green turtles.

Moreton Bay, in southeast Queensland, Australia (centered on 27°22'S, 153°15'E) is a major feeding ground for green as well as loggerhead turtles (*Caretta caretta*). From 8 October to 20 November 1991, ≥70 *Ch. mydas* were reported stranded on Moreton Bay beaches or found weak and listless in the water. Approximately one third of these turtles were examined clinically; they then were either killed humanely by injection of 60 mg/kg pento-

barbitone sodium ("Valbarb," Pitman-Moore Australia Limited, North Ryde, New South Wales, Australia) into the dorsal cervical sinus, or were redirected to oceanaria to attempt rehabilitation. Most of the latter turtles subsequently died. Clinically, the most consistent signs were pronounced weakness and depression. Turtles returned to the water would deliberately re-beach. Sunken eyes in some turtles were evidence for possible dehydration. Only two animals were seen to pass diarrhetic feces; however, several turtles exhibited definite neurological disturbances, including circling, head-tilting and nystagmus.

Seventeen turtles underwent detailed necropsy examination; the gastrointestinal tracts only of a further seven animals were examined. Most cases had severe exudative enteritis, ranging from mucoid in some animals, to fibrinous or necrotising in others, and involving almost the entire intestine, sparing only the proximal duodenum. The intestinal mucosa varied in color from deep crimson to yellow or green where it had been replaced by a friable diphtheritic membrane. Miliary white foci up to 1 mm diameter were found in the thyroid glands of four turtles, and renal hemorrhages in two. Stable foam was frequently present in airways. Other sporadic findings were of minor chronic lesions such as hepatic fungal abscesses, and evidence of past infection with spirorchid flukes. Most turtles were in good nutritional condition, suggesting a relatively acute course.

Tissues were fixed in 10% neutral buffered formalin or Bouin's fixative (Lillie, 1954), embedded in paraffin, sectioned at 5 μm and stained with hematoxylin and eosin. We observed a profound alteration

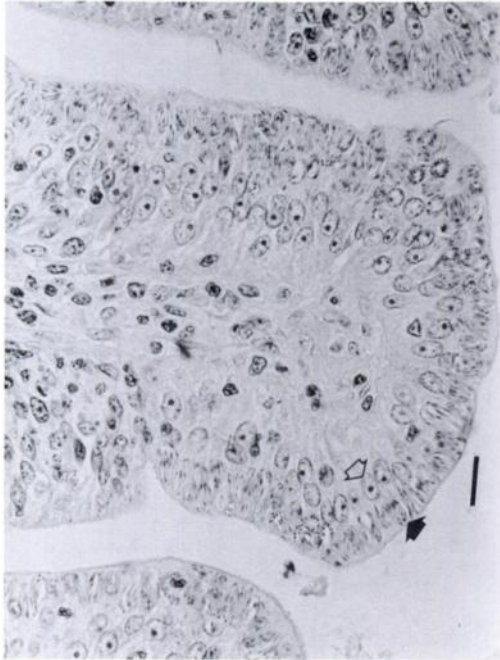


FIGURE 1. Heavily parasitized duodenal epithelium of a green turtle. In each cell the coccidial schizont (closed arrow) is located superior to the host cell nucleus (open arrow). H&E. Bar = 20 μ m.

of intestinal architecture, with hyperplastic enterocytes occupied generally by gametogenous coccidial stages, although epithelial schizonts were occasionally observed (Fig. 1). Necrosis of sheets of infected enterocytes resulted in diphtheritic membrane formation. Schizonts were present in the intestinal lamina propria as well as in a range of extra-intestinal sites including kidney, thyroid gland and brain (Fig. 2). In a large proportion of cases there was meningoencephalitis characterized by meningeal thickening with inflammatory cells and fibroblasts, as well as perivascular cuffs and randomly-distributed foci of inflammatory cells (granulocytes and lymphocytes) in the parenchyma. Schizonts in the brain sometimes were seen in the process of rupturing, and the inflammatory response to the free merozoites was always intense. In two turtles which had recovered from enteritis, unremitting neurological problems due to encephalitis necessitated euthanasia. However, in most turtles,

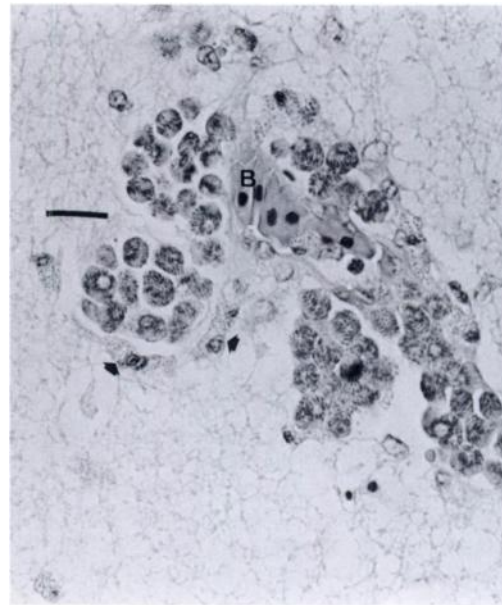


FIGURE 2. Forebrain of green turtle with coccidial schizonts grouped around a blood vessel (B). Early inflammatory response includes a few granulocytes (arrows). H&E. Bar = 20 μ m.

fatalities were attributed to the severe intestinal lesions.

In mucosal scrapings of both small and large intestine, we observed abundant elongated thin-walled oocysts in most turtles affected with enteritis. Oocysts purified by differential centrifugation of intestinal contents in filtered seawater were incubated in Petri dishes for 5 days at 28 C and the seawater was changed daily. Sporulation was completed in 15 to 24 hr. The morphology of sporulated oocysts conformed to the original description of *Caryospora cheloniae* (Leibovitz et al., 1978): elongate, ellipsoidal oocysts containing a single sporocyst with eight sporozoites (Fig. 3). Unlike the original description, no sporocysts were observed within oocysts. Nineteen sporocysts measured 37 to 51 μ m by 10 to 16 μ m (\bar{x} , 44 by 13 μ m), which is larger than those in the original description, though the ranges overlap. The difference may be due to adult rather than hatchling hosts, or to a different temperature of development. Within 24 hr the sporocyst split transversely into

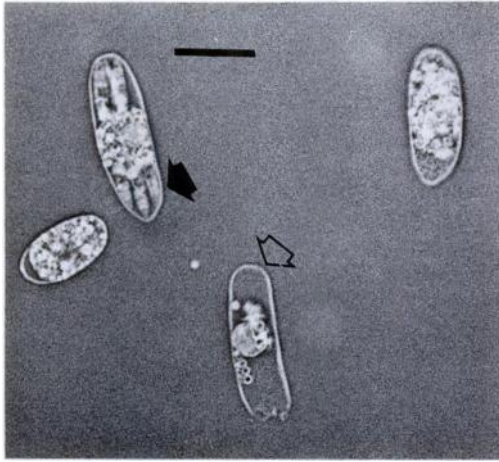


FIGURE 3. Unstained wet mount of sporulated sporocyst (closed arrow) of *C. cheloniae*, with two unsporulated sporocysts and a sporocyst which has excysted (open arrow). Bar = 20 μ m.

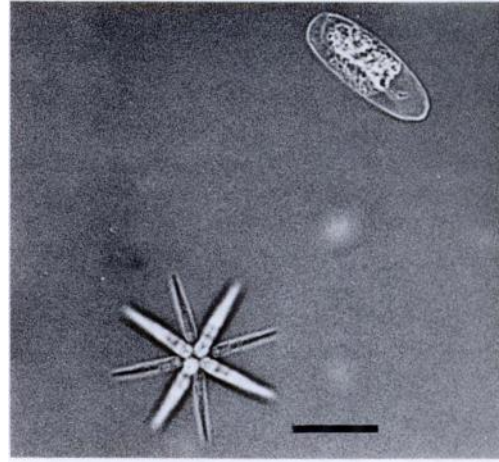


FIGURE 4. Unstained wet mount of "star" formation following sporulation of *C. cheloniae* sporocyst, as well as an unsporulated sporocyst. Bar = 20 μ m.

two unequal parts and all eight sporozoites glided out, typically with the acute end foremost. The excysted sporozoites were elongated, and ranged from 15 to 25 μ m in length. They arranged themselves into a star (Fig. 4), with their obtuse ends touching and remained in this formation for 2 to 3 days, after which they disintegrated. Stars readily rolled and floated in a slight current whereas sporocysts remained static on the bottom of the dish. Sporocysts which did not spontaneously hatch within the first 24 hr decomposed over the next 2 days. The spontaneous release of sporozoites into the environment and the unusual star formation were observed on each of six occasions when oocysts were incubated. They have not been described for any other coccidian. They were not reported by Leibovitz et al. (1978), possibly because the potassium dichromate which they added to the seawater killed the sporozoites as they excysted. In the present study, the low proportion of oocysts which sporulated from the first turtle (19%) may have been due to the release of immature oocysts during the breakdown of the mucosa in the terminal stages of the disease. Based on the rapid disintegration of the sporozoites, we

suggest that their immediate uptake by a host, either another turtle or perhaps an intermediate host, may be required.

From reports of coccidial disease in free-living fauna (Barker et al., 1972; Tuggle and Crites, 1984; Parker and Duszynski, 1986), we believe the etiological factors are similar to those for captive animals: immunological naivety, overcrowding and poor hygiene. Poor hygiene was thought responsible for the original epizootic of coccidiosis in hatchling *Ch. mydas* (Rebell et al., 1974). Further work is required to elucidate the conditions which allowed an epizootic of fatal coccidiosis in free-living *Ch. mydas*. The turtles were allocated to age classes based on a combination of curved carapace length (CCL) and gonadal maturity (Limpus and Reed, 1985). Most of the affected turtles were large subadult or pubescent animals. The mean (\pm SE) CCL for 24 turtles was 834 mm (\pm 29), with a range of 509 to 1,051 mm. *Chelonia mydas* take up residence in coastal feeding grounds as small juveniles with a CCL of about 400 mm, remaining in the one feeding ground for extended periods, perhaps years, before moving to another major area (Limpus et al., 1984). Given this life history, it is not clear whether the turtles

would have had prior exposure to *C. cheloniae*. In coccidial infections in other species, older animals with no past exposure to coccidia are thought to be as susceptible or more susceptible than young ones to similar infective doses (Fernando, 1982). This may account for the apparent predilection for older turtles in the affected sample. Segregation of the different size classes within a feeding ground also may be a significant factor. Infection presumably occurred through ingestion of infective sporocysts, stars or "caryocysts"—an encysted form that develops in tissues of secondary hosts in some *Caryospora* species (Lindsay and Sundermann, 1989). A heavy buildup of infective stages in the feeding grounds may have precipitated the epizootic.

Immunity in poikilotherms is at least partially temperature-dependent (Kollias, 1984). In Moreton Bay, Read (1991) recorded winter surface water temperatures as low as 15 C during 1991. Activity in *Ch. mydas* is predicted to cease at these temperatures (Felger et al., 1976), yet turtles in Moreton Bay were observed foraging; this activity may have exposed them to high numbers of coccidial infective stages at a time when they were incapable of mounting an effective immune response. Should coccidiosis in *Ch. mydas* be related to water temperatures, it may prove to be a factor delimiting the range in which turtles are active year-round.

Caryospora cheloniae was not recorded in extra-intestinal sites in the original description, though the authors did not specify which tissues were examined. This mode of development is not unprecedented for an eimeriid coccidian (Novilla et al., 1981), and may be relatively common in poikilotherms (Overstreet, 1981). For this reason, the extra-intestinal coccidia found during this epizootic could well be *C. cheloniae*, though this remains to be confirmed through experimental infections, ultrastructural studies or immunocytochemical techniques. Recent investigators (Lindsay and Sundermann, 1989;

Dubey et al., 1990; Douglas et al., 1991, 1992) have demonstrated facultatively heteroxenous life cycles of other *Caryospora* sp. involving secondary hosts in which extra-intestinal development occurs. *Caryospora cheloniae* has been included in the genus *Caryospora* on the basis of possessing eight sporozoites within a single sporocyst; endogenous development and structure may be quite different from other *Caryospora* species (Upton and Sundermann, 1990).

For access to turtle stranding records, field and laboratory support we thank C. Limpus, N. Winney, S. Therkelsen, J. Massey, P. Couper, the Queensland Department of Environment and Heritage, and Fisheries Division of the Queensland Department of Primary Industries. We thank the staff of Sea World and Underwater World for their cooperation. This work was supported by Special Project Grant 4 from the University of Queensland.

LITERATURE CITED

- BALAZS, G. H., AND S. G. POOLEY (editors). 1991. Research plan for marine turtle fibropapilloma. National Oceanic and Atmospheric Administration Technical Memorandum, National Marine Fisheries Service Publication No. 156. National Technical Information Service, Springfield, Virginia, 113 pp.
- BARKER, I. K., K. E. HARRIGAN, AND J. K. DEMPSTER. 1972. Coccidiosis in wild grey kangaroos. *International Journal for Parasitology* 2: 187-192.
- DOUGLAS, R. J., C. A. SUNDERMANN, AND D. S. LINDSAY. 1991. Effects of route of inoculation on the site of development of *Caryospora bigenetica*. *The Journal of Parasitology* 77: 755-757.
- _____, _____, _____, AND D. R. MULVANEY. 1992. Experimental *Caryospora bigenetica* (Apicomplexa: Eimeriidae) infections in swine (*Sus scrofa*). *The Journal of Parasitology* 78: 148-151.
- DUBEY, J. P., S. S. BLACK, L. T. SANGSTER, D. S. LINDSAY, C. A. SUNDERMANN, AND M. J. TOPPER. 1990. *Caryospora*-associated dermatitis in dogs. *The Journal of Parasitology* 76: 552-556.
- FELGER, R. S., K. CLIFFTON, AND P. J. REGAL. 1976. Winter dormancy in sea turtles: Independent discovery and exploitation in the Gulf of California by two local cultures. *Science* 191: 283-285.
- FERNANDO, M. A. 1982. Pathology and pathogenicity. In *Biology of the coccidia*, P. L. Long (ed.). University Park Press, Baltimore, Maryland, pp. 287-327.

- GLAZEBROOK, J. S., R. S. F. CAMPBELL, AND D. BLAIR. 1989. Studies on cardiovascular fluke (Digenea: Spirorchhiidae) infections in sea turtles from the Great Barrier Reef, Queensland, Australia. *Journal of Comparative Pathology* 101: 231-250.
- KOLLIAS, G. V., JR. 1984. Immunologic aspects of infectious diseases. *In Diseases of amphibians and reptiles*, G. L. Hoff, F. L. Frye, and E. R. Jacobson (eds.). Plenum Press, New York, New York, pp. 661-691.
- LEIBOVITZ, L., G. REBELL, AND G. C. BOUCHER. 1978. *Caryospora cheloniae* sp. n.: A coccidial pathogen of mariculture-reared green sea turtles (*Chelonia mydas mydas*). *Journal of Wildlife Diseases* 14: 269-275.
- LILLIE, R. D. 1954. Histopathologic technic and practical histochemistry. The Blakiston Company, Inc., New York, New York, 501 pp.
- LIMPUS, C. J., AND P. C. REED. 1985. The green turtle, *Chelonia mydas*, in Queensland: A preliminary description of the population structure in a coral reef feeding ground. *In Biology of Australasian frogs and reptiles*, G. Grigg, R. Shine, and H. Ehmann (eds.). Surrey Beatty and Sons, Chipping Norton, New South Wales, Australia, pp. 47-52.
- , A. FLEAY, AND M. GUINEA. 1984. Sea turtles of the Capricornia section, Great Barrier Reef Marine Park. *In Proceedings of the symposium on the Capricornia section of the Great Barrier Reef. Past, present and future*, W. T. Ward and P. Saenger (eds.). The Royal Society of Queensland and Australian Coral Reef Society, Brisbane, Australia, pp. 61-78.
- LINDSAY, D. S., AND C. A. SUNDERMANN. 1989. Recent advances in the biology of the coccidian genus *Caryospora*. *Journal of Veterinary Parasitology* 3: 1-5.
- NOVILLA, M. N., J. W. CARPENTER, T. R. SPRAKER, AND T. K. JEFFERS. 1981. Parental (*sic*) development of eimerian coccidia in sandhill and whooping cranes. *The Journal of Protozoology* 28: 248-255.
- OVERSTREET, R. M. 1981. Species of *Eimeria* in nonepithelial sites. *The Journal of Protozoology* 28: 258-260.
- PARKER, B. P., AND D. W. DUSZYNSKI. 1986. Coccidiosis of sandhill cranes (*Grus canadensis*) wintering in New Mexico. *Journal of Wildlife Diseases* 22: 25-35.
- READ, M. A. 1991. Observations on the feeding ecology of immature green turtles, *Chelonia mydas*, in the Moreton Banks region of Moreton Bay, southeast Queensland. B.Sc. (Hons.) Thesis. Department of Zoology, University of Queensland, Queensland, Australia, 62 pp.
- REBELL, G., A. RYWLIN, AND G. ULRICH. 1974. Coccidiosis in the green turtle (*Chelonia mydas*) in mariculture. *In Proceedings of the 5th annual workshop, World Mariculture Society*, J. W. Avault, Jr. (ed.). Louisiana State University Division of Continuing Education, Baton Rouge, Louisiana, pp. 197-204.
- RUEDA, J. V. 1990. Dying turtles in Colombian waters still a mystery. *Marine Turtle Newsletter* 50: 4-6.
- TUGGLE, B. N., AND J. L. CRITES. 1984. Renal coccidiosis in interior Canada geese, *Branta canadensis interior* Todd, of the Mississippi Valley population. *Journal of Wildlife Diseases* 20: 272-278.
- UPTON, S. J., AND C. A. SUNDERMANN. 1990. *Caryospora*: Biology. *In Coccidiosis of man and domestic animals*, P. L. Long (ed.). CRC Press, Boca Raton, Florida, pp. 187-204.

Received for publication 29 July 1992.