

Fluorosis in Deer (*Odocoileus virginianus*)

Author: KARSTAD, LARS

Source: Bulletin of the Wildlife Disease Association, 3(2) : 42-46

Published By: Wildlife Disease Association

URL: <https://doi.org/10.7589/0090-3558-3.2.42>

The BioOne Digital Library (<https://bioone.org/>) provides worldwide distribution for more than 580 journals and eBooks from BioOne's community of over 150 nonprofit societies, research institutions, and university presses in the biological, ecological, and environmental sciences. The BioOne Digital Library encompasses the flagship aggregation BioOne Complete (<https://bioone.org/subscribe>), the BioOne Complete Archive (<https://bioone.org/archive>), and the BioOne eBooks program offerings ESA eBook Collection (<https://bioone.org/esa-ebooks>) and CSIRO Publishing BioSelect Collection (<https://bioone.org/csiro-ebooks>).

Your use of this PDF, the BioOne Digital Library, and all posted and associated content indicates your acceptance of BioOne's Terms of Use, available at www.bioone.org/terms-of-use.

Usage of BioOne Digital Library content is strictly limited to personal, educational, and non-commercial use. Commercial inquiries or rights and permissions requests should be directed to the individual publisher as copyright holder.

BioOne is an innovative nonprofit that sees sustainable scholarly publishing as an inherently collaborative enterprise connecting authors, nonprofit publishers, academic institutions, research libraries, and research funders in the common goal of maximizing access to critical research.

Fluorosis in Deer (*Odocoileus virginianus*)

LARS KARSTAD

Division of Zoonoses and Wildlife Diseases, Ontario Veterinary College, Guelph, Canada

Received for publication 12 December, 1966

ABSTRACT

Above normal levels of fluorides were found in the bones of deer in the vicinity of an industrial complex. The sources of fluorides for the deer were water in a pond within the industrial compound and vegetation containing moderately increased levels of fluoride. Mandibular bone fluoride contents of 4300 to 7125 ppm. were associated with pitting and black discoloration of teeth, abnormal tooth wear and fractures of teeth and jaw bones.

INTRODUCTION

In 1964, an opportunity was presented to obtain jawbones and antlers from deer which died or were killed in the vicinity of an industrial complex. Since fluorosis has occurred in cattle on pastures contaminated by the gaseous effluent from industrial processes¹, it was considered that deer, which in this case had access also to the fenced enclosure of the complex, might be indicators for environmental contamination. Accordingly, analysis was made for fluoride in jawbones and antlers from deer killed or which died on the premises and in the vicinity of the complex during the period 1962 to 1966. In addition, a number of shed antlers were included in the study.

Although the industrial processes used were believed to release little fluoride into the atmosphere, there was the possibility that deer would drink contaminated water from a pond within the fenced industrial compound. Deer were able to enter and leave the compound through two vehicle entrance gates which were usually left open, but they tended to remain in the compound because it afforded food, cover and protection from harassment by dogs and hunters. The large numbers of deer within the en-

closure soon led to severe over-browsing and the need to supplement the available vegetation with hay during the winters. Such feeding practices contributed further to the concentration of deer within the fenced area. The number of deer in the compound during the years 1964 and 1965 varied between 35 and 86, the highest numbers being present during the winter, when alfalfa hay was fed.

MATERIALS AND METHODS

Mandibles and antlers were collected from deer which died or were killed in the vicinity of the industrial complex. Bones were cleaned, dried and pulverized by sawing or by grinding small portions in a mortar and pestle. Fluoride analysis was performed by the method of Willard and Winter². Observations were made on the cause or circumstances of death, the condition of the carcass at necropsy and gross signs of disease. Ages were estimated by tooth eruption, replacement and wear³. A number of antlers and mandibles from deer in other areas were included in the study as presumed normal controls.

OBSERVATIONS

The results of analyses on mandibles and antlers collected in the vicinity of the industrial complex are presented in Table 1. For comparison, the results of analyses of bones from presumed normal deer, collected elsewhere, are listed in Table 2. The fluoride content of five

Table 1. Results of analyses for fluoride on dried fat-free bone of white-tailed deer collected in the vicinity of an industrial complex

Specimen Number	Year Collected	Age in Years	Sex	Fluoride	Comments
W109A	1962-63	2½	M	A 503 ppm.*)	annually shed antlers from same deer
W109B	1963-64	3½	M	A 886 ppm.)	
W109C	1964-65	4½	M	A1906 ppm.)	
137	1964	1	M	M 808 ppm.	
234	1964	1½	M	M1325 ppm.	
W109E	1964-65	1½	M	A1072 ppm.	shed antler
W174A	1964-65	2	M	A 512 ppm.	shed antler
W174B	1964-65	?	M	A1299 ppm.	shed antler
240	1965	2	M	M4300 ppm.	broken molar, emaciated
241	1965	1	F	M5400 ppm.	fractured jaw, emaciated
243	1965	1	M	M7125 ppm.	emaciated
244	1965	10+	F	M1664 ppm.	emaciated
246	1965	3	F	M4733 ppm.	
249	1965	1½	F	M1680 ppm.	
251	1965	1½	M	M1835 ppm.	
252	1965	1½	M	M 389 ppm.	
W292A	1965	?	M	A 715 ppm.	antlers in velvet
W292B	1965-66	?	M	A1730 ppm.	shed antler, 1 tine broken
W292C	1965-66	?	M	A 983 ppm.	shed antler, 2 tines broken
W292D	1965-66	?	M	A1656 ppm.	shed antler, 1 tine broken
W292I	1965-66	?	M	A2997 ppm.	shed antler, 2 tines broken
256	1966	1	F	M2960 ppm.	emaciated, mandibular exostoses
W 91	1966	1	M	M2197 ppm.	fore-shortened mandible, exostoses, emaciated
264	1966	10+	F	M3605 ppm.	teeth blackened
259	1966	2½	F	M4597 ppm.	teeth blackened
266	1966	1½	M	M4800 ppm.	teeth black and pitted
258	1966	2½	F	M4313 ppm.	teeth black and pitted
262	1966	2½	F	M4460 ppm.	teeth black and pitted

* Letters prefixed denote sources of bone:

A = antler; M = mandible

normal mandibles ranged from 167 to 560 ppm and two presumably normal antlers contained fluoride levels of 134 and 152 ppm. In contrast, most of the mandibles collected from deer in the vicinity of the complex contained elevated levels of fluoride, ranging from 808 to 7125 ppm, while samples of antler bone varied between 503 and 2997 ppm fluoride. Specimens W109 A, B and C in Table 1 were antlers shed by the same deer in the winters of 1962-63, 1963-64 and 1964-65, respectively. This deer was seen almost daily around the feeding areas and was known by the unusual semi-palmate formation of the antlers. There was a progressive increase in fluoride content of these three yearly sets of antlers, suggesting increasing contamination of the environment. Un-

fortunately the antlers shed by this deer in the winter of 1965-66 could not be found.

The first signs of fluorosis in the deer were seen early in 1965. The case histories of the first three affected animals were as follows:

Specimen #240 (Table 1) - a pair of mandibles from an approximately 20 month old male deer weighing 90 pounds, found dead within the fenced enclosure. The carcass was emaciated. The rear half of one of the first molars had broken away and this was associated with a roughened enlargement of the mandible, suggestive of actinomycosis. The lateral incisors and third molars were pitted and mottled (figure 1). Mandibular bone contained fluoride at a level of 4300 ppm.

This One



KBH8-UAQ-L84G

Specimen #241 - mandibles from a female deer, approximately nine months old. There was a recent unhealed fracture of the left mandible and a healed fracture of the ramus of the right mandible. The molars and premolars were severely blackened and the jawbone was porous along the gum line (figure 2). Analysis of a sample of mandibular bone revealed a fluoride content of 5400 ppm. The carcass weighed approximately 60 pounds.

Specimen #243 - mandibles from a 10 month old deer found dead. The emaciated carcass weighed 40 pounds. Marrow in the long bones was pink and watery, suggesting malnutrition. Other abnormalities found were pitting of the surfaces of the second molars, blackening of the surfaces of molars and premolars and abnormal wear of incisors. The central incisors were cupped toward the median, exposing the dentine. Fluoride analysis of mandibular bone revealed a level of 7125 ppm.

Many of the deer examined which

were approaching one year of age had pronounced thickening of the mandibles over developing molars. In some instances these bony prominences were so large that they resembled calluses of healed fractures, of the type shown in figure 2. In most cases, however, fracture lines were not demonstrable. The bone in these exostoses was either soft and cartilaginous or roughened and pitted.

Three of the young deer examined had fore-shortened mandibles. In two instances (#W92, 1965 and #W91, 1966) this was thought to have caused difficulty in feeding and to have contributed to the emaciated condition of the animals. Lesions were present in the hard palate in both deer, caused by incisors which were not brought to bear on the normal dental pad in biting and chewing. This appeared to be a congenital anomaly, however, since it was seen also in newborn deer in this herd. Such fore-shortened mandibles have been observed in a percentage of otherwise normal deer shot during regular hunting².




Figure 1. Mandible of 20 month old deer; teeth pitted and blackened.

Table 2. Results of fluoride analysis on antler and mandible bone from white-tailed deer presumed normal

Specimen Number	Year Collected	Age in Years	Sex	Specimen	Amount of Fluoride
248	1965	½	M	Mandible	167 ppm.
133	1960	1		Mandible	560 ppm.
160	1960	1½		Mandible	413 ppm.
168	1961	1		Mandible	401 ppm.
W 25	1964	3½	M	Antler	134 ppm.
W247	1966	3½	F	Mandible	499 ppm.
700	1961	4½	M	Antler	152 ppm.

DISCUSSION

Bovine fluorosis is an economic problem which occurs where abnormally high levels of fluorine are found in the soil or where excessive amounts of fluoride are released into the atmosphere by industrial processes⁵. Usually the source of fluoride in such instances is contaminated forage, rarely has contaminated water been incriminated. The first sign of fluorosis in cattle (and probably also in deer) is mottling, pitting, and black discoloration of the teeth. Affected teeth are soft and show abnormal wear. Later the leg and foot bones may become deformed or fractured, resulting in lameness.

Lameness has not been noticed as a sign of fluorosis in the deer herd under

study. At present it is impossible to assess the effects of an abnormally high intake of fluorine on the general health of the deer. The tooth abnormalities described are believed to be a sign of fluorosis. The jaw fractures in deer #241, the broken tooth in #240 and the increased rate of tooth wear seen in several animals, no doubt contributed to their deaths. It is not known if there is a relationship between fluorosis and the excessive proliferations of bone over the developing molars in some deer. We have been unable to find previous reports of fluorosis in deer.

Since the ages of deer over two years of age were estimated on the basis of tooth wear, it is obvious that tooth softness caused by fluorosis would affect

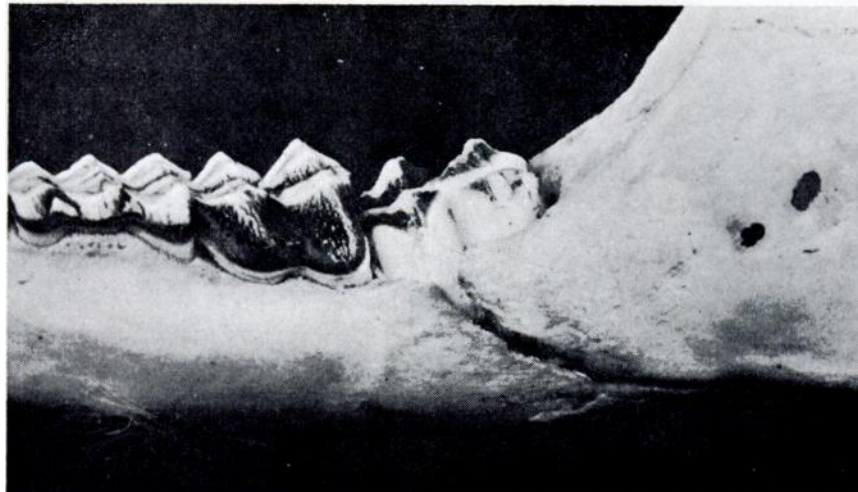


Figure 2. Mandible of nine month old deer with recent fracture and black discoloration of teeth.

these estimates. Deer with teeth badly worn, whose ages were estimated at 10+ years may actually have been much younger. Age determination by the counting of annual layers of growth in incisors might have provided more accurate data¹.

Fluoride analyses were made on forage and water samples collected in the

area. An unwashed sample of vegetation obtained in July, 1965 from an area where the deer graze had a fluoride content of 35.8 ppm, not excessively high⁵. Another source of exposure was a pond within the compound which received effluent directly from the plants. The fluoride content of this effluent was found to be 1000 to 1200 ppm.

ACKNOWLEDGEMENTS

Analyses for fluoride were performed by personnel of the Division of Pharmacology, Ontario Veterinary College. This work was supported in part by a grant from the Conjoint Agriculture - Lands and Forests Committee, Government of Ontario.

LITERATURE CITED

1. GILBERT, F. F. 1966. Aging white-tailed deer by annuli in the cementum of the first incisor. *J. Wildl. Mgmt.* 30 (1): 200-202.
2. JOHNSON, C. E. 1935. Abnormal mandible in white-tailed deer. *J. Mammal.* 16 (1): 69-70.
3. SEVERINGHAUS, C. W. 1949. Tooth development and wear as a criterion of age in white-tailed deer. *J. Wildl. Mgmt.* 13: 195-215.
4. SEVERINGHAUS, C. W., and CHEATUM, E. L. 1956. Life and times of the white-tailed deer. p. 164 in Taylor, W. P. *The Deer of North America*. The Stockpole Co., Harrisburg and Wildl. Mgmt. Inst., Wash.
5. SHUPE, J. L., MINER, M. L., and GREENWOOD, D. A. 1964. Clinical and pathological aspects of fluorine toxicosis in cattle. *Ann. N. Y. Acad. Sci.* III, (Art. 2): 618-637.
6. WILLARD, H. H. and WINTER, O. B. 1933. Volumetric method for determination of fluorine. *Ind. Eng. Chem. Anal. Ed.* 5: 7-10.

ABSTRACTS

Selected hematological and biochemical tests performed with blood and serum of adult rainbow trout (*Salmo gairdneri*) with a high incidence of hepatoma. S. F. Snieszko, J. A. Miller & C. R. Atherton. *Ann. N.Y. Acad. Sci.* 136: 191-210 (1966). Author's summary: "About 100 three-to four-year old rainbow trout of both sexes were selected at random from a large lot having a high degree of hepatoma and examined for a number of parameters. The nature of the liver lesion in this lot of trout was determined histologically as hepatoma. The weight of the livers expressed as percentage of the weight of the trout body was 1.0 to 1.5 in normal trout. In trout with hepatoma, livers were heavier and larger, exceeding 10 percent of body weight in extreme cases. The hematocrit, total serum protein, globulin, in particular, and total

serum cholesterol were higher in trout with enlarged livers. Differences between normal trout and those having greatly enlarged livers were clearly visible in paper electrophorograms made with trout sera."

A painted Turtle (*Chrysemys picta*) with ulcers in the stomach and duodenum. G. B. Pauley & D. L. Robberson. *Northwest Science* 40: 78-82 (1966). Summary: Three ulcers were observed in the gastrointestinal tract of a Painted Turtle. Two were in the stomach and one in the duodenum. All three ulcers exhibited a marked fibroblastic proliferation, scarring, heavy vascularization, and the accumulation of numerous eosinophils and neutrophils. The cause of the ulcerations was unknown but may have been ulcer-producing bacteria of the genus *Aeromonas*.