

## **AN UNUSUAL CASE OF FISH DISEASE CAUSED BY OPHRYOGLENA SP\* (Protozoa: Hymenostomatida)**

Author: HOFFMAN, GLENN L.

Source: Bulletin of the Wildlife Disease Association, 3(3) : 111-112

Published By: Wildlife Disease Association

URL: <https://doi.org/10.7589/0090-3558-3.3.111>

---

The BioOne Digital Library (<https://bioone.org/>) provides worldwide distribution for more than 580 journals and eBooks from BioOne's community of over 150 nonprofit societies, research institutions, and university presses in the biological, ecological, and environmental sciences. The BioOne Digital Library encompasses the flagship aggregation BioOne Complete (<https://bioone.org/subscribe>), the BioOne Complete Archive (<https://bioone.org/archive>), and the BioOne eBooks program offerings ESA eBook Collection (<https://bioone.org/esa-ebooks>) and CSIRO Publishing BioSelect Collection (<https://bioone.org/csiro-ebooks>).

Your use of this PDF, the BioOne Digital Library, and all posted and associated content indicates your acceptance of BioOne's Terms of Use, available at [www.bioone.org/terms-of-use](http://www.bioone.org/terms-of-use).

Usage of BioOne Digital Library content is strictly limited to personal, educational, and non-commercial use. Commercial inquiries or rights and permissions requests should be directed to the individual publisher as copyright holder.

---

BioOne is an innovative nonprofit that sees sustainable scholarly publishing as an inherently collaborative enterprise connecting authors, nonprofit publishers, academic institutions, research libraries, and research funders in the common goal of maximizing access to critical research.

A few parasitic cysts with different morphological characteristics were present in skeletal muscle. These had thin single layer eosinophilic walls with smooth external and internal surfaces. The cytoplasm of the walls was granular and there were no septae projecting from the internal surface. The cysts contained numerous banana-shaped basophilic structures, each of which had a round to oval subterminal nucleus and small basophilic granules within the cytoplasm. The cysts replaced approximately two-thirds of the sarcoplasm in the slightly swollen affected muscle bundles (Figure 2). There was no inflammatory reaction surrounding the cysts or the affected muscle bundles. The author

believes that the above described parasitic cysts are caused by a member of the genus *Sarcocystis*, based on their morphological characteristics.

#### ACKNOWLEDGEMENTS

The author wishes to acknowledge the assistance of Lt. Col. F. M. Garner, Armed Forces Institute of Pathology, Washington, D.C. and Dr. W. J. Zimmermann, Veterinary Medical Research Institute, College of Veterinary Medicine, Iowa State University, Ames, Iowa.

JOHN P. KLUGE

U.S. Department of Agriculture  
Agricultural Research Service  
Animal Disease and Parasite Research  
Division  
National Animal Disease Laboratory,  
Ames, Iowa 50010

10 May, 1967

#### AN UNUSUAL CASE OF FISH DISEASE CAUSED BY *OPHRYOGLA SP\** (Protozoa:Hymenostomatida)

During July and August, 1959, several fish which were kept in small aerated aquaria for other experiments became infected with a medium-sized ciliate which caused rapid mortality of small fish. The affected fish were largemouth black bass (*Micropterus salmoides*), bluegills (*Lepomis macrochirus*), fallfish (*Semotilus corporalis*), creek chubs (*Semotilus atromaculatus*) and sculpin (*Cottus bairdi*). Most of the fish were 2 to 3 inches long but the bass were 1.5 inches long.

The smallest fish were most seriously affected and died about 2 days after the appearance of infection, which was manifested by sloughing of large patches of epithelium (Figure 1). The larger of the affected fish which had smaller, but easily visible, white spots of sloughing epithelium, became lethargic and finally died.

Histopathological studies revealed the parasites within, as well as beneath, the

\*Identified by Dr. Jiri Lom, Academy of Science, Prague, Czechoslovakia.

epithelium. No pathologic changes were seen except necrosis of the invaded epithelium. Death of the fish was probably caused by the loss and malfunction of invaded epithelium.

When a small live affected fish was observed in good light with a dark background or under the dissection microscope, swarms of the ciliate could be seen around the fish. After the death, or removal of the fish, most of the ciliates settled to the bottom of the container, where many of them rounded up and formed cysts which were still intact on the bottom of the container after 16 days. Although the methods of treatment were not investigated by controlled experiments, a 30-minute exposure of the infected fish to formalin at a final concentration 1:4000 appeared to alleviate the symptoms.

#### Morphology

The size of this living, free-swimming, *Ophryoglena* is 150-200 by 85  $\mu$ . Its shape is a constant ellipsoid, slightly more attenuated anteriorly. When burrowing in the epithelium it is capable of rounding up, and sinuating, somewhat like *Ichthyophthirius*, but its body

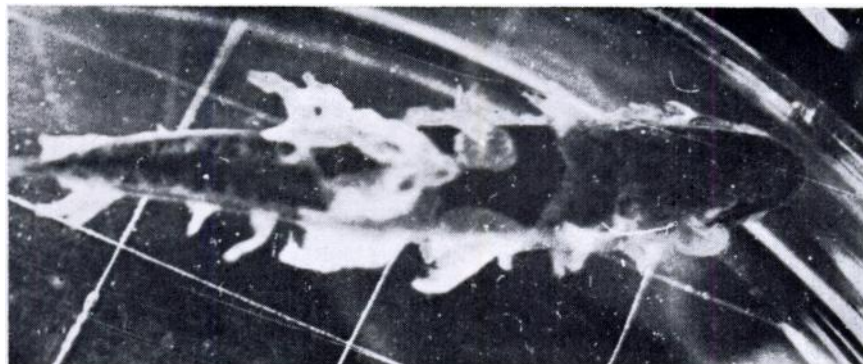


FIGURE 1. Small largemouth black bass with sloughing epithelium due to *Ophryoglena* sp.

appears to be much less plastic. The ciliates are opaque white and, other than the constant shape, their most striking features are the very conspicuous and numerous globules, about 7 - 12  $\mu$  in diameter in the cytoplasm. The cytosome, situated about 45  $\mu$  from the anterior end, is very conspicuous, unlike that in a mature *Ichthyophthirius*. The lower edge of the cytosome is thickened, obvious, and perhaps similar to the perforatorium of *Cryptocaryon*; the cilia here are 7 to 8  $\mu$  long, whereas the body cilia are about 4  $\mu$  long. There appears to be a cylindrical membrane of some sort in the "pharynx" which can be seen pulsating (like a clapper) at times. No cytophyge was seen. The macronucleus is large and oval. The cysts are about 90-95  $\mu$  in diameter with a cyst membrane ca. 3.5  $\mu$  thick. The

conspicuous globules (food vacuoles?) are still present.

This is the first report of *Ophryoglena* parasitizing fish. Other hymenostomes reported from fish include *Ichthyophthirius multifiliis*, a serious pathogen of fish, *Glaucoma* (Hoffman, Parasites of North American Freshwater Fishes, Univ. Calif. Press, 1967, in press) and *Tetrahymena* from European fish (Bykhovskaya-Pavlovskaya *et al.*, Key to Parasites of Freshwater Fish of the U. S.S.R., Eng. transl. TT64-11040, U.S. Dept. Commerce, 1964) and the sea-horse (Moewus, L., J. Protozool. 9, Suppl.: 13, 1962).

GLENN L. HOFFMAN

Eastern Fish Disease Laboratory  
U. S. Bureau of Sport Fisheries and Wildlife  
Leetown (P.O. Kearneysville), W. Va. 25430  
12 May, 1967

**PARASITES OF THE BLACK-BILLED  
MAGPIE, *Pica pica hudsonia* (Sabine, 1823)  
FROM NORTHERN UTAH**

During March and May 1965, 14 Black-billed Magpies, *Pica pica hudsonia* (Sabine, 1823), were collected near Logan, Cache County, Utah. Of these, 11 (6 males and 5 females) were adults, and three were nestlings of undetermined sex approximately 3 weeks old. Within 24 hours after collection the intestinal

tract was removed, placed in saline solution, and opened along its entire length. The wall of the intestine and the intestinal contents were examined with a dissecting microscope for helminths. Nematodes were fixed in hot glycerine-alcohol and cleared in glycerine. Flatworms and acanthocephalans were fixed in AFA solution and stained with acetorcein or Harris' hematoxylin. Contents of the large intestine were examined by