



## **Lesions Associated with Infestation of a Yellow-footed Rock Wallaby (*Petrogale xanthopus xanthopus*) with Larvae of *Odontacarus (Leogonius) adelaideae* (Womersley) (Acarina: Trombiculidae) in South Australia**

Authors: O'Callaghan, Michael G., Carmichael, Ian H., Finnie, John W., and Conaghty, Sue

Source: Journal of Wildlife Diseases, 30(2) : 257-259

Published By: Wildlife Disease Association

URL: <https://doi.org/10.7589/0090-3558-30.2.257>

---

BioOne Complete ([complete.BioOne.org](https://complete.BioOne.org)) is a full-text database of 200 subscribed and open-access titles in the biological, ecological, and environmental sciences published by nonprofit societies, associations, museums, institutions, and presses.

Your use of this PDF, the BioOne Complete website, and all posted and associated content indicates your acceptance of BioOne's Terms of Use, available at [www.bioone.org/terms-of-use](https://www.bioone.org/terms-of-use).

Usage of BioOne Complete content is strictly limited to personal, educational, and non - commercial use. Commercial inquiries or rights and permissions requests should be directed to the individual publisher as copyright holder.

---

BioOne sees sustainable scholarly publishing as an inherently collaborative enterprise connecting authors, nonprofit publishers, academic institutions, research libraries, and research funders in the common goal of maximizing access to critical research.

## Lesions Associated with Infestation of a Yellow-footed Rock Wallaby (*Petrogale xanthopus xanthopus*) with Larvae of *Odontacarus (Leogonius) adelaideae* (Womersley) (Acarina: Trombiculidae) in South Australia

Michael G. O'Callaghan,<sup>1</sup> Ian H. Carmichael,<sup>1</sup> John W. Finnie,<sup>1</sup> and Sue Conaghty,<sup>2</sup> <sup>1</sup> Department of Primary Industries, Central Veterinary Laboratories, G.P.O. Box 1671, Adelaide, South Australia 5001, Australia; <sup>2</sup> Adelaide Zoological Gardens, Frome Road, Adelaide, South Australia 5000, Australia

**ABSTRACT:** Dermatitis associated with natural infestation of a yellow-footed rock wallaby (*Petrogale xanthopus xanthopus*) with larvae of the chigger mite, *Odontacarus (Leogonius) adelaideae* is described. This record extends the known host range of *O. adelaideae* and is the first from a native animal in southern Australia.

**Key words:** *Odontacarus adelaideae*, Trombiculidae, Leeuwenhoeikiinae, chiggers, dermatitis, yellow-footed rock wallaby, *Petrogale xanthopus xanthopus*.

The larval instars of numerous mite species of the family Trombiculidae, collectively known as chiggers or scrub-itch mites, have been found on a diverse range of Australian free-living mammals, introduced mammals, and humans (Domrow and Lester, 1985). The nymphs and adults of scrub itch-mites are free-living; only the larval stages are parasitic. Most species are associated with specific habitats rather than with hosts and will attach to the first available animal within that preferred habitat; others are selective and favor certain animal classes such as lizards or birds, or particular species (Domrow, 1962, 1967; Domrow and Lester, 1985). Four species belonging to the subfamily Leeuwenhoeikiinae have been recovered from native and introduced mammals in Australia. *Odontacarus echidnus* has been reported on an echidna (*Tachyglossus aculeatus*) from the Atherton Tableland, Queensland (Womersley, 1944). *Odontacarus australiensis* has been reported from unspecified bandicoots in Cairns, Little Mulgrave, and Brisbane, Queensland (Womersley, 1944); dogs and cats in Sydney (Seddon, 1967); and unspecified wallabies, most probably the agile wallaby (*Macropus agilis*) in the

Gulf country, Queensland (Seddon, 1967). *Odontacarus adelaideae* has been recovered from cats (Adelaide, South Australia) and an unspecified rat species (Cairns) (Womersley, 1934, 1944); eastern grey kangaroo (*Macropus giganteus*), red kangaroo (*M. rufus*), sheep and feral pigs from Clermont, Queensland (Gill et al., 1945). *Odontacarus cooki* has been reported on a cat from Trinity Bay, Queensland (Southcott, 1957). In addition, Domrow (1962) recovered large numbers of an unidentified *Odontacarus* sp. from several small native rodent and marsupial species near Innisfail, Queensland.

Although occasionally found clustered on any part of the body (Domrow, 1962), the preferred site of *Odontacarus* spp. in most hosts is the internal surface and margins of the ears (Seddon, 1967). *Odontacarus adelaideae* has been collected frequently from cats in Adelaide (Southcott, 1989) and can cause intense local irritation in that host with the development of discrete crusted lesions superseded by moist ulcerated areas after mites have been shed (Prescott, 1984). There are, however, no records of *O. adelaideae* in wildlife in southern Australia nor reports of pathology caused by naturally acquired *Odontacarus* spp. infestations in hosts other than the cat. We describe dermatitis on a macropodid host infested with *O. adelaideae*.

On 11 February 1993, a mature male yellow-footed rock wallaby (*Petrogale xanthopus xanthopus*), captured in its natural habitat at Buckaringa Gorge (32°20'S, 138°0'E) near Quorn in the Flinders Ranges, South Australia, was transported to the

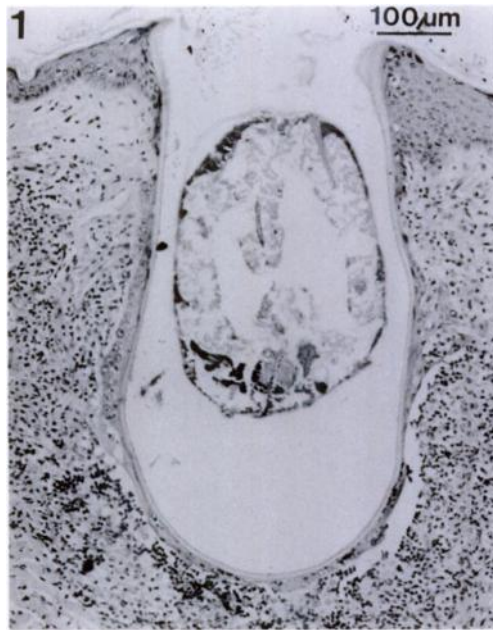

FIGURE 1. Section of skin of a yellow-footed rock wallaby showing a larval mite located in the lumen of the capsular invagination formed during feeding. H&E.

Adelaide Zoological Gardens, where it was noticed to be suffering from an extensive moist, pustular dermatitis affecting the inguinal, abdominal and axillary regions. We observed clusters of mites on the external pinnae and collected specimens for identification. Subsequently, on 26 February a skin scraping was taken from the right, medial inguinal area and six mites were recovered. The mites collected from both sites were confirmed to be larval instars of *O. adelaideae* according to the descriptions of Southcott (1989). An occasional louse, identified as *Heterodoxus ampullatus* according to the description of von Kéler (1971) was observed free in the body hair. As far as we can ascertain this is the first record of lice on this host; however, Clay (1981) depicts *H. ampullatus* from an unspecified species of rock wallaby at Bindina Springs in South Australia but does not provide supporting comment in the text. Representative specimens of the two parasite species have been deposited with the South Australian Museum (Adelaide,

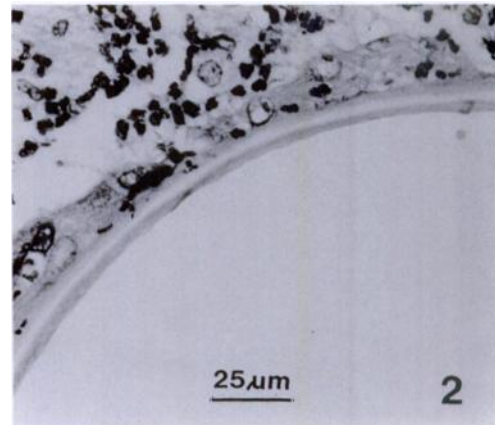


FIGURE 2. Hyaline stylostome lining an invagination of the skin at the site of attachment of a larval mite. Note the cellular infiltration of the dermis in response to the presence of the mite. H&E.

South Australia); accession number N199379 for *O. adelaideae* and *H. ampullatus* as K1424/93.

A cutaneous biopsy was taken from the perimeter of an inguinal lesion for histopathological examination. The biopsy was fixed in 10% buffered formalin, embedded in paraffin and 5  $\mu$ m sections were stained with hematoxylin and eosin. Microscopically, mites were found in invaginations of the epidermis. The infolded, attenuated epidermis was lined by a laminated, eosinophilic to hyaline membrane (stylostome), with a mite located in the lumen (Figs. 1, 2). The dermis surrounding the stylostome was heavily infiltrated by polymorphonuclear leucocytes, predominantly eosinophils, and mononuclear cells, mainly macrophages with fewer lymphocytes and plasma cells. Epidermis, away from the immediate location of the mite, had mild acanthosis and orthokeratotic hyperkeratosis.

Production of a capsular invagination of the epidermis is not uncommon in chigger mite infestations and has been described for the trombiculid genus *Guntherana* spp. in bandicoots (Domrow, 1960). The hyaline secretion of the stylostome extends backwards around the body of the larval mite and enlarges as it penetrates and feeds.

During engorgement by the mites, an intense pruritic dermatitis often develops which is considered to be an allergic reaction to the salivary secretions of the parasite (Nutting, 1984).

It is interesting, however, that *O. australiensis* and *O. adelaideae* have not been reported to cause dermatitis on the macropodid hosts from which they have thus far been recovered, namely wallabies and red and grey kangaroos, respectively. In contrast, heavy infestations of the grey kangaroo with the related trombiculid mite, *Trombicula sarcina* cause shallow crater-like ulcerations on the inner surface of the thighs in which hundreds of mites accumulate; despite this, there is no biting or rubbing of the affected areas whereas *T. sarcina* infestations in humans and sheep stimulate intense irritation (Gill et al., 1945). The clinical severity of chigger infestations in macropods probably relates to both absolute numbers of mites and host species sensitivity.

The skin lesions in the affected wallaby gradually resolved over a 10-wk-period without treatment and another rock wallaby in close contact with it did not become infested or develop dermatitis. The clinical case reported here extends the known natural host range and the geographical distribution of *O. adelaideae* infestations on Australian native animals and identifies the pathogenicity of this parasite on a macropodid host.

#### LITERATURE CITED

- CLAY, T. 1981. A report on a collection of lice (Boopidae: Phthiraptera) on *Petrogale* rock wallabies. *Proceedings of the Linnean Society of New South Wales* 105: 65–78.
- DOMROW, R. 1960. The genus *Guntherana* (Acarina: Trombiculidae). *Pacific Insects* 2: 195–237.
- . 1962. Mammals of Innisfail. II. Their mite parasites. *Australian Journal of Zoology* 10: 268–306.
- . 1967. Mite parasites of small mammals from scrub typhus foci in Australia. *Australian Journal of Zoology* 15: 759–798.
- , AND L. N. LESTER. 1985. Chiggers of Australia (Acari: Trombiculidae): An annotated checklist, keys and bibliography. *Australian Journal of Zoology, Supplementary Series*, No. 114, CSIRO, Melbourne, Australia, pp. 1–111.
- GILL, D. A., G. R. MOULE, AND R. F. RIEK. 1945. Trombidiosis of sheep in Queensland. *Australian Veterinary Journal* 21: 22–31.
- NUTTING, W. B. 1984. Mammalian diseases and arachnids, Vol. II. CRC Press Inc., Boca Raton, Florida, pp. 203–204.
- PRESCOTT, C. W. 1984. Parasitic diseases of the cat in Australia. *Veterinary Review* No. 24. University of Sydney, Post-graduate Foundation in Veterinary Science, Sydney South, New South Wales, Australia, p. 68.
- SEDDON, H. R. 1967. Arthropod infestations. Diseases of domestic animals in Australia, Part 3. Commonwealth Department of Health, Canberra, Australia, pp. 130–131.
- SOUTHCOTT, R. V. 1957. The genus *Acomatacarus* (Acarina: Trombiculidae) I. Description of three new species from Trinity Bay, north Queensland. *Transactions of the Royal Society of South Australia* 80: 146–155.
- . 1989. The larva and nymph instars of *Odontacarus* (*Leogontius*) *adelaideae* (Womersley) (Acarina: Trombiculidae: Leeuwenhoekinae). *Transactions of the Royal Society of South Australia* 113: 35–45.
- VON KÉLER, S. 1971. A revision of the Australian Boopidae (Insecta: Phthiraptera) with notes on the Trimenoponidae. *Australian Journal of Zoology, Supplementary Series*, No. 6, CSIRO, Melbourne, Australia, pp. 1–126.
- WOMERSLEY, H. 1934. A revision of the trombid and erythraeid mites of Australia with descriptions of new genera and species. *Records of the South Australian Museum* 5: 179–254.
- . 1944. Notes on and additions to the Trombiculinae and Leeuwenhoekinae (Acarina) of Australia and New Guinea. *Transactions of the Royal Society of South Australia* 68: 82–112.

Received for publication 8 September 1993.