BioOne COMPLETE

SARCOPTIC MANGE IN WILD RUMINANTS IN ZOOLOGICAL GARDENS IN ISRAEL

Authors: Yeruham, I., Rosen, S., Hadani, A., and Nyska, A.

Source: Journal of Wildlife Diseases, 32(1) : 57-61

Published By: Wildlife Disease Association

URL: https://doi.org/10.7589/0090-3558-32.1.57

BioOne Complete (complete.BioOne.org) is a full-text database of 200 subscribed and open-access titles in the biological, ecological, and environmental sciences published by nonprofit societies, associations, museums, institutions, and presses.

Your use of this PDF, the BioOne Complete website, and all posted and associated content indicates your acceptance of BioOne's Terms of Use, available at www.bioone.org/terms-of-use.

Usage of BioOne Complete content is strictly limited to personal, educational, and non - commercial use. Commercial inquiries or rights and permissions requests should be directed to the individual publisher as copyright holder.

BioOne sees sustainable scholarly publishing as an inherently collaborative enterprise connecting authors, nonprofit publishers, academic institutions, research libraries, and research funders in the common goal of maximizing access to critical research.

Downloaded From: https://complete.bioone.org/journals/Journal-of-Wildlife-Diseases on 27 Apr 2024
Terms of Use: https://complete.bioone.org/terms-of-use

Journal of Wildlife Diseases, 32(1), 1996, pp. 57–61
© Wildlife Disease Association 1996

SARCOPTIC MANGE IN WILD RUMINANTS IN ZOOLOGICAL GARDENS IN ISRAEL

I. Yeruham,[1] S. Rosen,[2] A. Hadani,[2] and A. Nyska[2]

[1] Hachaklait, Gedera and the Koret School of Veterinary Medicine, The Hebrew University of Jerusalem, Bet-Dagan 50250, Israel.

[2] The Kimron Veterinary Institute, Bet-Dagan and the Koret School of Veterinary Medicine, The Hebrew University of Jerusalem, Bet-Dagan, 50250, Israel.

ABSTRACT: Sarcoptic mange (*Sarcoptes scabiei*) occurred among wild ruminant species in five zoological gardens in Israel, from 1984 to 1994. Infestation of five ruminants by *S. scabiei* is reported for the first time: mountain gazelles (*Gazella gazella*), Nubian ibexes (*Capra ibex nubiana*), a barbary sheep (*Ammotragus lervia*), elands (*Taurotragus oryx*), and an Arabian oryx (*Oryx leucoryx*). All animals in the herds were administered ivermectin orally at a dose of 200 μg/kg body weight daily for 3 consecutive days. This was repeated three times at 2-wk intervals. The disease was eradicated in four small zoos, whereas in the biggest zoo, only control was achieved. Mortality among animals <4 mo and >8-yr-old animals composed 65% of mortality among all age classes.

Key words: *Sarcoptes scabiei*, wild ruminants.

INTRODUCTION

Sarcoptic mange, or scabies, is a highly contagious parasitic skin disease caused by *Sarcoptes scabiei*. *Sarcoptes scabiei* is a ubiquitous mite which infects domestic and wild animals, as well as humans (Fain, 1968, 1978).

The disease usually is a problem among herds, rather than being confined to single animals (Fain, 1978). Sarcoptic mange in severely affected animals may cause loss of condition and even death.

We report epizootics of sarcoptic mange among wild ruminants of five zoological gardens in Israel, and the results of an oral treatment with ivermectin.

MATERIALS AND METHODS

The survey was conducted in five zoological gardens, labelled A to E, each with two to eight species of wild ruminants (Table 1). All animals were free-roaming, with the possibility of direct contact. Mountain gazelles and Nubian ibexes, the only wild ruminants abundant in the Middle East, were found at each zoological garden.

Animals were examined following imobilization with 0.022 mg/kg large animal Imobilon® (Reckitt and Colman; C-vet, Ltd. Suffolk, United Kingdom) using a G.U.T. 50 Universal Gas-applicator (Telinject, Romerberg, Germany). Seventeen animals severely affected with sarcoptic mange were euthanized with 10 mg/100 kg T-61 (American Hoechst Corp., Somerville, New Jersey, USA). Another 90 severely infested animals died and were examined as well. Age was estimated, based on growth rings on the horns, tooth eruption and wear, and body size (Prof. Mendelssohn, Department of Zoology, University of Tel-Aviv, pers. comm.).

Skin scrapings came from 40 clinically affected animals: three from mountain gazelles, 13 from Thompson's gazelles, nine from Nubian ibexes, one from a Barbary sheep, three from gnus, 10 from elands, and one from an Arabian oryx. Scrapings were taken with a curette, dissolved in 90% lactic acid (Riedel-deHaen, Seelze, Germany) and examined microscopically. Punch biopsies from the same animals were fixed in 10% buffered formaldehyde. After dehydration and embedding of the tissue in paraffin wax, 4 μm sections were cut and stained with hematoxylin and eosin (H&E). The paraffin blocks and slides have been deposited in the archives of the Department of Pathology, Kimron Veterinary Institute, Bet-Dagan, Israel. Mites were identified based on Fain's (1968) descriptions.

All animals in the herd were treated orally with ivermectin (IVOMEC 1% w/v - MSD AGVET, Merck & Co., Inc., Rahway, New Jersey) at a dose of 200 μg/kg body weight daily for three consecutive days. Treatment was repeated three times, at 2-wk intervals. Propylene glycol (Vitamed, Benyamina, Israel) was used as a diluent for the ivermectin (10:1, v:v) and mixed with the animals' feed concentrate.

RESULTS

Visible signs of infestation included progressive dermatitis, alopecia, keratinization, skin thickening and wrinkling (Figs.

Downloaded From: https://complete.bioone.org/journals/Journal-of-Wildlife-Diseases on 27 Apr 2024
Terms of Use: https://complete.bioone.org/terms-of-use

TABLE 1. Morbidity and mortality among wild ruminants due to *Sarcoptes scabiei*, at five zoological gardens in Israel.

Locality	Density (animals/hectare)	Date of study	Parasite accession numbers	Mountain gazelle (*Gazella gazella*)	Thompson's gazelle (*Gazella thompsoni*)	Nubian ibex (*Capra ibex nubiana*)	Barbary sheep (*Ammotragus lervia*)	Gnu (*Connochaetes taurinus*)	Eland (*Taurotragus oryx*)	Arabian oryx (*Oryx leucoryx*)
A. Ramat-Gan	2.4	November 1984 to December 1987	15,620/84	0/8[a]	60/180	20/60	0/8	3/25	15/75	NP[b]
B. Kfar-Aza	1.2	February 1986 to July 1986	3,521/86	NP	NP	NP	NP	NP	NP	1/2
C. Nezer-Sereni	1.8	March 1987 to August 1989	4,563/89	1/4	NP	0/4	NP	NP	NP	NP
D. Hafez-Haim	5.1	September 1982 to March 1993	18,874/92	NP	NP	NP	1/8	NP	NP	NP
E. Kfar-Eziom	8	December 1990 to June 1991	16,521/90	2/24	NP	4/26	NP	NP	NP	NP

[a] Number of animals that died/number of animals infected.
[b] NP, no member of this species present.

FIGURE 1. Thick, fissured, lichenified, and crusted skin extending all over the body surface of a Barbary sheep due to *Sarcoptes scabiei*.

1 and 2), intense itching, and marked loss of condition, often ending in death (107 animals died). Two attendants in zoological garden A also became infected with scabies.

Defassa waterbuck (*Kobus ellipsiprymnus aldolfi-friderici*) was not found infested with sarcoptic mange (zoos A, B and D). The highest mortality rates were recorded among Thompson's gazelles and Nubian ibexes (Table 1).

Of the 107 animals that died, 70 (65%) were young (4 mo to 1 yr) or old (>8 yr) (Thompson's gazelles, mountain gazelles, white-bearded gnus, elands, Nubian ibexes and barbary sheep). Only 12 of the 107 cases were observed in the zoological gardens during the hot season (April to October).

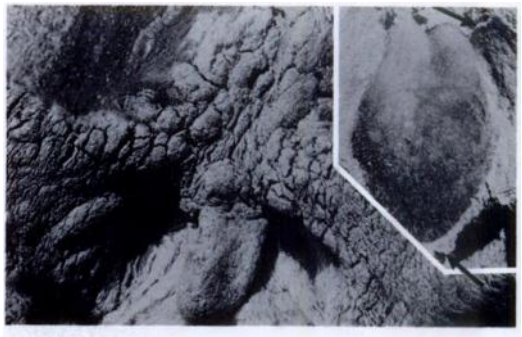

FIGURE 2. Perineal and scrotal skin of the animal in Figure 1. Note fissuring of the thickened skin. Insert is a close-up of the scrotal area, with exfoliation (arrows) of the affected skin.

Downloaded From: https://complete.bioone.org/journals/Journal-of-Wildlife-Diseases on 27 Apr 2024
Terms of Use: https://complete.bioone.org/terms-of-use

FIGURE 3. Histologic section of a skin biopsy taken from a Barbary sheep. Note the epidermal hyperplasia and hyperkeratosis associated with burrowing *S. scabiei* mites. Bar = 15 μm.

During the survey period, 10 hedgehogs, eight *Erinaceus europaeus* and two *Hemiechinus auritus*, also were examined in zoological garden A. Seven *E. europaeus* and one *H. auritus* were infested with sarcoptic mange mites.

All mites isolated from the skin scrapings of the affected animals were identified as *S. scabiei* and deposited (accession number 18992/92) at the entomological collection of the Parasitology Division, Kimron Veterinary Institute, Bet-Dagan, Israel.

All infected ruminants had an acute perivascular dermatitis. The epidermis was multifocally eroded, associated with marked epidermal hyperplasia and prominent elongation of rete ridges. There was marked parakerathotic, hyperkerathotic, and epidermal spongiosis.

Superficially, a tenacious, thickly encrusted exudate was present. Within the epidermal and keratin layers numerous sections of mites were noted, associated with bacterial colonies. The superficial dermis was moderately infiltrated by polymorph-nuclear inflammatory cells, while the adjacent blood vessels were prominently congested with a perivascular mononuclear infiltrate (accession number 18874/92 at the Kimron Veterinary Institute) (Fig. 3).

The disease was eradicated in three of the gardens after a single set of treatments, while in the fourth garden (D) two series of treatments, 3 mo apart, were necessary. In the fifth garden (A), sarcoptic mange condition significantly improved, but new cases still occurred, and the animals are still treated two to three times yearly.

Following treatment, there was a marked improvement of the skin lesions and body condition. Mites disappeared from skin scrapings.

DISCUSSION

Based on our findings, we believe that sarcoptic mange is enzootic in many wild ruminants in captivity and can periodically become epizootic.

Repeated reinfection of the animals in zoological garden A may have originated either from sub-clinically infested ruminants or from infested hedgehogs which were found abundantly in the same area. In this case, we considered hedgehogs as a reservoir of sarcoptic mange that rendered eradication of the parasite in the ruminants almost impossible.

Sarcoptic mites most commonly spread among animals by direct contact (Kral and Schwartzman, 1964). Rubbing against objects in the corrals or pasture to relieve the pruritus induced by the mites, also may have contributed to the dissemination of mange in the herds. The high density of the animal populations also may have facilitated spread of the mites. All life stages of *S. scabiei* may survive in the host's environment for days and even weeks, depending on relative humidity and temperature (Arlian et al., 1989). Gerasimoff (1953, cited in Andrews, 1983) claimed that even transmission of sarcoptic mites by flies is possible. Cross-infestivity of *S. scabiei* occurs between several species of herbivores (Arlian et al., 1988; Abu Samra et al., 1985; Ibrahim and Abu Samra, 1987).

Severe sarcoptic mange in humans generally occurs in immunodepressed individuals (Fain, 1978). The fact that most (65%) victims of mange in this study were either young (<1 yr) or old (>8 yr) may be be-

Downloaded From: https://complete.bioone.org/journals/Journal-of-Wildlife-Diseases on 27 Apr 2024
Terms of Use: https://complete.bioone.org/terms-of-use

cause those animals had low resistance to the parasite.

The *Sarcoptes* sp. mites examined from the different host species in this survey were morphologically indistinguishable. Fain (1968, 1978) concluded that there is only a single, highly variable species, *S. scabiei*. Other authors consider some strains to be distinct species (Kutzer and Onderscheka, 1966; Kutzer, 1970). All wild ruminant species reported in this study, apart from Thompson's gazelle, are described here for the first time as hosts of sarcoptic mange.

The marked seasonality (November to March) of the occurrence of sarcoptic mange observed here has been described by Christophersen (1986). The favorable climate conditions during the winter months for all life stages (Arlian et al., 1989) probably increased the mite population considerably.

Ivermectin has been reported as a highly potent, broad-spectrum, and systemic antiparasitic drug (Campbell, 1985). Its efficacy is related not only to the dose, but also to its formulation and route of administration. In cattle, for example, ivermectin administered orally at 200 μg/kg body weight was not effective against scabies (Meleney, 1982). Kutzer (1989) reported the successful treatment of wild boars (*Sus scrofa*) with ivermectin at a dose of 500 μg/kg body weight administered with the feed twice at a fortnight's interval. In wild ruminants, oral ivermectin treatment is preferable to that of ivermectin-containing gelatin bullets because the capture of wild ruminants with a net or the use of tranquilizing darts dipped in insecticide or injected with ivermectin is dangerous (Meleny et al., 1980).

In four zoological gardens, the treated animals fully recovered and mites were not found in their skin scrapings. In the fifth garden (A), a marked improved was achieved and new cases seldom occurred. Based on our study, oral treatment with ivermectin at the recommended dose and timetable was effective, even in severe clinical cases of sarcoptic mange.

The short time interval between the treatment sets (14 days) ensured that the mites could not reproduce between treatments. In this way the life cycle of the mites was disrupted.

Defassa waterbuck were not found to be clinically infested with mange. Thus, waterbucks might be less susceptible to this mite. However, differences in susceptibility to sarcoptic mange among different species of wild ruminants are not mentioned in the literature. According to our findings, Thompson's gazelles and Nubian ibexes seemed to be highly susceptible to sarcoptic mange.

A better understanding of the factors affecting the host and mite relationship, and particularly the population dynamics and seasonality of *S. scabiei* in wild ruminants kept in captivity, would facilitate disease control. More intensive experimental work is required to study the pathogenicity, pathogenesis and epizootiological significance of sarcoptic mange in wild ruminants.

LITERATURE CITED

ABU-SAMRA, M. T., B. H. ALI, B. E. MUSA, AND K. E. E. IBRAHIM. 1985. Experimental infection of domestic donkey (*Equus asinus asinus*) with a goat strain of *Sarcoptes scabiei* and treatment with ivermectin. Acta Tropica 42: 217–224.

ANDREWS, J. R. H. 1983. The origin and evolution of host associations of *Sarcoptes scabiei* and the Subfamily Sarcoptinae Murray. Acarologia 24: 85–94.

ARLIAN, L. G., D. L. VYSZENSKI-MOHER, AND D. CORDOVA. 1988. Host specificity of *Sarcoptes scabiei* var. canis (Acari: Sarcoptidae) and the role of host odor. Journal of Medical Entomology 25: 52–56.

———, ———, AND M. J. POLE. 1989. Survival of adults and developmental stages of *Sarcoptes scabiei* var. canis when off the host. Experimental and Applied Acarology 6: 181–187.

CAMPBELL, W. C. 1985. Ivermectin, an update. Parasitology Today 1: 10–16.

CHRISTOPHERSEN, J. 1986. Epidemiology of scabies. Parasitology Today 2: 247–248.

FAIN, A. 1968. Etude de la variabilite de *Sarcoptes scabiei* avec une revision des Sarcoptidae. Acta Zoology Pathology Antverpen 47: 1–196.

Downloaded From: https://complete.bioone.org/journals/Journal-of-Wildlife-Diseases on 27 Apr 2024
Terms of Use: https://complete.bioone.org/terms-of-use

———. 1978. Epidemiological problems of scabies. International Journal of Dermatology 17: 20–30.

GERASIMOFF, YU. A. 1953. Zudnevaya chesotka dikikh lisits. Voprosy Biologii Pushnykh Zverey 13: 16.

IBRAHIM, K. E., AND M. T. ABU-SAMRA. 1987. Experimental transmission of a goat strain of *Sarcoptes scabiei* to desert sheep and its treatment with ivermectin. Veterinary Parasitology 26: 157–164.

KRAL, F., AND R. M. SCHWARTZMAN. 1964. Veterinary and comperative dermatology, J. B. Lippincott Company, Philadelphia, Pennsylvania, pp. 343–368.

KUTZER, E. 1970. Merkblätter über angewandte Parasitenkunde und Schädlingsbekampfung. *Sarcoptes* Milben und Sarcoptesraude der Haustiere. Angewandete Parasitologie 11: 1–22.

———. 1989. Zur Tilgung der Sarcoptesräude bei wild und Hausschweinen mit Ivermectin (Ivomec). Der Praktische Tierarzt 10: 44–46.

———, AND W. ONDERSCHEKA. 1966. Die Räude der Gemse und ihre Bekampfung. Zeitschrift für Jagdwissenschaft 12: 63–84.

MELENEY, W. P. 1982. Control of psoroptic scabies on calves with ivermectin. American Journal of Veterinary Research 43: 329–331.

———, F. C. WRIGHT, AND F. S. GUILLOT. 1980. Identification and control of psoroptic scabies in bighorn sheep (*Ovis canadensis mexicana*). Proceedings of the United States Animal Health Association 84: 403–407.

Received for publication 23 December 1994.

Downloaded From: https://complete.bioone.org/journals/Journal-of-Wildlife-Diseases on 27 Apr 2024
Terms of Use: https://complete.bioone.org/terms-of-use