

EUROPEAN BROWN HARE SYNDROME IN FREE-RANGING HARES IN POLAND

Authors: Frölich, Kai, Meyer, Heinrich H. D., Pielowski, Zygmunt, Ronsholt, Leif, Seck-Lanzendorf, S. v., et al.

Source: Journal of Wildlife Diseases, 32(2) : 280-285

Published By: Wildlife Disease Association

URL: <https://doi.org/10.7589/0090-3558-32.2.280>

The BioOne Digital Library (<https://bioone.org/>) provides worldwide distribution for more than 580 journals and eBooks from BioOne's community of over 150 nonprofit societies, research institutions, and university presses in the biological, ecological, and environmental sciences. The BioOne Digital Library encompasses the flagship aggregation BioOne Complete (<https://bioone.org/subscribe>), the BioOne Complete Archive (<https://bioone.org/archive>), and the BioOne eBooks program offerings ESA eBook Collection (<https://bioone.org/esa-ebooks>) and CSIRO Publishing BioSelect Collection (<https://bioone.org/csiro-ebooks>).

Your use of this PDF, the BioOne Digital Library, and all posted and associated content indicates your acceptance of BioOne's Terms of Use, available at www.bioone.org/terms-of-use.

Usage of BioOne Digital Library content is strictly limited to personal, educational, and non-commercial use. Commercial inquiries or rights and permissions requests should be directed to the individual publisher as copyright holder.

BioOne is an innovative nonprofit that sees sustainable scholarly publishing as an inherently collaborative enterprise connecting authors, nonprofit publishers, academic institutions, research libraries, and research funders in the common goal of maximizing access to critical research.

EUROPEAN BROWN HARE SYNDROME IN FREE-RANGING HARES IN POLAND

Kai Frölich,¹ Heinrich H. D. Meyer,¹ Zygmunt Pielowski,² Leif Ronsholt,³
S. v. Seck-Lanzendorf,¹ and Manuela Stolte¹

¹ Institute for Zoo Biology and Wildlife Research Berlin, P.O. Box 1103, 10252, Berlin, Germany

² Polish Hunting Association Research Station, PI-62055 Czempin, ul. Sokolnicza 11

³ State Veterinary Institute for Virus Research, Lindholm, 4771 Kalvehave, Denmark

ABSTRACT: A study of European brown hare syndrome (EBHS) was conducted in Poland (Czempin). From April 1993 until February 1994, 100 blood and 78 spleen samples of European brown hares (*Lepus europaeus*) were tested for prevalence of EBHS and rabbit hemorrhagic disease (RHDV) antibodies and EBHS virus antigen with two enzyme-linked immunosorbent assay (ELISA) test kits. Thirty-eight of 100 serum samples were positive for EBHS, and six (7.6%) of 78 of the spleen materials were antigen positive for EBHS virus. Three (3%) of the sera were positive against RHDV, whereas two of these also were seropositive for EBHSV. European brown hare syndrome virus seropositive hares were most frequently found from April to September. Based on negative staining electron microscopy investigations of liver and spleen homogenates of all antigen-positive hares, we observed caliciviruses in only one animal. For histopathological investigations organ specimens were available from 98 hares. Histopathological findings corresponded with the clinical picture of chronic EBHS. A pathohistological picture consistent with EBHS was found in 22 (22%) of investigated hares and corresponded in 50% of the animals which reacted positively in the EBHSV antigen-ELISA and in 29% of the animals which reacted positively in the EBHSV antibody-ELISA. These results from western Poland are the first that caliciviruses are present in European brown hare population in Eastern Europe and may be one of the causes for increased mortality in the Polish hare population over the past 10 years.

Key words: Epizootiology, European brown hare syndrome, rabbit hemorrhagic disease, histopathological findings, serological survey, electron microscopy, *Lepus europaeus*, enzyme-linked immunosorbent assay, Poland.

INTRODUCTION

In 1989, Lavazza and Vecchi (1989) found viral particles by negative-staining immune electron microscopy of the liver of European brown hares which died from European brown hare syndrome (EBHS). These particles were similar to rabbit hemorrhagic disease virus (RHDV) described in China (Xu and Chen, 1989). The causative virus of EBHS is a small (30 to 35 nm) icosahedral, non-enveloped and hemagglutinating virus (Gavier-Widen and Mörner, 1991). The EBHSV and RHDV were both classified as caliciviruses (Ohlinger and Thiel, 1991).

Lagomorphs are the only animals susceptible to experimental infections with RHDV and EBHSV (Smid et al., 1991; Xu, 1991). The RHDV infection in rabbits is spread by oral and nasal transmission (Xu and Chen, 1989). This virus is present in all secretions and excretions of diseased animals (Xu, 1991). In the field, the fecal-

oral mode of transmission is probably the most important one (Morisse et al., 1991). There is no evidence of natural cross-infection with calicivirus between hares and rabbits (Gavier-Widen and Mörner, 1993). Experimental infection of hares with RHDV and, likewise, infection of rabbits with EBHSV do not induce clinical symptoms; but humoral antibodies are formed as a sign of a manifested silent infection (L. Ronsholt, unpubl.). However, for some reasons there are also reports of successful experimental cross-infection (Modugno and Nasti, 1990; Morisse et al., 1990). The clinical and pathological manifestations of EBHS and rabbit hemorrhagic disease (RHD) are remarkably similar. Principal pathological features common to EBHS and RHD are: rapid progression, mild nervous symptoms, degeneration and congestion of the liver, serohemorrhagic liquid at the nostrils, congestion of the spleen and kidneys, uncoagulated blood in the body

cavities, diffuse or petechial haemorrhages on serosa and mucosa, and occasional jaundice. Other similarities included extremely high morbidity and mortality rates and preferential susceptibility of adult animals, especially breeders, while animals below the age of 40 days remain unaffected (Capucci et al., 1991).

European brown hare syndrome has been reported in many European countries: Morisse (1988), Eskens and Volmer (1989), Marcato et al. (1989), Henriksen et al. (1989), Okerman et al. (1989), Chassey and Duff (1990), Sostaric et al. (1991), Gavier-Widen and Mörner (1993), Salmela et al. (1993), Steineck und Nowotny (1993), and Gortazar and de Luco (1995).

Since 1976, an increase in mortality of adult European brown hares (*Lepus europaeus*) has been observed in Poland (Pielowski, 1990). Our objective was to determine the occurrence of EBHS in an area of Poland where a high mortality in hares prevailed.

MATERIALS AND METHODS

Acquisition of material required close cooperation with the research station of the Polish Hunting Association at Czempin, Poland. From April 1993 to February 1994, eight to ten hares were obtained each month from local hunters. Czempin (52°09'N, 16°46'E) is located in the western part of Poland. The hunting area of 15,000 ha is almost flat and consists predominantly of large cultivated fields with some small individual farms and fruit plantations situated in the remaining part of the area. The habitat is sparsely wooded and there are few lakes, ponds, or brooklets.

In this study, we got samples from 100 hunted hares (55 males, 45 females) of which 100 blood samples were available, which were serologically tested for specific antibodies to EBHSV and RHDV. Moreover, 78 spleens were available, which were tested for EBHSV- and RHDV antigen. In addition, we investigated 98 hares by pathohistological methods; specimens were not available from two hares. Eighty-eight livers, 80 kidneys, 78 spleens, 83 brains, 80 intestines, 79 lungs, 57 thyroid glands, 67 adrenal glands, and 41 pancreases were available for histopathological investigations.

Immediately after hunting, the organ material which had remained completely intact was

removed, and cooled to 0 C on broken ice, and transported to Berlin; all necessary processing in our laboratory lasted less than one day.

After centrifugation, serum samples were inactivated at 56 C for 30 min and stored at -20 C. Spleen samples were stored at -70 C, homogenized, and centrifuged before being tested for the presence of EBHSV antigen.

We used European brown hare syndrome virus and rabbit hemorrhagic disease virus antigens- and antibody-blocking ELISA test kits according to the directions of the manufacturer (Danish Veterinary Institute for Virus Research; DVIVR). The two ELISA systems differentiated between the material from EBHSV and RHDV infections. The detection of the virus was done by an EBHSV antigen ELISA. Briefly, the EBHSV antigen ELISA microplates (Maxisorp, Nunc- Roskilde, Denmark) were coated with rabbit anti-EBHSV immunoglobulin G (IgG), washed, and the supernatant from the test material or dilutions hereof were analyzed as quadruplicates. European brown hare syndrome virus-positive (Bundesforschungsanstalt für Viruskkrankheiten, Tübingen, Germany) and negative control samples (Institut für Versuchstierkunde, Berlin, Germany) were included. Following an incubation period overnight at 5 C and a washing step, immunosorbent-treated guinea pig anti-EBHSV hyperimmune serum was added to two of the wells, and the same concentration of normal guinea pig serum to the other two wells per test sample. Following another incubation period of 30 min at 37 C and another washing procedure, the wells were further incubated with rabbit anti-guinea pig peroxidase conjugate (Denmark code P141, DAKO Diagnostik GmbH, Hamburg, Germany). After washing, the fixed enzymes reacted for 10 min with orthophenylenediamine (OPD) substrate including perhydrol (Sigma-Chemie GmbH, Deisenhofen, Germany). The reaction was stopped with H₂SO₄ and the results were read at 490 nm on a MTF 10 spectrophotometer (Wissenschaftlicher Gerätebau, Berlin, Germany). The mean optical density (OD) of the negative controls was calculated. Test samples that deviated significantly >3 standard deviation (SD) from the mean of control sera were considered EBHSV positive.

For European brown hare syndrome and RHD antibody ELISA, the antigen ELISA test kits were used for detection of blocking antibodies against EBHSV or RHDV in a competitive assay. The investigated sera were tested in three dilution steps: 1:4, 1:10 and 1:100. Briefly, 50 µl of the diluted serum sample were added to IgG anti-RHDV or IgG anti-EBHSV pre-coated wells followed by 50 µl of the related homologous virus antigen suspension (either

EBHSV or RHDV), giving an OD value of about 1,000 with negative serum. After incubation overnight at 5 C, the procedure for the antigen ELISA again was followed. The mean OD of the negative control sera was calculated. Sera that deviated <3 SD from the mean of negative control sera were considered antibody positive.

Liver and spleen specimens of all EBHSV antigen-positive hares, frozen at -70 C, were examined by electron microscopy using the negative staining technique (Gelderblom and Özel, 1983). First, the homogenate was centrifuged at $10,000 \times G$ for 15 min to eliminate large debris. Thereafter, the supernatant was centrifuged at $135,000 \times G$ for 5 min and the sediment was placed on 400 mesh copper grids (Baltec, Walluf, Germany) covered with formvar film and coated with carbon (Plano, Marburg, Germany). Finally, the grids were negatively stained with 1% uranyl acetate (Serva, Heidelberg, Germany) and checked by a EM 902 A electron microscope (Carl Zeiss, Oberkochen, Germany).

Specimens of liver, spleen, kidney, small and large intestine, lungs, brain, adrenal gland, thyroid gland, and pancreas were fixed in 10% buffered formalin solution (pH 7.4). The tissues were then embedded in paraffin after dehydration in ethanol and sections were cut at 4 μ m. Histological examination was performed after staining with hematoxylin-eosin (HE) for light microscopy (Axioplan, Carl Zeiss, Oberkochen, Germany). The histological samples were considered positive for EBHS or RHDV if at least one of the following criteria was detected: predominant periportal necrosis and degeneration of the hepatocytes characterized by single, group, and mass cell necrosis, karyorrhexis, karyolysis or karyopyknosis with a scattered foci of lymphohistiocytic infiltrates. The histological samples were determined to be nonspecific and questionable for EBHS or RHDV if they had only tubulonephrosis, hyperplasia of splenic follicles, necrosis of the white spleen pulp or hepatic vacuolar degeneration.

Fisher's two-tailed exact test (Freeman and Halton, 1951) was used to evaluate differences in seroprevalence or antigen prevalence between hares shot in April to September or October to February, respectively, for histologically positive and negative cases. The significance level was set at $\alpha = 0.05$.

RESULTS

European brown hare syndrome virus antibodies were present in 38 of 100 European brown hares. Of the 38 positive sera, 13 (34%) sera were positive up to a

dilution of 1:4, 22 (58%) sera up to 1:10 and three (8%) sera up to 1:100. Rabbit hemorrhagic disease antibodies were present in three of 100 European brown hares. Of these, two sera were positive up to a dilution of 1:4 (these sera were also positive for EBHSV antibodies) and one serum up to 1:10.

We detected EBHSV antigen in six (7.6%) of the 78 usable spleens. Of these, four samples were positive when diluted 1:4 and two samples were positive up to a dilution of 1:10.

We found no sex-specific differences neither in EBHSV antigen-positive nor in seropositive animals. The EBHSV-seropositive hares were obtained throughout the year but were most frequently found from April to September: 27% of the seropositive hares were found between April and September and only 11% seropositive hares were found between October and February. The differences were nearly significant ($P = 0.059$, $n = 100$). In the EBHSV antigen test, no differences between April to September and October to February were found.

A pathohistological picture related to EBHS was found in 22 (22%) hares. Of the six animals which reacted positively with the EBHSV antigen ELISA, three also had histological alterations characteristic of EBHS, two only had nonspecific alterations and one had a normal histological picture.

Of the 38 animals reacting positively in the EBHSV antibody ELISA, 11 (29%) also had characteristic histological alterations of EBHS, 12 had nonspecific alterations, while 15 hares had a normal histological picture. Of the three hares reacting positively in the RHDV antibody ELISA, no animal was histologically positive, two had nonspecific alterations and one was histologically negative. In the group of 62 hares without EBHSV antibodies, 35 had no pathohistological features while 15 samples had only nonspecific alterations. However, in 11 (18%) animals, alterations of the liver were found similar to the typ-

ical EBHS findings. No histological material was available from one of these animals.

Seventy-two hares (92%) were negative for the EBHSV antigen test. Of these, 36 (50%) did not have any histological changes while 20 specimens had nonspecific alterations. In 16 (21%) animals, alterations of the liver were found similar to typical EBHS findings. Summarizing these findings, 50% of the animals which reacted positively for the EBHSV antigen test, were also pathohistologically positive, while only 21% which reacted negatively for the EBHSV antigen test were pathohistologically positive. But these differences were not significant ($P = 0.108$, $n = 56$).

The 29% of the animals which reacted positively in the EBHSV antibody ELISA, were also pathohistologically positive, while only 18% which reacted negatively in the EBHSV antibody ELISA were pathohistologically positive. However, the differences were not significant ($P = 0.102$, $n = 70$).

Virus particles characteristic of calicivirus were found in liver and spleen homogenate in one of the six EBHSV antigen-positive hares by negative staining electron microscopy. After low centrifugation, the icosahedral particles of 30 nm diameter were seen in groups, and following high centrifugation, they occurred singly spaced. They were partially damaged during preparation, but most of them showed the characteristic cup-like depressions of the surface (Fig. 1).

DISCUSSION

These investigations done in western Poland are the first evidence that caliciviruses are present in European brown hare populations in Eastern Europe (Gortazar and de Luco, 1995). Furthermore, the study was valuable due to the simultaneous use of both histopathological and electron-microscopical methods as well as the EBHS/RHD antibody- and EBHS antigen-ELISA.

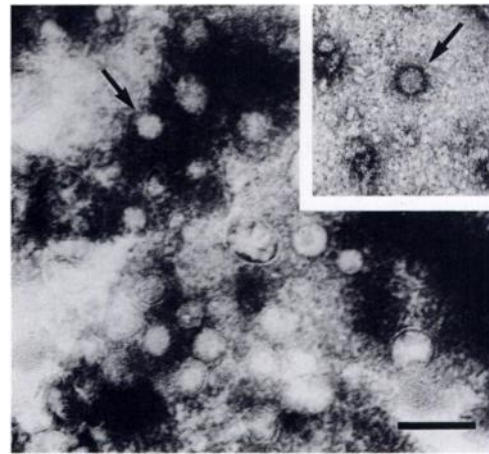


FIGURE 1. Negative electron microscope picture of a group of caliciviruses (European brown hare syndrome viruses) after low centrifugation and isolated calicivirus after high centrifugation (Bar = 150 nm).

Thirty-eight percent of the sera were positive for EBHSV antibodies. Similar antibody prevalence was found in Germany: 21% seroprevalence (Maess et al., 1991) and 23% (Stubbe et al., 1994). However, in another investigation done in Austria by Steineck und Nowotny (1993), the seroprevalence was higher (88%). As might be expected with two closely-related viruses, there was a small degree of cross-reaction between RHDV and EBHSV antibody ELISAs. Thus, two of the EBHSV antibody positive sera also had evidence of antibodies against RHDV.

European brown hare syndrome virus seropositive hares were found most frequently between April and September. Probably the survival rate of infected hares is higher from April to September than from October to February and, therefore, animals which can cope with the disease (seropositive) are observed more frequently in April to September. This may explain why the highest mortality due to EBHS was found October to February (Poli et al., 1991).

The diagnosis of calicivirus was supported by negative-staining electron microscopic images. These viral particles morphologically resembled those observed

by Poli et al. (1991) in spleen and liver of hare with acute hepatitis. We found particles by electron microscopic image in only one hare of the six antigen-positive animals. This seronegative hare was also histopathologically positive and positive in the EBHSV-antigen ELISA. Probably, this hare was seronegative, because the animal was hunted in the stage of viremia.

Similar to Marcato et al. (1991), we found the same histological alterations characteristic of EBHS in both serologically and antigen-positive, apparently healthy hares; thus in 50% of the healthy hares we detected EBHSV antigen and in 29% we detected EBHSV antibodies. Both groups had characteristic alterations corresponding to chronic hepatitis (Marcato et al., 1991). Therefore, a certain relation exists between our histological findings and the results of the ELISAs, although these relations lacked statistical evidence. Much less relation was reported by Steineck and Nowotny (1993), who found only 14% of hares with features characteristic of EBHS in a group of collected hares composed of 88% EBHS-seropositive individuals.

The prevalence of pathohistologically positive hares (22%) is in the range of other studies (Gavier-Widen and Mörner, 1993; Löliger and Eskens, 1991); however, our study was not directly comparable because these other authors investigated hares found dead. We detected no acute cases of EBHS; this is probably because our investigation only included clinically normal hares, which were shot. It is not clear why pathohistological findings indicative of infection with calicivirus were found in 10 animals which were negative for both antibody and antigen ELISA tests. However, these symptoms are not specific and may have been attributable to another chronic disease. The quantity of EBHSV antigen detected in the hares of our study was rather low compared to the amount normally found in acute EBHS cases. This seems to reflect a chronic persistent stage of infection which, from an

epizootiological point, is rather interesting and may facilitate the spreading and maintenance of the infection.

In conclusion, EBHS had a high prevalence in Poland and these caliciviruses may be one of the causes for increased mortality in this population over the past 10 yr. The ecological impact of EBHS, however, cannot be evaluated exactly in conjunction with other adverse, perhaps complementary factors like changes in habitat, agricultural techniques, and environmental pollution. This influence has been demonstrated in several other studies (Pielowski, 1990; Stubbe et al., 1994).

ACKNOWLEDGEMENTS

The authors thank Dr. Gelderblom from the Robert-Koch-Institute in Berlin for technical help in preparing the homogenate for negative staining. We also thank Ms. B. Kirsch, Ms. D. Henne and Mr. B. Paschmionka for their technical assistance.

LITERATURE CITED

- CAPUCCI, L., M. T. SCICLUNA, AND A. LAVAZZA. 1991. Diagnosis of viral hemorrhagic disease of rabbits and the European brown hare syndrome. *Revue Scientifique et Technique Office International des Epizooties* 10: 347-370.
- CHASEY, D., AND P. DUFF. 1990. European brown hare syndrome and associated virus particles in the UK. *The Veterinary Record* 126: 623-624.
- ESKENS, U., AND K. VOLMER. 1989. Untersuchungen zur Ätiologie der Leberdystrophie des Feldhasen (*Lepus europeas*, Pallas). *Deutsche Tierärztliche Wochenschrift* 96: 464-466.
- FREEMAN, G. H., AND J. H. HALTON. 1951. Note on an exact treatment of contingency goodness of fit and other problems of significance. *Biometrika* 38: 141-149.
- GAVIER-WIDEN, D., AND T. MÖRNER. 1991. Epidemiology and diagnosis of the European brown hare syndrome in Scandinavian countries: *Revue Scientifique et Technique Office International des Epizooties* 10: 453-458.
- , AND ———. 1993. Descriptive epizootiological study of European brown hare syndrome in Sweden. *Journal of Wildlife Disease* 29: 15-20.
- GELDERBLUM, H., AND M. ÖZEL. 1983. Zur Virusdiagnostik mit dem Elektronenmikroskop. *Kleintierpraxis* 28: 39-45.
- GORTAZAR, C., AND D. F. DE LUCO. 1995. La enfermedad hemorrágica de la liebre. *Trofeo* 295: 30-34.

- HENRIKSEN, P., D. GAVIER, AND F. ELLING. 1989. Acute necrotising hepatitis in Danish farmed hares. *The Veterinary Record* 125: 486–487.
- LAVAZZA, A., AND G. VECCHI. 1989. Osservazioni su alcuni episodi di mortalità nelle lepri. Evidenziazione al microscopio elettronico di una particella virale. Nota preliminare. *Selezione Veterinaria* 30: 461–467.
- LÖLIGER, H.-CH., AND U. ESKENS. 1991. Incidence, epizootology and control of viral hemorrhagic disease of rabbits and the European brown hare syndrome in Germany. *Revue Scientifique et Technique Office International des Epizooties* 10: 423–434.
- MAESS, J., V. RYLL, M. V. KEYSERLINGK, L. WENK, AND K. POHLMAYER. 1991. Untersuchungen zum Vorkommen der Rabbit Viral Hemorrhagic Disease oder serologisch verwandter Infektionserreger in der Hasen- und Wildkaninchenpopulation von Niedersachsen. *Zeitschrift für Jagdwissenschaft* 37: 49–54.
- MARCATO, P. S., C. BENAZZI, M. GALEOTTI, AND L. SALDA DELLA. 1989. Infective necrotic hepatitis of leporids. *Rivista di Coniglicultura* 26: 41–50.
- , ———, G. VECCHI, M. GALEOTTI, L. DELLA SALDA, G. SARLI, AND P. LUCIDI. 1991. Clinical and pathological features of viral hemorrhagic disease of rabbits and the European brown hare syndrome. *Revue Scientifique et Technique Office International des Epizooties* 10: 371–390.
- MODUGNO, G. D., AND R. NASTI. 1990. Viral hemorrhagic disease of rabbits in Apulia, experimental infection of rabbits and hares. *Rivista di Coniglicultura* 27: 25–32.
- MORISSE, J.-P. 1988. Hemorrhagic septicemia syndrome in rabbits: First observations in France. *Le Point Vétérinaire* 20: 79–83.
- , J. P. PICAULT, E. BOILLETOT, AND M. MORIN. 1990. Relations étiologiques entre le syndrome du lièvre brun européen (EBHS) et la maladie hémorragique virale du lapin (VHD). *Revue de Médecine Vétérinaire* 141: 463–467.
- , G. LE GALL, AND E. BOILLETOT. 1991. Hepatitis of viral origin in Leporidae: Introduction and aetiological hypotheses. *Revue Scientifique et Technique Office International des Epizooties* 10: 283–295.
- OHLINGER, V. F., AND H. J. THIEL. 1991. Identification of the viral hemorrhagic disease virus of rabbits as a calicivirus. *Revue Scientifique et Technique Office International des Epizooties* 10: 311–323.
- OKERMAN, L., P. VAN DE KERCKHOVE, S. OSAER, L. DEVRIESE, AND E. UYTTEBROEK. 1989. European brown hare syndrome in captive hares (*Lepus capensis*) in Belgium. *Vlaams Diergeneeskundig Tijdschrift* 58: 44–46.
- PIELOWSKI, Z. 1990. Über die Abhängigkeit der Besatzdichte und anderer Populationsparameter des Hasen von der Agrarstruktur und landwirtschaftlichen Aktivitäten. *Beiträge zur Jagd- und Wildtierforschung*, Band 17: 156–162.
- POLI, A., M. NIGRO, D. GALLAZZI, G. SIRONI, A. LAVAZZA, AND D. GELMETTI. 1991. Acute hepatitis in the European brown hare (*Lepus europaeus*) in Italy. *Journal of Wildlife Diseases* 27: 621–629.
- SALMELA, P., BELAK, K., AND GAVIER-WIDEN, D. 1993. The occurrence of European brown hare syndrome in Finland. *Acta Veterinaria Scandinavica* 34: 215–217.
- SMID, B., L. VALICEK, L. RODAK, J. STEPANEK, AND E. JURAK. 1991. Rabbit hemorrhagic disease: An investigation of some properties of the virus and evaluation of an inactivated vaccine. *Veterinary Microbiology* 26: 77–85.
- SOSTARIC, B., Z. LIPEJ, AND R. FUCHS. 1991. The disappearance of free living hares in Croatia: 1. European brown hare syndrome. *Veterinarski Arhiv* 61: 133–150.
- STEINECK, TH., AND N. NOWOTNY. 1993. European Brown Hare Syndrome (EBHS) in Österreich: Epizootiologische Untersuchungen. *Tierärztliche Umschau* 48: 225–229.
- STUBBE, W., I. STUBBE, M. AHRENS, AND A. FRIEDEL. 1994. Feldhasenprojekt Sachsen-Anhalt - eine Zwischenbilanz. *Unsere Jagd* 7: 8–11.
- XU, W. Y. 1991. Viral hemorrhagic disease of rabbits in the People's Republic of China: Epidemiology and virus characterisation. *Revue Scientifique et Technique Office International des Epizooties* 10: 393–408.
- XU, Z. J., AND W. X. CHEN. 1989. Viral hemorrhagic disease in rabbits: A. Review. *Veterinary Research Communications* 13: 205–212.

Received for publication 2 May 1995.