

Lymphosarcoma in a Raccoon (*Procyon lotor*)

Authors: Hamir, Amir N., Hanlon, Cathleen A., and Rupprecht, Charles E.

Source: *Journal of Wildlife Diseases*, 32(4) : 670-673

Published By: Wildlife Disease Association

URL: <https://doi.org/10.7589/0090-3558-32.4.670>

BioOne Complete (complete.BioOne.org) is a full-text database of 200 subscribed and open-access titles in the biological, ecological, and environmental sciences published by nonprofit societies, associations, museums, institutions, and presses.

Your use of this PDF, the BioOne Complete website, and all posted and associated content indicates your acceptance of BioOne's Terms of Use, available at www.bioone.org/terms-of-use.

Usage of BioOne Complete content is strictly limited to personal, educational, and non-commercial use. Commercial inquiries or rights and permissions requests should be directed to the individual publisher as copyright holder.

BioOne sees sustainable scholarly publishing as an inherently collaborative enterprise connecting authors, nonprofit publishers, academic institutions, research libraries, and research funders in the common goal of maximizing access to critical research.

Lymphosarcoma in a Raccoon (*Procyon lotor*)

Amir N. Hamir,^{1,3} Cathleen A. Hanlon,^{2,4} and Charles E. Rupprecht,^{2,5} ¹Department of Pathobiology, School of Veterinary Medicine, University of Pennsylvania, New Bolton Center, Kennett Square, Pennsylvania 19348, USA; ²Department of Microbiology and Immunology, Center for Neurovirology, Thomas Jefferson University, Philadelphia, Pennsylvania 19107, USA. Present addresses: ³College of Veterinary Medicine, Oregon State University, Magruder Hall, Corvallis, Oregon 97331, USA; ⁴New York State Department of Health, Empire State Plaza, Albany, New York 12237, USA; ⁵Centers for Disease Control and Prevention, 1600 Clifton Road, Atlanta, Georgia 30333, USA

ABSTRACT: A case of lymphosarcoma in a captive adult female raccoon (*Procyon lotor*) from northeastern Pennsylvania (USA) was observed in 1991. Prior to its death the raccoon had lost weight. At necropsy the carcass was in poor body condition and had pale mucous membranes. The thoracic and abdominal lymph nodes were enlarged, soft, and pale tan. Microscopically, there was effacement of normal lymph node architecture by sheets of mononuclear cells. These were well-differentiated small lymphocytes with distinct cell borders. Nuclei of these cells were darkly stained and mitotic figures were frequently seen. Similar but lesser numbers of neoplastic cells were seen in the parenchyma of liver, spleen, and the pancreas. Since the neoplasm involved several organs, we propose that the condition was of multicentric origin. Gross lesions, histopathologic findings and the organs involved differed from a previously described case of lymphosarcoma in a raccoon.

Key words: Lymphosarcoma, raccoon, *Procyon lotor*.

The epizootic of raccoon (*Procyon lotor*) rabies in the northeastern United States and the subsequent development and experimental evaluation of a vaccinia-rabies glycoprotein (V-RG) oral vaccine (Rupprecht et al., 1992) provided an opportunity to examine over 500 raccoons at necropsy from 1985 to 1993. Here we document a case of lymphosarcoma involving several organs of an adult raccoon.

Neoplastic lesions have infrequently been documented in the Family Procyonidae. Williams (1982) reviewed neoplasms of raccoons and found records of skin fibroma, pancreatic adenoma, thyroid adenoma/adenocarcinoma, brain astrocytoma, nasal adenocarcinoma and intestinal adenocarcinoma. However, Williams (1982) did not include four other neoplasms (adenocarcinoma of kidney, carcinoma of kid-

ney, chondroma in rib, and hemangiosarcoma in nasal orifice) listed by Kaiser (1981). Since that time, Roher and Nielsen (1984) documented a case of lymphosarcoma confined to the non-lymphoid tissues (kidney, brain, and meninges); Hamir and Rupprecht (1995) reported adrenal gland adenomas; and Hamir et al. (1995) described viral papillomatous growths on the skin of lower legs of raccoons. We now describe a case of lymphosarcoma with neoplastic involvement of lymphoid organs.

An adult female raccoon was live-trapped (Tomahawk Number 207 traps, Tomahawk Live Trap Company, Tomahawk, Wisconsin, USA), at State Game Lands Number 13 (41°18'N; 76°20'W) in northeastern Pennsylvania (USA), and kept in captivity for 8 mo as a control animal in a rabies pathogenesis/V-RG experiment. At the time of capture and during most of her time in captivity, the raccoon was in good health and appeared normal. However, during the last 4 wk she lost approximately 15% of her body weight and was found dead on 1 January 1992. At the time of death the raccoon was indoors at a temperature of approximately 35 C.

At necropsy the carcass was in poor body condition and the mucous membranes were pale. The mesenteric lymph node was at least five times the normal size (10 × 3 × 2.5 cm; Fig. 1). On cut surface, the parenchyma was uniformly pale tan and had a soft consistency. Similar but lesser enlargement of other abdominal and thoracic lymph nodes was noted. The spleen and the pancreas were also enlarged and extensively infiltrated with pale tan soft material. Representative tissue

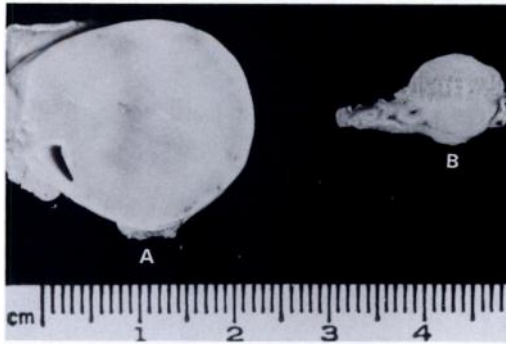


FIGURE 1. Cut sections through mesenteric lymph nodes of two age-matched raccoons. A, with lymphosarcoma. B, normal.

samples were fixed in 10% formalin for histopathology, embedded in paraffin, sectioned at $6\ \mu\text{m}$, and stained with hematoxylin and eosin. Sections of mesenteric lymph node and liver were stained with toluidine blue to detect metachromatic granules within the cytoplasm of the neoplastic cells (Humason, 1979).

On microscopic examination of the mesenteric lymph node, there was complete effacement of the normal cortical architecture and replacement with sheets of densely packed homogeneous population of mononuclear cells (Figs. 2 and 3) which also infiltrated the capsular region (Fig. 3). The neoplastic cells were well-differentiated lymphocytes which had darkly stained nuclei and a moderate amount of cytoplasm with distinct borders. Large numbers of mitotic figures, up to 12 per high power field ($400\times$), were seen. Similar but less extensive neoplastic infiltrates were also seen in the spleen, pancreas, and the liver (Fig. 4). With toluidine blue-stained sections, no metachromatic granules were seen within the cytoplasm of the neoplastic cells.

Lymphosarcoma is the most common neoplasm of most animals (Moulton and Harvey, 1990). In the present case, gross findings were consistent with a malignant neoplasm involving a number of lymph nodes. Neoplastic changes characteristic for lymphosarcoma (Moulton and Harvey,

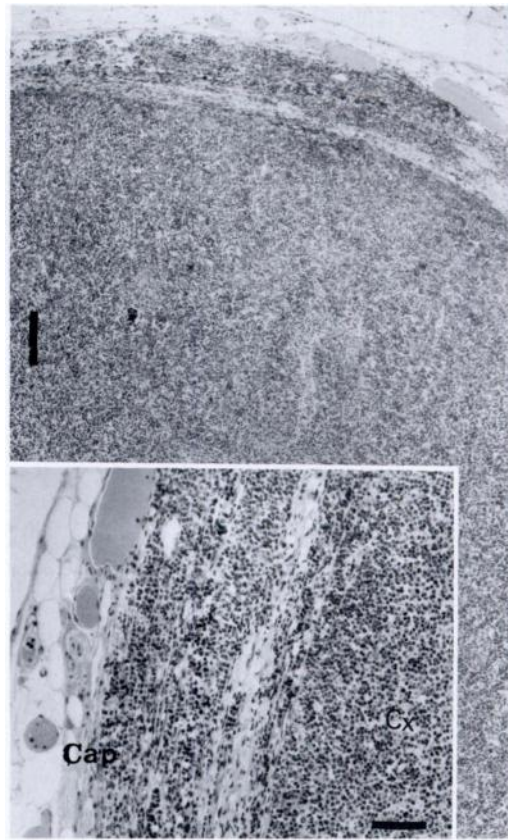


FIGURE 2. Photomicrograph of mesenteric lymph node of raccoon with lymphosarcoma. H&E. Bar = $250\ \mu\text{m}$. Insert is a higher magnification showing both the cortex (Cx) and capsule (Cap) infiltrated with neoplastic lymphocytes. H&E. Bar = $100\ \mu\text{m}$.

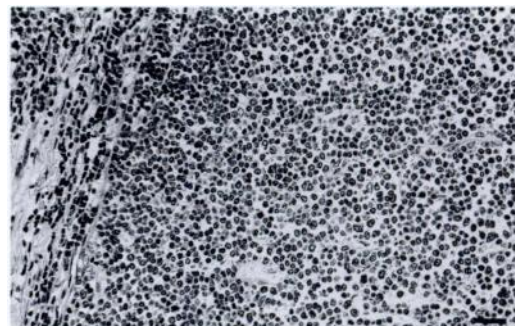


FIGURE 3. Higher magnification of lymphosarcoma showing monomorphic neoplastic lymphocytes which have extensively infiltrated the cortex and the capsule. H&E. Bar = $80\ \mu\text{m}$.

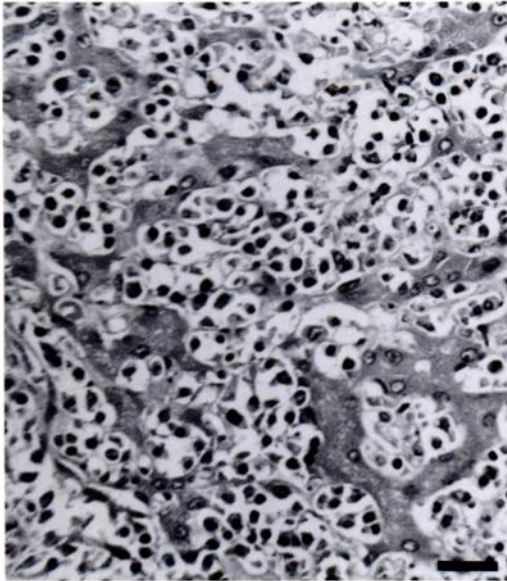


FIGURE 4. Photomicrograph of liver of a raccoon with metastatic lymphosarcoma. In this area, much of the normal liver parenchyma has been effaced by sheets of neoplastic cells. Only a few viable hepatocytes are evident. H&E. Bar = 50 μ m.

1990) were observed on histopathologic examinations. In domestic animals, lymphosarcomas are grouped according to anatomic locations; five forms, thymic, alimentary, multicentric, cutaneous, and solitary, have been described (Moulton and Harvey, 1990). Since the neoplasm in the raccoon involved several abdominal organs, it was most likely of multicentric origin. However, since the mesenteric lymph node was the most extensively involved organ, the node may have been the primary site of the neoplasm with secondary involvement of the other lymph nodes and the abdominal organs.

Neoplasia, with the exception of thyroid tumors (Kronberger, 1962; Ippen, 1987) appears to be rare in raccoons. In a retrospective survey of over 400 raccoon necropsies, Diters et al. (1978) found only two cases of neoplasia, an astrocytoma of the brain and a fibroma of the skin. Similarly, at our laboratory, we have examined an approximately similar sample size of raccoons from northeastern USA and have reported

eight cases of adrenal gland adenomas (Hamir and Rupprecht, 1995) and two cases of multifocal skin papillomas caused by papilloma virus (Hamir et al., 1995). Ippen (1987), on the other hand, found 16 tumors in 93 raccoons that were necropsied at zoological facilities. Thirteen of these tumors were of thyroid gland origin, and one each involved the liver, kidney, and uterus. None of the neoplasms of the latter three organs were lymphosarcomas.

There were some significant cytological differences between this case and the lymphosarcoma documented by Roher and Nielsen (1984). We found predominant infiltration of various tissues (including lymph nodes, spleen, liver and pancreas) with well-differentiated small neoplastic lymphocytes; whereas Roher and Nielsen (1984) found infiltration of kidneys, brain and meninges with large lymphoblastic cells. In lymphosarcomas of dogs, the cell types most commonly encountered are histiocytic and poorly differentiated; whereas in cats the predominant cell types are either prolymphocytic, histiocytic or mixed lymphocyte-histiocytic types in multicentric lymphomas (Moulton and Harvey, 1990). Since there is paucity of reported cases of neoplasms in raccoons, no conclusions regarding incidence, organ involvement or cell types can be derived at this time.

We thank Barbara Lehmann, Ray Buchanan, and Suzanne Hindman for technical assistance. This work was supported by funds from the Pennsylvania Department of Agriculture and the Department of Pathobiology, University of Pennsylvania.

LITERATURE CITED

- DITERS, R. W., C. H. KIRCHER, AND S. W. NIELSEN. 1978. Astrocytoma in a raccoon. *Journal of the American Veterinary Medical Association* 173: 1152-1153.
- HAMIR, A. N., AND C. E. RUPPRECHT. 1995. Adrenal gland adenomas in raccoons (*Procyon lotor*) from eastern United States. *Journal of Veterinary Diagnostic Investigation* 7: 413-416.
- , G. MOSER, A. B. JENSON, J. P. SUNDBERG,

- C. HANLON, AND C. E. RUPPRECHT. 1995. Papilloma virus infection in raccoons (*Procyon lotor*). *Journal of Veterinary Diagnostic Investigation* 7: 549–551.
- HUMASON, G. L. 1979. Staining cellular elements. *In* *Animal tissue techniques*. W. H. Freeman and company, San Francisco, California, pp. 305–334.
- IPPEN, R. 1987. Ein Beitrag zu den Tumoren der nicht-domestizierten Landraubtiere (Fissipedia). *DTW Deutsche Tierärztliche Wochenschrift* 94: 61–63.
- KAISER, H. E. 1981. Animal neoplasms—a systemic review. *In* *Neoplasms—comparative pathology of growth in animals, plants, and man*. Williams and Wilkins, Baltimore, Maryland, pp. 747–812.
- KRONBERGER, H. 1962. Geschwulste bei Zootieren. *Nordisk Veterinaermedizin* 14: 297–304.
- MOULTON, J. E., AND J. W. HARVEY. 1990. Tumors of the lymphoid and hematopoietic tissues. *In* *Tumors in domestic animals*, 3rd. ed. University of California Press, Berkeley, California, pp. 231–307.
- ROHER, D. P., AND S. W. NIELSEN. 1984. Lymphosarcoma in a raccoon, *Procyon lotor* (L). *Journal of Wildlife Diseases* 20: 156–157.
- RUPPRECHT, C. E., C. A. HANLON, A. N. HAMIR, AND H. KOPROWSKI. 1992. Oral wildlife rabies vaccination: Development of a recombinant virus vaccine. *Transactions of the North American Wildlife and Natural Resources Conference* 57: 439–452.
- WILLIAMS, E. S. 1982. Miscellaneous diseases. *In* *Diseases of wildlife in Wyoming*, 2nd ed., E. T. Thorne, N. Kingston, W. R. Jolley, and R. C. Bergstrom (eds.). Wyoming Game and Fish Department, Cheyenne, Wyoming, pp. 261–301.

Received for publication 21 July 1995.