



Respiratory and Pharyngo-Esophageal Iridovirus Infection in a Gopher Tortoise (*Gopherus polyphemus*)

Authors: Westhouse, R. A., Jacobson, E. R., Harris, R. K., Winter, K. R., and Homer, B. L.

Source: Journal of Wildlife Diseases, 32(4) : 682-686

Published By: Wildlife Disease Association

URL: <https://doi.org/10.7589/0090-3558-32.4.682>

BioOne Complete (complete.BioOne.org) is a full-text database of 200 subscribed and open-access titles in the biological, ecological, and environmental sciences published by nonprofit societies, associations, museums, institutions, and presses.

Your use of this PDF, the BioOne Complete website, and all posted and associated content indicates your acceptance of BioOne's Terms of Use, available at www.bioone.org/terms-of-use.

Usage of BioOne Complete content is strictly limited to personal, educational, and non - commercial use. Commercial inquiries or rights and permissions requests should be directed to the individual publisher as copyright holder.

BioOne sees sustainable scholarly publishing as an inherently collaborative enterprise connecting authors, nonprofit publishers, academic institutions, research libraries, and research funders in the common goal of maximizing access to critical research.

Respiratory and Pharyngo-Esophageal Iridovirus Infection in a Gopher Tortoise (*Gopherus polyphemus*)

R. A. Westhouse,¹ E. R. Jacobson,² R. K. Harris,³ K. R. Winter,⁴ and B. L. Homer,^{1,5} ¹Department of Pathobiology, P.O. Box 100145, College of Veterinary Medicine, University of Florida, Gainesville, Florida 32610-0145, USA; ²Department of Small Animal Clinical Sciences, College of Veterinary Medicine, University of Florida, Gainesville, Florida 32610-0145, USA; ³Department of Defense, Armed Forces Institute of Pathology, Washington, D.C. 20306-6000, USA; and ⁴Care & Rehabilitation of Wildlife, Inc., Sanibel Island, Florida 33957, USA; ⁵Reprint requests from Dr. Homer

ABSTRACT: A free-living adult male gopher tortoise (*Gopherus polyphemus*) was found on Sanibel Island, Florida (USA), on 18 February 1992 with signs of upper respiratory disease. On necropsy after euthanasia on 27 February 1992, severe, extensive necrotizing ulcerative tracheitis, multifocal necrotizing pneumonia, and multifocal necrotizing ulcerative pharyngitis and esophagitis were observed. Large ovoid to round intracytoplasmic basophilic inclusions, which appeared to displace the nucleus to the cell periphery, occurred within degenerate and necrotic epithelial cells of the above tissues. On transmission electron microscopy of formalin-fixed trachea and lung, intracytoplasmic viral particles were observed within necrotic cells in the tracheal lumen and epithelial cells of the lung. Most infected cells also had a roughly spherical granular cytoplasmic inclusion that contained clusters of viral particles. Viral particles had an electron dense spherical to icosahedral core surrounded by a less electron dense icosahedral capsid. Mature extracellular virions were surrounded by an envelope and were 150 to 220 nm in diameter. Virions and cytoplasmic inclusions were morphologically similar to those of the Family Iridoviridae.

Key words: Gopher tortoise, *Gopherus polyphemus*, iridovirus, pneumonia, tracheitis, esophagitis, pharyngitis.

Iridoviridae are double-stranded DNA viruses that consist of an icosahedral nucleocapsid surrounded by a lipid-containing envelope (Murphy and Kingsbury, 1990). The virion diameter is 125 to 300 nm. Viral replication occurs in the cytoplasm, and virions are released into the extracellular space by membrane budding or following cell necrosis (Murphy and Kingsbury, 1990). This family of viruses infects a wide variety of nonmammalian hosts, including lizard erythrocytic virus among lizards (Telford and Jacobson, 1993); lymphocystis disease (Wolf, 1988a),

viral hematopoietic necrosis (Schuh and Shirley, 1990), and viral erythrocytic necrosis (Wolf, 1988a) in fish; and frog erythrocytic virus among amphibians (Gruija-Gray et al., 1989). Infections also occurs in insects (Kelly, 1985), terrestrial isopods, and nematodes (Hess and Poinar, 1985). In this report, we implicate a virus with morphologic features similar to those of the Family Iridoviridae as the cause of a multifocal necrotizing disease of the trachea, lungs, pharynx and esophagus in a gopher tortoise (*Gopherus polyphemus*).

Gopher tortoises are listed as a species of special concern in Florida with the destruction of habitat as the single most important factor for their population decline (Diemer, 1987). Because of this status, there is growing interest in their diseases. A free-living, 4.2 kg adult male gopher tortoise from Sanibel Island, Florida (USA) (26°26'N, 82°5'W), was evaluated because of clinical upper respiratory disease on 18 February 1992. The tortoise was identified during a population survey involving habitat research. Clinical signs included ocular and nasal mucoid discharge, lethargy, listlessness, and mild dehydration. The packed cell volume, obtained by microhematocrit tube centrifugation was 25%; total protein via refractometry was 4.4 g/dl (Duncan et al., 1994). Treatment consisted of enrofloxacin, a broad spectrum antibiotic (Haver/Diamond Scientific, Shawnee, Kansas, USA) at a dose of 0.75 ml intramuscularly (IM) once daily, along with vitamins A (0.05 ml) and B-complex (0.25 ml) IM weekly. The diet was supplemented once daily with 20 ml (orally) of Nutri-cal®, a high caloric dietary supplement

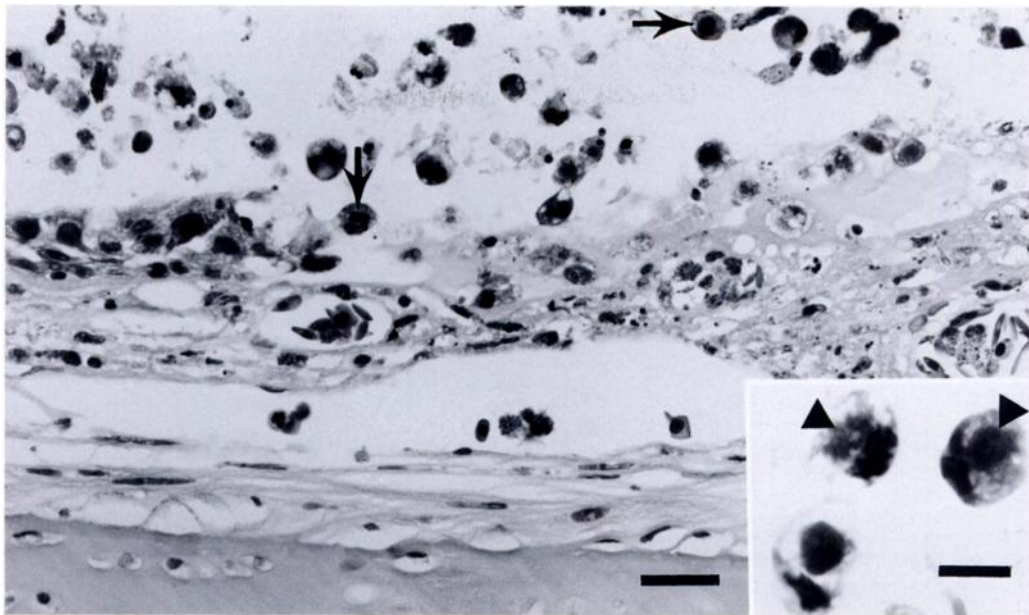


FIGURE 1. Trachea from a gopher tortoise with iridovirus infection. The mucosa is ulcerated and the lumen contains degenerate and necrotic cells admixed with cellular debris. Many of the degenerate cells within the lumen contain large intracytoplasmic inclusion bodies (arrows) that displace the nuclei peripherally. Hematoxylin and eosin. Bar = 30 μ m. Inset: Higher magnification of degenerate cells with intracytoplasmic viral inclusion bodies (arrowheads). Bar = 10 μ m.

(Evsco Pharmaceuticals, Buena, New Jersey, USA). Due to a progressive decline in condition, the tortoise was euthanatized by the injection of 1.0 ml Beuthanasia® (Schering-Plough Animal Health, Kenilworth, New Jersey) into the occipital sinus 9 days later on 27 February 1992.

During necropsy only petechial hemorrhages of the pharyngeal mucosa and diffuse pulmonary congestion were observed. Tissue samples of trachea, lung, liver, kidney, heart, pharynx, esophagus, testicle, and striated muscle were fixed in 10% neutral buffered formalin for 72 hr, processed through a graded series of alcohols, embedded in paraffin, sectioned at 6 μ m, and stained with hematoxylin and eosin.

The tracheal mucosa was extensively ulcerated and the lumen contained abundant cellular debris admixed with fibrin, degenerate and necrotic cells, numerous heterophils, and occasional macrophages (Fig. 1). Many of the degenerate and necrotic cells within the lumen had vacuo-

lated cytoplasm and an ovoid to round or ill-defined, basophilic, 5 to 9 μ m diameter intracytoplasmic inclusion (Fig. 1 inset). Nuclei of infected cells were eccentric and often pyknotic, karyolytic, or obscured by the inclusion. The intact epithelial cells tended to be attenuated and elongated along the basement membrane. There was diffuse fibrin exudation, heterophilic infiltration, and edema in the lamina propria. In the lung, there was multifocal epithelial cell necrosis associated with fibrin exudation and moderate infiltration of heterophils and macrophages. The intact epithelial cells in necrotic foci contained intracytoplasmic inclusions similar to those in the trachea. Alveolar septa were multifocally widened by foamy eosinophilic material and small infiltrates of heterophils with occasional mononuclear leukocytes. There was mild multifocal hyperplasia of cells consistent with alveolar type II cells. After we stained tissue sections of trachea and lung for bacteria with Brown & Brenn

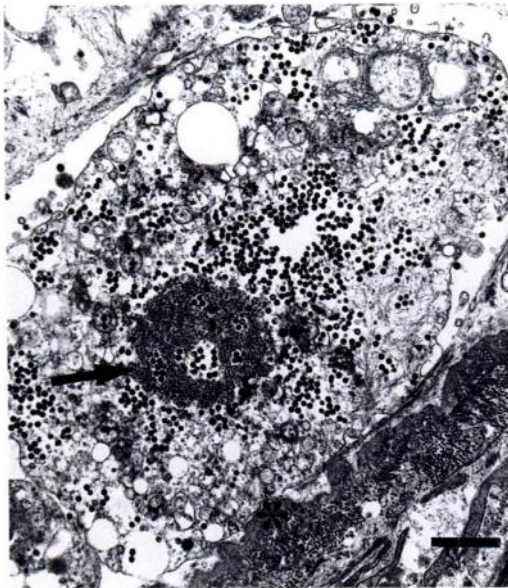


FIGURE 2. Transmission electron micrograph of the trachea from a gopher tortoise with iridovirus infection. Necrotic epithelial cell is lifted off the irregular basement membrane (asterisk). Virions are in cytoplasm and occasionally in the extracellular space. A granular inclusion (arrow) contains scattered virions amid electron-dense granular material. Bar = 1.5 μ m.

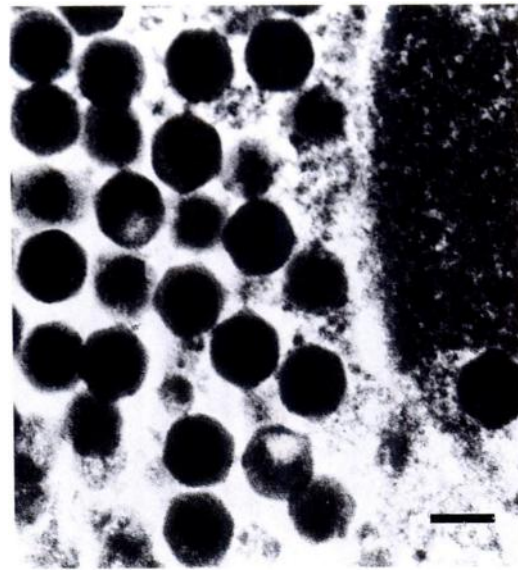


FIGURE 3. Transmission electron micrograph of the trachea from a gopher tortoise with iridovirus infection. Intracellular viral particles have an electron dense core surrounded by a less electron dense hexagonal capsid. Electron dense granular material (right side of photo) is part of the cytoplasmic granular inclusion. Bar = 100 nm.

stain (Luna, 1968) and for fungi by Grocott's method (Luna, 1968), we did not observe any microbial organisms. Feulgen staining (Lillie and Fullmer, 1976) of the cytoplasmic inclusions was positive, indicating presence of DNA. The mucosa of the pharynx and esophagus was multifocally necrotic and ulcerated. The necrosis extended into the subjacent mucous glands. Many sloughed epithelial cells in necrotic areas contained intracytoplasmic inclusions. The intact epithelium was multifocally hypertrophied and hyperplastic. Hepatocyte cytoplasm was often distended with discrete clear vacuoles, consistent with lipid. The kidney contained small numbers of scattered hemosiderin-laden macrophages. The heart, testicle and striated muscle had no significant lesions.

Portions of formalin-fixed trachea and lung were cut into 1 mm cubes, post-fixed in 1% osmium tetroxide (Ted Pella, Inc., Redding, California, USA), dehydrated

through graded concentrations of alcohol, embedded in LR White acrylic resin (Polysciences, Inc., Warrington, Pennsylvania, USA) and ultrathin sections were stained with uranyl acetate (Ted Pella, Inc.) and lead citrate (Ted Pella, Inc.) by the procedures of Hayat (1989). Sections were examined in a Zeiss electron microscope (Model 10A, Carl Zeiss Inc., Thornwood, New York, USA). Viral particles were present in the cytoplasm of degenerate and necrotic epithelial cells of the trachea (Fig. 2) and lung, and necrotic cells in the tracheal lumen. Viral particles had a central electron dense round to hexagonal core, surrounded by a less electron dense granular hexagonal capsid, indicative of icosahedral symmetry (Fig. 3). Extracellular virions were sometimes encompassed by cellular debris and fibrin. Several extracellular virions were enveloped, apparently associated with cell membrane budding. Enveloped intracellular virions were not identified. Non-enveloped viral particles

were 130 to 140 nm in diameter. Mature, enveloped virions were 150 to 220 nm in diameter. Most infected cells contained a large spherical electron dense granular inclusion, which often contained clusters of viral particles (Fig. 2). Frozen tissue was not available for virus isolation.

Enveloped viruses with polygonal symmetry include hepadnaviruses, togaviruses, retroviruses, herpesviruses, and iridoviruses (Murphy and Kingsbury, 1990). Of these, hepadnaviruses, herpesviruses, and iridoviruses contain DNA. The diameter of hepadnaviruses is 40 to 48 nm, while virions of herpesviruses and iridoviruses are 100 to 110 nm, and 125 to 300 nm, respectively (Cheville, 1994). Herpesviruses are assembled in the nucleus, while iridoviruses are assembled in the cytoplasm (Cheville, 1994). On examining the trachea and lung by electron microscopy, we observed virus only within the cytoplasm. Moreover, using light microscopy we observed inclusions only within the cytoplasm. Using a Feulgen stain, these inclusions were composed of DNA, supporting our diagnosis of an iridovirus infection.

This is only the second report of an iridovirus infection in a chelonian species. The anatomic distribution of lesions in this gopher tortoise was significantly different than the distribution described in a captive spur-tailed Mediterranean land tortoise (*Testudo hermanni*), in which iridovirus infection was associated with multifocal necrotizing hepatitis, splenitis, and enterocolitis (Heldstab and Bestetti, 1982). Basophilic cytoplasmic inclusions were present in degenerate hepatocytes and occasional intestinal mucosal cells. The identity of that virus was confirmed ultrastructurally.

Iridoviruses have been identified in eosinophilic cytoplasmic inclusions within erythrocytes, associated with anemia in lizards (Telford and Jacobson, 1993), frogs (Gruia-Gray et al., 1989), and fish (Wolf, 1988b). In fish, iridoviruses can also cause systemic disease associated with lesions in multiple organs. The disease viral hematopoietic necrosis, reported in an angelfish

(*Pterophyllum scalare*), not only was characterized by widespread necrosis of circulating and non-circulating hematopoietic cells, and multifocal necrosis of the hematopoietic tissue in the kidney and spleen, but also by parenchymal necrosis of the pancreas, and mural necrosis of visceral blood vessels (Schuh and Shirley, 1990). Small round eosinophilic cytoplasmic inclusions were identified in affected erythrocytes. A systemic viscerotropic iridovirus infection, associated with diffuse splenic necrosis and viral inclusions in hematopoietic cells, hepatocytes and endothelial cells, was reported in farm-raised gouramis (*Trichogaster trichopterus*) by Fraser et al. (1993). The systemic viscerotropic diseases of fish are distinctly different from lymphocystis disease of fish, which is dermatotropic (Wolf, 1988a). This dermatotropic strain of iridovirus causes elevated, multinodular cutaneous masses, associated with marked enlargement of infected cells (Wolf, 1988a). Electron dense granular inclusions, as occurred in lung and tracheal epithelial cells of the gopher tortoise of this report have been described in lizards (Telford and Jacobson, 1993) and fish (Gruia-Gray et al., 1989). These structures probably contribute to the appearance of the cytoplasmic inclusions observed on light microscopy and may represent a viral assembly site (Telford and Jacobson, 1993).

There was a strictly respiratory and pharyngo-esophageal distribution of lesions in the gopher tortoise of our report; thus inhalation or ingestion of the virus may have been the portal of infection. Infection with viscerotropic iridovirus of fish is also thought to be through ingestion (Schuh and Shirley, 1990; Fraser et al., 1993) while dermatotropic lymphocystis disease virus is most likely acquired via the gills or skin wounds (Wolf, 1988a). Trauma enhances transmission of lymphocystis disease; the oral route does not seem to be involved (Wolf, 1988a). Based on the lack of reported cases of iridovirus infection, the impact of this disease on populations

of free-living gopher tortoises does not appear to be significant at this time.

We thank Ms. Betty Hall for her skilled technical assistance. This paper is published as University of Florida, College of Veterinary Medicine, Journal Series Number 400.

LITERATURE CITED

- CHEVILLE, N. F. 1994. Ultrastructural pathology: An introduction to interpretation. Iowa State University Press, Ames, Iowa, pp. 502–514, 527–530.
- DIEMER, J. E. 1987. The status of the gopher tortoise in Florida. In *Proceedings of the third southeastern non-game and endangered wildlife symposium*. R. Odom, K. Riddleberger, and J. Ozier (eds.). Georgia Department of Natural Resources, Game and Fish Division, Atlanta, Georgia, pp. 72–83.
- DUNCAN, J. R., K. W. PRASSE, AND E. A. MAHAFFEY. 1994. *Veterinary laboratory medicine: Clinical pathology*. Iowa State University Press, Ames, Iowa, 300 pp.
- FRASER, W. A., T. J. KEEFE, AND B. BOLON. 1993. Isolation of an iridovirus from farm-raised gouramis (*Trichogaster trichopterus*) with fatal disease. *Journal of Veterinary Diagnostic Investigation* 5: 250–253.
- GRUIA-GRAY, J., M. PETRIC, AND S. S. DESSER. 1989. Ultrastructural, biochemical and biophysical properties of an erythrocytic virus of frogs from Ontario, Canada. *Journal of Wildlife Diseases* 25: 497–506.
- HAYAT, M. A. 1989. *Principles and techniques of electron microscopy: Biological applications*. CRC Press, Inc., Boca Raton, Florida, 469 pp.
- HELDSTAB, A., AND G. BESTETTI. 1982. Spontaneous viral hepatitis in a spur-tailed Mediterranean land tortoise. *Journal of Zoo Animal Medicine* 13: 113–120.
- HESS, R. T., AND G. O. POINAR. 1985. Iridoviruses infecting terrestrial isopods and nematodes. *Current Topics in Microbiology and Immunology* 116: 49–76.
- KELLY, D. C. 1985. Insect iridescent viruses. *Current Topics in Microbiology and Immunology* 116: 23–35.
- LILLIE, R. D., AND H. M. FULLMER. 1976. *Histologic technic and practical histochemistry*. McGraw-Hill Book Co., New York, New York, pp. 171–177.
- LUNA, L. G. 1968. *Manual of histologic staining methods of the Armed Forces Institute of Pathology*. McGraw-Hill Book Co., New York, New York, pp. 222–232.
- MURPHY, F. A., AND D. W. KINGSBURY. 1990. Virus taxonomy. In *Fields virology*. B. N. Fields and D. M. Knipe (eds.). Raven Press, Ltd., New York, New York, pp. 9–35.
- SCHUH, J. C. L., AND I. G. SHIRLEY. 1990. Viral hematopoietic necrosis in an angelfish (*Pterophyllum scalare*). *Journal of Zoo and Wildlife Medicine* 21: 95–98.
- TELFORD, S. R., AND E. R. JACOBSON. 1993. Lizard erythrocytic virus in east African chameleons. *Journal of Wildlife Diseases* 29: 57–63.
- WOLF, K. 1988a. Lymphocystis disease. In *Fish viruses and fish viral diseases*. K. Wolf (ed.). Comstock Publishing Associates, Ithaca, New York, pp. 268–291.
- . 1988b. Viral erythrocytic necrosis. In *Fish viruses and fish viral diseases*. K. Wolf (ed.). Comstock Publishing Associates, Ithaca, New York, pp. 389–398.

Received for publication 4 April 1995.