



Coccidioidomycosis in Free-living California Sea Lions (*Zalophus californianus*) in Central California

Authors: Fauquier, D. A., Gulland, F. M. D., Trupkiewicz, J. G., Spraker, T. R., and Lowenstine, L. J.

Source: Journal of Wildlife Diseases, 32(4) : 707-710

Published By: Wildlife Disease Association

URL: <https://doi.org/10.7589/0090-3558-32.4.707>

BioOne Complete (complete.BioOne.org) is a full-text database of 200 subscribed and open-access titles in the biological, ecological, and environmental sciences published by nonprofit societies, associations, museums, institutions, and presses.

Your use of this PDF, the BioOne Complete website, and all posted and associated content indicates your acceptance of BioOne's Terms of Use, available at www.bioone.org/terms-of-use.

Usage of BioOne Complete content is strictly limited to personal, educational, and non - commercial use. Commercial inquiries or rights and permissions requests should be directed to the individual publisher as copyright holder.

BioOne sees sustainable scholarly publishing as an inherently collaborative enterprise connecting authors, nonprofit publishers, academic institutions, research libraries, and research funders in the common goal of maximizing access to critical research.

Coccidioidomycosis in Free-living California Sea Lions (*Zalophus californianus*) in Central California

D. A. Fauquier,¹ F. M. D. Gulland,¹ J. G. Trupkiewicz,² T. R. Spraker,³ and L. J. Lowenstine,² ¹The Marine Mammal Center, Golden Gate National Recreation Area, Sausalito, California 94965, USA; ²Department of Pathology, Microbiology and Immunology, University of California, Davis, California 95616, USA; ³Wildlife Pathology International, 2905 Stanford Road, Fort Collins, Colorado 80521, USA

ABSTRACT: Coccidioidomycosis is described in seven California sea lions (*Zalophus californianus*) admitted to The Marine Mammal Center, Sausalito, California (USA), between January 1986 and December 1994. Diagnoses were confirmed by histology in all seven cases, culture in three cases, and serology in one case. These are believed to be the first published cases of coccidioidomycosis in free-ranging California sea lions.

Key words: Coccidioidomycosis, *Coccidioides immitis*, fungal disease, California sea lion, *Zalophus californianus*, pinniped, California.

Coccidioides immitis is a free-living soil dwelling fungus that survives in saline soil and in sea water (Egeberg et al., 1964; Dzawachiszwili et al., 1964). In the United States, it is endemic to Arizona, California, Nevada, New Mexico, Texas and Utah; it is also found in Mexico and parts of South America (Pappagianis, 1988).

Coccidioides immitis is infectious to mammals and of major health concern to humans (Kaplan, 1973). Coccidioidomycosis commonly is contracted by inhaling dust-borne spores (Pappagianis, 1988). The disease typically is characterized by granulomatous pneumonia, although in 1% of human cases (usually adult white males), dissemination occurs (Kaplan, 1973). There have been numerous reports of *C. immitis* infections in domestic animals, including cattle, sheep, llamas (*Lama glama*), and dogs (Pappagianis, 1988). Infections also have been reported in captive wild animals including a mountain gorilla (*Gorilla gorilla beringei*), Bengal tiger (*Panthera tigris*), a giant red kangaroo (*Macropus rufus*), and a tapir (*Tapirus terrestris*) (Pappagianis, 1988); and in free-ranging wild animals, including a western cougar (*Felis concolor*) (Clyde et al., 1990), desert bighorn sheep (*Ovis canadensis nel-*

soni) (Jessup et al., 1989), and coyotes (*Canis latrans*) (Pappagianis, 1988). The only previously reported cases of *C. immitis* in marine mammals occurred in a captive California sea lion (*Zalophus californianus*) at the Reid Park Zoo, Tucson, Arizona (Reed et al., 1976), a wild California sea otter (*Enhydra lutris*) from Morro Bay, California (Cornell et al., 1979), and a wild California sea lion from San Diego, California (K. G. Osborn, pers. comm.).

Since 1986, seven cases of coccidioidomycosis in free-living California sea lions have been diagnosed at The Marine Mammal Center, Sausalito, California. One case per year occurred during 1986, 1988, and 1992. During 1993 and 1994, there were two cases per year. All the animals stranded live along the central California coast, between 37°42'N, 123°05'W and 35°59'N, 121°30'W. One California sea lion stranded in Santa Cruz County, three stranded in Monterey County, and three stranded in San Luis Obispo County. Sex and age were recorded for each animal. Observations of external characteristics (size, tooth development and wear, coat color, crest development) were used to classify animals as sub-adult or adult (Mate, 1978). Ages were determined for three of the animals by counting annual growth layers of dentin in sagittal sections of the decalcified upper left canine tooth (Payne, 1978).

Six of the seven animals died naturally within one to 11 days of stranding. One animal was anesthetized with an intramuscular injection of 2.5 ml of 100 mg/ml xylazine hydrochloride (Anpro Pharmaceutical, Arcadia, California) and euthanized by intracardiac injection of 40 ml of 389

mg/ml sodium pentobarbital (Moby Corporation, Shawnee, Kansas, USA). Following routine post-mortem examination within 24 hr of death, representative tissue samples from the seven animals were fixed by immersion in 10% neutral buffered formalin. Tissues collected included brain, thyroid, lung, heart, aorta, liver, pancreas, spleen, stomach, intestine, colon, kidney, adrenal, gonad and reproductive tract, ureter, urinary bladder, urethra, multiple lymph nodes, and omentum. Fixed tissues were embedded in TissuePrep (Fischer Scientific, Fairlawn, New Jersey, USA), sectioned at 5 μm , and stained with hematoxylin and eosin (Luna, 1968). Samples of lung, liver, and lymph node (from four animals), were cultured on tryptic soy agar with 5% sheep blood and on MacConkey agar (PML Microbiologicals, Tualatin, Oregon, USA), incubated at 35 C, and examined after 24 hr (Carter, 1973). Microbiological identification of *C. immitis* was confirmed at the University of California, Davis, School of Veterinary Medicine, Department of Clinical Microbiology at the Veterinary Medical Teaching Hospital according to the method of Walsh and Mitchell (1991). Blood was collected from the caudal gluteal vein of one animal using a 21-gauge, 3-cm vacutainer needle, placed into a serum separation gel and clot activator tube (Vacutainer, Becton Dickinson, Rutherford, New Jersey) and centrifuged at $3,000 \times G$ for 15 min to separate serum. Serum was frozen at -40 C . A quantitative immunodiffusion test was used to detect serum antibodies to *C. immitis* (Pappagianis and Zimmer, 1990). This test was performed at the University of California, Davis, School of Medicine, Coccidioidomycosis Serology Laboratory.

Of the seven animals, five were male and two were female. The three animals of determinate age were 4 yr, 3 yr and 2 yr. The four animals aged by external characteristics included two adults and two sub-adults. On post-mortem examination, two of the animals had purulent fluid within the pleural cavity and yellow caseous

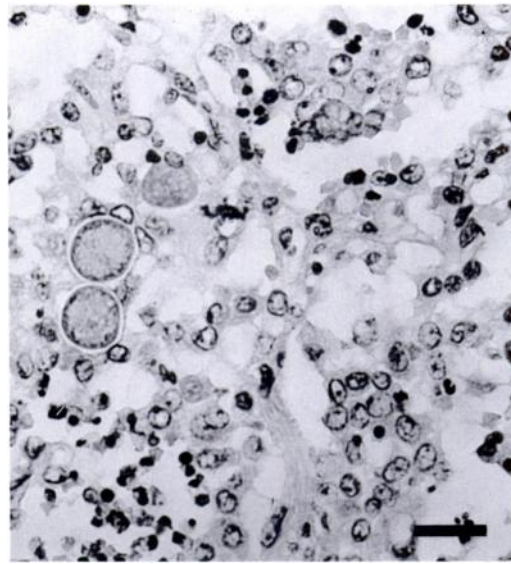


FIGURE 1. Histological section of California sea lion lung containing *Coccidioides immitis*, Hematoxylin and eosin. Bar = 50 μm .

nodules, 1 to 5 mm in diameter, throughout the lungs. One animal had a mass of solid tissue, 14 cm in diameter, that incorporated the submandibular and retro-pharyngeal lymph node, displacing the trachea from the midline. Four other animals had clear fluid in the peritoneal cavity and solid yellow masses, ranging from 7 to 27 cm in diameter, that incorporated the pancreas, pancreaticoduodenal lymph node, and omentum. These animals also had nodules, 1 to 10 mm in diameter, scattered throughout the mesentery and liver and, in three of the four cases, in the lungs.

On histological examination of tissues, pyogranulomatous infiltrates in the affected organs were observed in all seven cases. Round organisms, 10 to 70 μm in diameter (Fig. 1), with double contoured walls containing endospores, 2 to 5 μm in diameter, were observed and diagnosed histologically as *C. immitis* in all seven cases. *Coccidioides immitis* was isolated from three of the four animals from which tissues were cultured. The organism grew on blood agar plates and consisted of an aerial mold of whitish color. Serum from the one ani-

mal tested for antibodies to *C. immitis* had a titer of 1:256, which is evidence for disseminated coccidioidomycosis in humans and other animals (Pappagianis and Zimmer, 1990). To determine whether such antibodies were present in free-ranging sea lions, serum samples from 20 animals that stranded in central California suffering from pathological conditions other than coccidioidomycosis, such as trauma, neoplasia, and interstitial nephritis (Gage et al., 1993), were tested. No antibodies were detected using quantitative immunodiffusion.

Based on these seven cases *C. immitis* is capable of infecting free-ranging California sea lions and may be more common in California sea lions than previously suspected. The source and route of infection, however, are unknown. California sea lions breed along the eastern Pacific coast from islands in the Gulf of California to the Channel Islands off southern California (Peterson and Bartholomew, 1967). During the non-breeding season, California sea lions can migrate north from Mexico to British Columbia, Canada (Peterson and Bartholomew, 1967). They could therefore become infected anywhere along this migratory route. However, *C. immitis* only has been documented as endemic in areas in the central and southern part of the range, including the coastal counties of Monterey, San Luis Obispo, Ventura, Los Angeles, and San Diego, California as well as Baja California, Mexico (Pappagianis, 1988). Interestingly, coccidioidomycosis has been observed in California sea otters that stranded in San Luis Obispo County (Cornell et al., 1979; N. Thomas and L. Creekmore, pers. comm.). *Coccidioides immitis* can survive in sea water in the laboratory for up to 6 wk (Dzawachiszwili et al., 1964). It is unknown whether *C. immitis* can survive in ocean water.

There is no known health risk to animal care workers treating a California sea lion infected with *C. immitis* or while performing a necropsy (Pappagianis, 1988). However, cultures for microbiological identifi-

cation of *C. immitis* from tissue require a Biosafety Level 2 practice and facility (Richmond and McKinney, 1993). Furthermore, the remains of the animal should be disposed of quickly and with care due to the fungus sporulating once exposed to air (Pappagianis, 1988).

We thank Dr. Demosthenes Pappagianis for conducting the serological tests and commenting on this manuscript; Spencer Jang and Sherry Nolan for conducting the microbiological tests; Dr. Hilary Feldman, Dr. Tom Niesen and Michelle Lander for commenting on this manuscript; and Dr. Kimberlee Beckmen, Jan Roletto, and Krista Hanni for performing post mortem examinations. Personnel at the University of California, Berkeley, Museum of Vertebrate Zoology, assisted with tooth examination for aging. Personnel at National Marine Fisheries Service, Southwest Fisheries Science Center verified the ages obtained by tooth examination. This is Scientific Contribution 184 of The Marine Mammal Center.

LITERATURE CITED

- CARTER, G. R. 1973. Diagnostic procedures in veterinary microbiology, 2nd ed., Charles C. Thomas (ed.). Springfield, Illinois, 362 pp.
- CLYDE, L. H., G. V. KOLLIAS, M. E. ROELKE, AND M. R. WELLS. 1990. Disseminated coccidioidomycosis in a western cougar (*Felis concolor*). *Journal of Wildlife Diseases* 21: 200–205.
- CORNELL, L. H., K. G. OSBORN, J. E. ANTRIM, AND J. G. SIMPSON. 1979. Coccidioidomycosis in a California sea otter (*Enhydra lutris*). *Journal of Wildlife Diseases* 15: 373–378.
- DZAWACHISZWILI, N., J. W. LANDAU, V. D. NEWCOMER, AND O. A. PLUNKETT. 1964. The effect of sea water and sodium chloride on the growth of fungi pathogenic to man. *Journal of Investigative Dermatology* 43: 103–109.
- EGERBERG, R. O., E. ELCONIN, AND M. C. EGERBERG. 1964. Effect of salinity and temperature on *Coccidioides immitis* and three antagonistic soil saprophytes. *Journal of Bacteriology* 88: 473–476.
- GAGE, L. J., J. A. GERBER, D. M. SMITH, AND L. E. MORGAN. 1993. Rehabilitation and treatment success rate of California sea lions (*Zalophus californianus*) and northern fur seals (*Callorhinus ursinus*) stranded along the central and northern California coast, 1984–1990. *Journal of Zoo and Wildlife Medicine* 24: 41–47.

- JESSUP, D. A., N. KOCK, AND M. BERBACH. 1989. Coccidioidomycosis in a desert bighorn sheep (*Ovis canadensis nelsoni*) from California. *Journal of Zoo and Wildlife Medicine* 20: 471-473.
- KAPLAN, W. 1973. Epidemiology of the principle systemic mycoses of man and lower animals and the ecology of their etiologic agents. *Journal of the Veterinary Medical Association* 163: 1043-1047.
- LUNA, L. G. 1968. Manual of histologic staining methods of the Armed Forces Institute of Pathology, 3rd ed. McGraw Hill Company, New York, New York, 121 pp.
- MATE, M. R. 1978. California sea lion. In *Marine mammals of eastern north Pacific and Arctic waters*, D. Haley (ed.). Pacific Search Press, Seattle, Washington, pp. 172-177.
- PAPPAGIANIS, D. 1988. Epidemiology of coccidioidomycosis. In *Current topics in medical mycology*, M. R. McGinnis (ed.). Springer-Verlag, New York, New York, pp. 199-237.
- , AND B. L. ZIMMER. 1990. Serology of coccidioidomycosis. *Clinical Microbiology Review* 3: 247-268.
- PAYNE, M. R. 1978. Population size and age determination in the Antarctic fur seal (*Arctocephalus gazella*). *Mammal Review* 8: 67-73.
- PETERSON, R. S., AND G. A. BARTHOLOMEW. 1967. The natural history and behavior of the California sea lion. American Society of Mammalogists, Stillwater, Oklahoma, 79 pp.
- REED, R. E., G. MIGAKI, AND J. A. CUMMINGS. 1976. Coccidioidomycosis in a California sea lion (*Zalophus californianus*). *Journal of Wildlife Diseases* 12: 372-375.
- RICHMOND, J. Y., AND R. W. MCKINNEY. 1993. Biosafety in microbiological and biomedical laboratories, 3rd ed. U.S. Department of Health and Human Services, Washington, D.C., 177 pp.
- WALSH, J., AND T. G. MITCHELL. 1991. Dimorphic fungi causing systemic mycoses. In *Manual of clinical microbiology*, 5th ed. A. Balows (ed.). American Society for Microbiology, Washington, D.C., pp. 630-643.

Received for publication 2 November 1995.