



Geographical Distribution of *Demodex ursi* in Black Bears from Florida

Authors: Foster, Garry W., Cames, Tânia A., and Forrester, Donald J.

Source: Journal of Wildlife Diseases, 34(1) : 161-164

Published By: Wildlife Disease Association

URL: <https://doi.org/10.7589/0090-3558-34.1.161>

BioOne Complete (complete.BioOne.org) is a full-text database of 200 subscribed and open-access titles in the biological, ecological, and environmental sciences published by nonprofit societies, associations, museums, institutions, and presses.

Your use of this PDF, the BioOne Complete website, and all posted and associated content indicates your acceptance of BioOne's Terms of Use, available at www.bioone.org/terms-of-use.

Usage of BioOne Complete content is strictly limited to personal, educational, and non - commercial use. Commercial inquiries or rights and permissions requests should be directed to the individual publisher as copyright holder.

BioOne sees sustainable scholarly publishing as an inherently collaborative enterprise connecting authors, nonprofit publishers, academic institutions, research libraries, and research funders in the common goal of maximizing access to critical research.

Geographical Distribution of *Demodex ursi* in Black Bears from Florida

Garry W. Foster,^{1,2} Tânia A. Cames,¹ and Donald J. Forrester,¹ ¹ Department of Pathobiology, College of Veterinary Medicine, University of Florida, P.O. Box 110880, Gainesville, Florida 32611, USA; ² Author for reprint requests (FosterG@mail.vetmed.ufl.edu)

ABSTRACT: From May 1990 to February 1996, 55 black bears (*Ursus americanus floridanus*) (38 males, 17 females) from 21 counties in Florida (USA), were examined for *Demodex ursi* (Acari: Demodicidae). The sample included cubs <1-yr-old ($n = 12$), juveniles (1 to <3 yr, $n = 20$), and adults (3 to 12 yr, $n = 23$). *Demodex ursi* was collected from four bears by deep scrapings of 15 sites on the head and forelimb of each bear. All four bears with demodicosis had crusty, scaly skin lesions, and moderate alopecia. No *D. ursi* were seen in any of the 750 scrapings from the other 51 bears, nor did any of those bears have signs of demodicosis. Demodicosis was found only in bears from or near the Ocala population in north-central Florida.

Key words: Black bear, Demodicosis, *Demodex ursi*, survey, *Ursus americanus*.

Demodicosis has been reported previously in five black bears (*Ursus americanus floridanus*) in Florida (USA) (Forrester et al. 1993); the etiologic agent was new and subsequently was described as *Demodex ursi* (Acari: Demodicidae) by Desch (1995). These cases were associated with varying degrees of alopecia. The present study was undertaken to determine the geographic distribution of *D. ursi* in the black bear population throughout Florida, and the presence of this mite in bears lacking signs of demodicosis.

From May 1990 to February 1996, 55 black bears (38 males, 17 females), killed by vehicle collision ($n = 51$) or illegally killed ($n = 4$), were obtained from 21 counties in Florida (USA) (between 25°48' and 31°00'N; 80°48' and 87°34'W) (Fig. 1). These included cubs <1 yr of age ($n = 12$), juveniles (juv) 1- to <3-yr-old ($n = 20$), and adults (ad) 3- to 12-yr-old ($n = 23$). Ages were determined by examination of the cementum annuli in a premolar tooth (Willey, 1974). Samples by county were as follows: Baker (1 ad); Bay (1 cub,

1 juv, 1 ad); Bradford (1 juv); Calhoun (2 ad); Collier (2 cubs, 1 juv, 2 ad); Franklin (1 ad); Glades (1 juv); Gulf (3 cubs, 1 juv, 1 ad); Hernando (1 ad); Highlands (1 cub, 1 juv, 2 ad); Jefferson (3 juv, 1 ad); Lake (1 cub, 3 juv, 4 ad); Liberty (2 juv, 1 ad); Marion (4 cubs, 1 juv, 1 ad); Nassau (1 juv); Okaloosa (1 ad); Putnam (1 ad); Seminole (2 juv); St. John's (1 ad); Sumter (1 juv, 2 ad); and Volusia (1 juv). We consider this mode of collection a random sampling of the bear population for the purpose of surveying for *Demodex* sp. In the five cases reported by Forrester et al. (1993) all affected bears had clinical signs of demodicosis on the head, face and forelimbs. To facilitate the handling of samples, between 1990 and 1993 the head and one forelimb, or their skins, were removed from each bear during necropsy, placed into individual plastic bags and frozen until examination. For the years 1994, 1995, and 1996 the bears were examined prior to necropsy. Upon examination, each sample was thawed, and 12 sites of 2cm² on the head and three on the forelimb were analyzed. The sites on the head included: lower nose, upper nose (between the eyes), forehead, crown (midway between the ears), upper and lower eyelids of both eyes, the right and left upper lip, and the caudal aspect of the pinna. The sites on the forelimb included: base of the middle digit, wrist, and the middle of the forearm. The hair was trimmed to skin level on all of the sites with scissors. At each site the exposed skin was scraped deeply with a scalpel blade and the scrapings placed on a glass microscope slide with mineral oil and covered with a cover glass. New gloves, and clean scissors and scalpel were used on each bear. Using a compound microscope

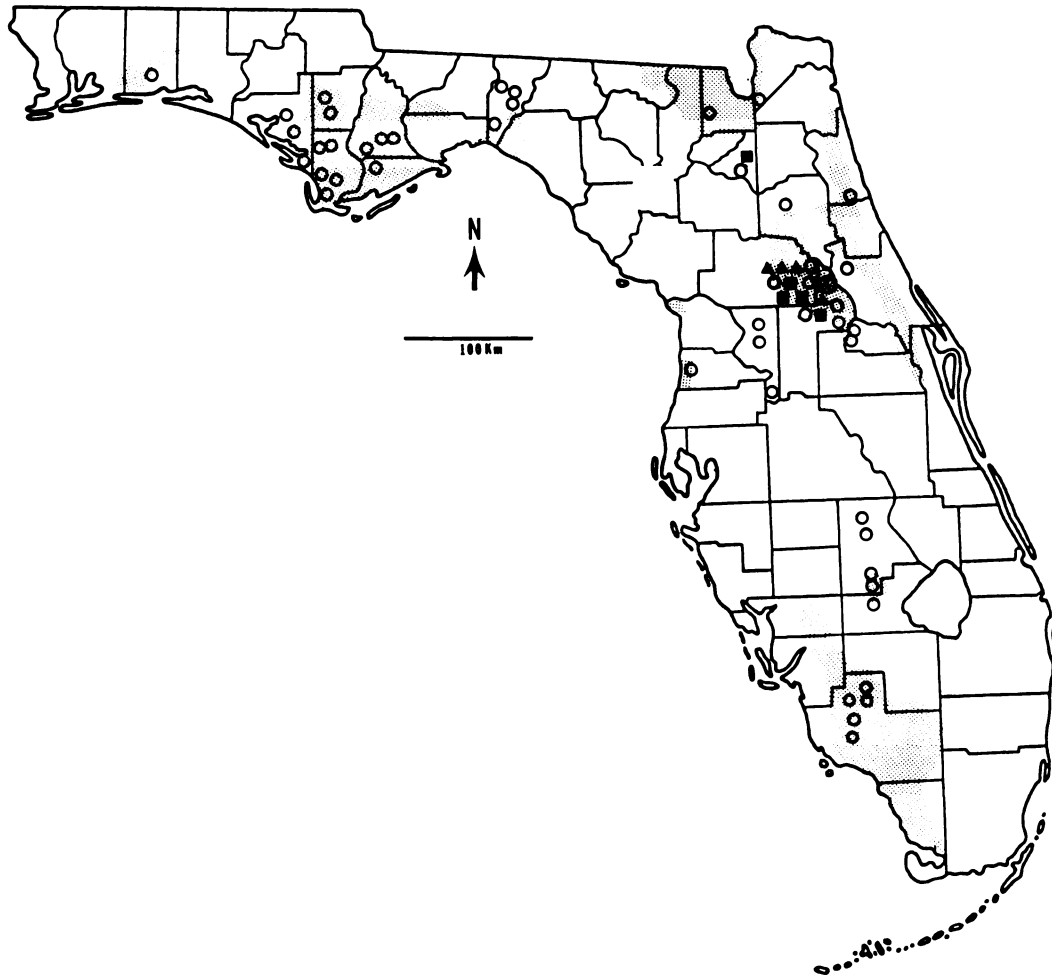


FIGURE 1. Distribution of *Demodex ursi* in the Florida black bear population. Stippled areas represent the most frequent reports of bears, open circles (○) are bears not infested with *D. ursi*, solid triangles (▲) represent bears infested with *D. ursi* (present study), solid squares (■) represent bears infested with *D. ursi* and reported in a previous study (Forrester et al. 1993), number inside circle indicates the number of bears at that location.

the slides were scanned at 100 \times for the presence of *Demodex* sp. A total of 810 sites was scraped. Four of the negative bears had the skin from the 12 areas on the head digested in 10% potassium hydroxide using the methods of Koutz et al. (1960) to locate mites potentially missed by scraping. To verify the KOH digestion technique and determine how long mites were detectable in the digested residue, areas from two of the infested bears were digested also.

Four bears from north-central Florida

were infested with *Demodex ursi* (Fig. 1). Three of these were 10-mo-old female cubs, weighing 14.9, 15.9, and 16.8 kg, obtained in Marion County (29°11'N, 81°55'W) in November of 1993. The fourth bear was an adult (>3 yr, not aged by premolar), 47.6 kg, male obtained in Lake County (28°56'N, 81°32'W) in October of 1994. On the three cubs, mites were present on all 15 sites scraped. On the adult bear, mites were present only in the left upper and lower eye lid scrapings. All four positive bears had signs of de-

modicosis, with crusty, scaly skin, and mild alopecia. On one of the cubs, two of these areas, the crown and the wrist, had a crusty yellowish exudate associated with the alopecia that may have been caused by a secondary pyoderma. Forrester et al. (1993) did not observe exudates on any of the bears they examined.

Three other bears had signs of mild hair thinning on small areas of the face or forehead which did not appear to be related to trauma. These areas were scraped in addition to the 15 regular sites and no *D. ursi* were found. The other 48 bears had no hair loss and no follicular mites were found on them.

Possibly, the five bears reported by Forrester et al. (1993) and the four bears reported here, which were infested with *D. ursi* were from a closely related family-group in the bear population from Ocala, although no genetic tests were performed on the bears. Six of the nine bears were collected within a 6.5 km section of State Road 40 in Marion County, with the three cubs only 3.2 km apart. The bear infested with *D. ursi* reported by Forrester et al. (1993) from Bradford County was a 5-yr-old male. Maehr et al. (1988) reported the movement of a 2.5-yr-old male bear which traveled 140 km in <1 mo in southern Florida. The Bradford County bear was collected about 100 km from the area near State Road 40 in Marion County. This bear could have been from the same area of Marion County as the other bears infested with *D. ursi*. The two bears from Lake County were collected 32 km from the area near State Road 40. The areas through which these three bears would have moved support bear populations and are characterized as good bear habitats (Brady and Maehr, 1985).

Demodicosis in dogs caused by a related mite, *D. canis*, is thought to be initiated by an immunosuppressive disorder and/or a hereditary defect in the immune system (Lemarie, 1996; Scott et al., 1996). If such phenomena were associated with these bears, this might explain why only a small

percentage of the bears in Florida had signs of demodicosis, and why most of the positive bears were found in such close proximity. However, unlike dogs which have demodicid mites as normal residents in their skin (Scott et al., 1996), mites were not found on any bears which lacked signs of demodicosis. Also, mites were not seen in the 48 skin digestions of the four bears that were negative by deep skin scraping. If the skin digestion method was utilized for a larger sample size, it might be possible to show that *D. ursi* occurs at a higher prevalence. With our use of a deep scraping technique we feel confident that there were no mites in the areas scraped. However, without digesting the skin of the whole bear we do not know if there might be mites elsewhere on the animal. Mites were easily seen in the skin digestions of the infested bears, with mites detectable in the digested residue for >8 mo. *Demodex ursi* seems to be a host specialist, only occurring on black bears (Desch, 1995). In Florida, *D. ursi* seems to have a restricted distribution, occurring only in the Ocala black bear population.

From 1976 to 1996 these nine black bears with *D. ursi* infestations represent the only cases in Florida in which demodicosis was noted in >460 carcasses examined (Forrester et al., 1993; J. C. Roof, pers. commun.). Manville (1978) reported *Demodex* sp. from one of 113 black bears (*U. americanus americanus*) live-trapped in northern Wisconsin and it was partially alopecic also. More study is needed on the host-parasite relationship between black bears and *D. ursi*, and the genetics of the black bear population in Florida.

We thank J. R. Brady, M. R. Dunbar and J. B. Wooding for assisting in sample collection. We thank also G. A. Kunkle for her discussions and insights on demodectic mange, and for reviewing an early draft of the manuscript. E. C. Greiner also reviewed an early draft of the manuscript and gave helpful suggestions for its improvement. This research was supported in part by a contract from the Florida

Game and Fresh Water Fish Commission and is a contribution of Federal Aid to Wildlife Restoration, Florida Pittman-Robertson Project W-41. This is Florida Agriculture Experiment Stations Journal Series No. R-05793.

LITERATURE CITED

- BRADY, J. R., AND D. S. MAEHR. 1985. Distribution of black bears in Florida. *Florida Field Naturalist* 13: 1-7.
- DESCH, C. E., JR. 1995. A new species of *Demodex* (Acari:Demodicidae) from the black bear of North America, *Ursus americanus* Pallas, 1780 (Ursidae). *International Journal of Acarology* 21: 23-26.
- FORRESTER, D. J., M. G. SPALDING AND J. B. WOODING. 1993. Demodicosis in black bears (*Ursus americanus*) from Florida. *Journal of Wildlife Diseases* 29: 136-138.
- KOUTZ, F. R., H. F. GROVES, AND C. M. GEE. 1960. A survey of *Demodex canis* in the skin of clinically normal dogs. *Veterinary Medicine* 55: 52-53.
- LEMARIE S. L. 1996. Canine demodicosis. *Compendium on Continuing Education for Practicing Veterinarians* 18: 354-368.
- MAEHR, D. S., J. N. LAYNE, E. D. LAND, J. W. MCCOWN, AND J. ROOF. 1988. Long distance movements of a Florida black bear. *Florida Field Naturalist* 16: 1-6.
- MANVILLE, A. M. 1978. Ecto- and endoparasites of the black bear in northern Wisconsin. *Journal of Wildlife Diseases* 14: 97-101.
- SCOTT, D. W., W. H. MILLER, AND C. E. GRIFFIN. 1995. *Muller and Kirk's Small Animal Dermatology*, 5th Ed., W.B. Saunders Company, Philadelphia, Pennsylvania, 1213 pp.
- WILLEY, C. N. 1974. Aging black bears from first premolar tooth sections. *The Journal of Wildlife Management* 38: 97-100.

Received for publication 26 June 1997.