



## **Gastric Spiral Bacteria in Wild Rats from Italy**

Authors: Giusti, Anna Maria, Crippa, Luca, Bellini, Ornella, Luini, Mario, and Scanziani, Eugenio

Source: Journal of Wildlife Diseases, 34(1) : 168-172

Published By: Wildlife Disease Association

URL: <https://doi.org/10.7589/0090-3558-34.1.168>

---

BioOne Complete ([complete.BioOne.org](https://complete.BioOne.org)) is a full-text database of 200 subscribed and open-access titles in the biological, ecological, and environmental sciences published by nonprofit societies, associations, museums, institutions, and presses.

Your use of this PDF, the BioOne Complete website, and all posted and associated content indicates your acceptance of BioOne's Terms of Use, available at [www.bioone.org/terms-of-use](https://www.bioone.org/terms-of-use).

Usage of BioOne Complete content is strictly limited to personal, educational, and non - commercial use. Commercial inquiries or rights and permissions requests should be directed to the individual publisher as copyright holder.

---

BioOne sees sustainable scholarly publishing as an inherently collaborative enterprise connecting authors, nonprofit publishers, academic institutions, research libraries, and research funders in the common goal of maximizing access to critical research.

## Gastric Spiral Bacteria in Wild Rats from Italy

Anna Maria Giusti,<sup>1</sup> Luca Crippa,<sup>2</sup> Ornella Bellini,<sup>3</sup> Mario Luini,<sup>3</sup> Eugenio Scanziani,<sup>1</sup> Istituto di Anatomia Patologica Veterinaria e Patologia Aviaria, Università degli Studi di Milano, Via Celoria 10, 20133 Milano, Italy; <sup>2</sup> Safety Department, Research Center, Boehringer Mannheim Italia, 20052 Monza (MI), Italy; <sup>3</sup> Istituto Zooprofilattico Sperimentale della Lombardia e dell'Emilia, Milano, Via Celoria 12, 20133 Milano, Italy

**ABSTRACT:** Forty-three wild rats (*Rattus norvegicus*) trapped in Milan (Italy) were examined for gastric spiral bacteria and to evaluate associated histological lesions. Spiral bacteria were histologically detected in the stomach of 10 rats (23%). The morphological features of these microorganisms, observed using both light and electron microscopy, correspond to those of *Helicobacter heilmannii*. Mild gastritis characterized by focal lymphoplasmacytic infiltration of the lamina propria was observed in six rats with gastric spiral bacteria. Our findings suggest a causal role of these bacteria in inducing a gastric inflammatory response.

**Key words:** Gastric pathology, gastric spiral bacteria, gastritis, *Gastrospirillum*, *Helicobacter heilmannii*, *Rattus norvegicus*, survey, wild rats.

Although spiral-shaped bacteria have been known from the stomach of some animal species since the end of the nineteenth century (Bizzozero, 1893; Salomon, 1896), it was only after the observations of Warren and Marshall (1983), who for the first time described *Helicobacter pylori* infection and its association with gastritis in human beings, that a renewed interest in such bacteria developed in veterinary medicine. Numerous species of spiral-shaped bacteria colonizing the gastrointestinal tract are actually included in the genus *Helicobacter*. They have been described in several animal species including dogs, cats, pigs, cheetahs (*Acinonyx jubatus*), ferrets (*Mustela putorius furo*), mink (*Mustela vison*), baboons (*Papio anubis*) and pig-tailed macaques (*Macaca nemestrina*) (Skirrow, 1994). A relationship between the presence of gastric *Helicobacter* spp. and the development of gastritis has been demonstrated in several cases of naturally or experimentally infected animals (Skirrow, 1994).

Some *Helicobacter* spp. have been described in rodents. *Helicobacter muridarum* and *Helicobacter trogonum* are nat-

ural inhabitants of the intestine of laboratory rats (Phillips and Lee, 1983; Lee et al., 1992; Mendes et al., 1996). *Helicobacter bilis* and *Helicobacter hepaticus* were isolated from livers and intestines of laboratory mice with chronic active hepatitis (Fox et al., 1994, 1995). Until now, few studies have focused on the presence of gastric spiral bacteria in the rat. Salomon (1896) reported the presence of such microorganisms in the rat stomach 100 yr ago, and one case of gastric spirillosis was reported by Kasai and Kobayashi (1919). Germ-free rats have been experimentally infected by *Helicobacter felis*, originally isolated from the cat stomach, and have developed gastric lymphocytic infiltration (Fox et al., 1991). The present study was designed to assess the presence of gastric spiral bacteria in wild rats from an urban area and to evaluate the histological lesions associated with these microorganisms.

Forty-three wild rats (*Rattus norvegicus*) from nine different urban areas of Milan (Italy) (45°28'N, 09°10'E) were captured in Havahart live traps (Woodstream, Lititz, Pennsylvania, USA). All nine areas showed common environmental conditions. Twenty-three males and 20 females, including 32 adults, nine subadults, and two juvenile rats were collected. Rats were categorized by weight as juvenile when <100 g, sub-adult when <100-200 g or adult when >200 g (Webster and Macdonald, 1995). The rats were sent to the laboratory (Istituto Zooprofilattico Sperimentale della Lombardia e dell'Emilia, Milano, Italy), euthanized by inhalation of ether, and necropsied. The stomach was immediately sampled, then fixed in 10% neutral buffered formalin followed by routine embedding in paraffin. Five- $\mu$ m thick histological sections

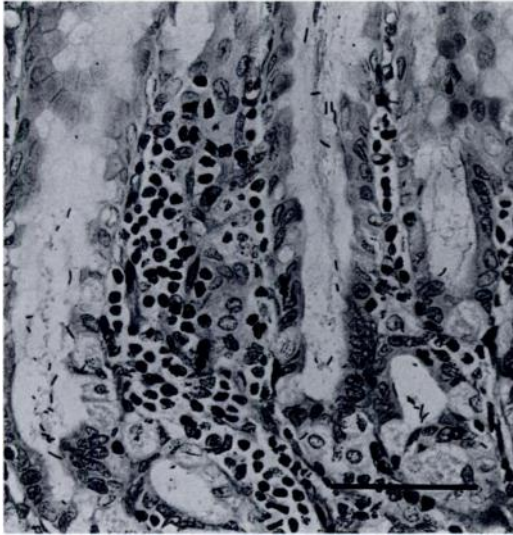


FIGURE 1. Numerous black stained elongated spiral bacteria are visualized within the lumen of gastric glands from a wild rat from Italy. Note the presence of a focal infiltration of lymphocytes in the lamina propria. Warthin-Starry stain. Bar = 70  $\mu\text{m}$ .

were stained with hematoxylin and eosin and with the Warthin-Starry method (Lillie, 1954). Formalin-fixed samples of gastric mucosa from rats with gastric spiral bacteria were processed for methacrylate-resin embedding (Technovit 7100, Kulzer Histo-Technik, Heraeus Kulzer GmbH, Wehrheim, Germany), cut at 1  $\mu\text{m}$  on a Leitz 1516 microtome (Leitz, Wetzlar, Germany) and stained with toluidine blue (Lynn, 1965). Formalin fixed samples of stomach body from two rats with gastric spirilla were post-fixed in 1% buffered osmium tetroxide (Milloning and Marinozzi, 1968) and embedded in Epon-Araldite mixture (Luft, 1965). Ultrathin sections cut at 700  $\text{\AA}$  on a Sorvall MT-2b ultramicrotome (Dupont Instruments, Newton, Connecticut, USA) were stained with lead citrate (Reynolds, 1963) and uranyl acetate (Huxley and Zubay, 1961) and examined with a Zeiss EM 9 transmission electron microscope (Zeiss, Oberchoken, Germany) at 80 kV.

Spiral bacteria were detected in the stomach of 10 of 43 (23%) rats consisting of seven adult males, two adult females,

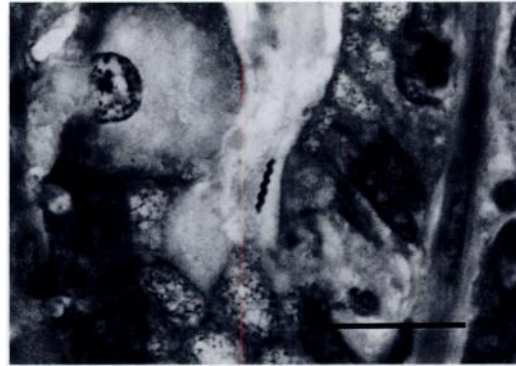


FIGURE 2. A tightly coiled spiral bacterium is present in a gastric glandular lumen of a wild rat from Italy. Methacrylate-resin embedding, toluidine blue. Bar = 25  $\mu\text{m}$ .

and one sub-adult female captured in five different areas. Organisms were easily identifiable in Warthin-Starry stained sections as black spiral bacteria measuring  $\leq 8$   $\mu\text{m}$  long (Fig. 1). The morphological characteristics were better appreciated in toluidine blue stained metacrylate sections, where the bacterial body appeared tightly coiled with several spirals (Fig. 2). Spiral bacteria showed similar dimensions and morphology in all the positive cases. The organisms were widely distributed in the glandular portion of the stomach while they were completely absent in the oesophageal mucosa. Organisms were localized on the surface of the gastric mucosa, in the lumen of foveolae and gastric glands, and in the cytoplasm of parietal cells (Fig. 3). In some instances, parietal cells containing spiral bacteria had pyknotic nuclei and vacuolated cytoplasm. In most cases, one microorganism was detected in a single parietal cell, although cells containing  $\leq 10$  microorganisms also were observed.

Mild gastritis characterized by focal lymphoplasmacytic infiltration in the lamina propria of gastric mucosa was seen in six of 10 rats with spiral bacteria (Fig. 4) and in one of 33 rats without spiral bacteria. Spiral bacteria were not constantly associated with the lymphoplasmacytic foci. In rats with spiral bacteria, other lesions associated to lymphoplasmacytic in-

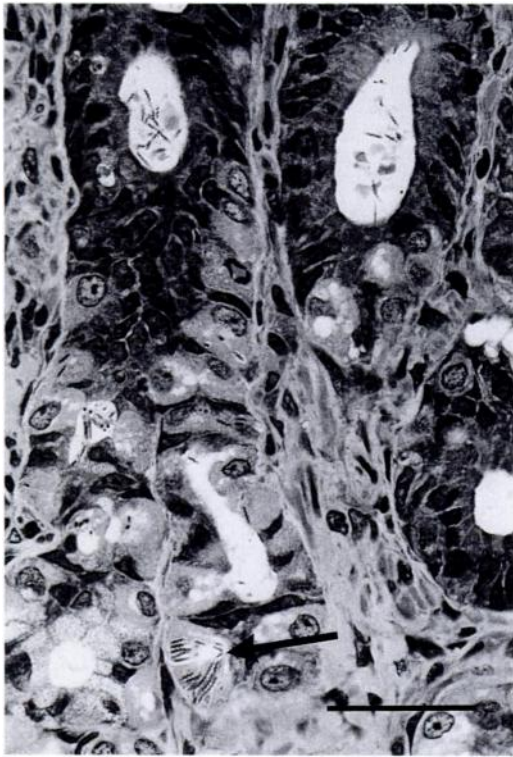

FIGURE 3. Large numbers of spiral shaped bacteria (top) are present deep in the gastric pits of a wild rat. Similar organisms are detected in the cytoplasm of a parietal cell (arrow). Methacrylate-resin embedding, toluidine blue. Bar = 35  $\mu$ m.

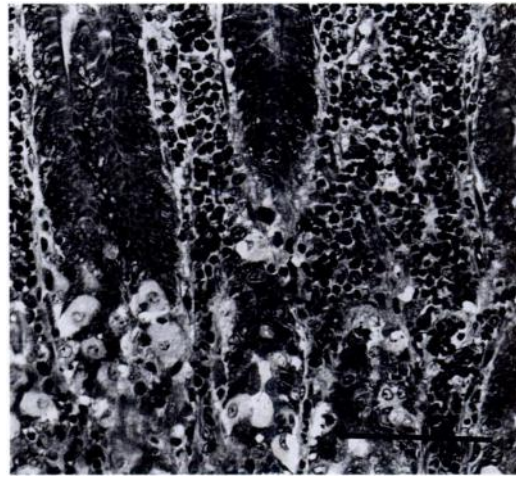


FIGURE 4. Area of lymphoplasmacytic infiltration in the lamina propria of the gastric mucosa of a wild rat infected with *Helicobacter* sp. At the top, hyperplasia of mucus neck cells is present. Methacrylate-resin embedding, toluidine blue. Bar = 100  $\mu$ m.

filtration were lymphoid follicles in the lamina propria in one case, subacute gastric ulcers in one case and hyperplasia of mucus neck cells in another case (Fig. 4). Acute gastric ulcers were present in two rats with no spiral bacteria.

On electron microscopic examination, the spiral bacteria had tightly coiled bodies with  $\leq 8$  coils, a multilaminar enveloping membrane, and numerous polar flagella (Fig. 5). Periplasmic fibers were not observed.

This study demonstrated that wild rats from urban areas frequently harbour spiral bacteria in the stomach. The morphological features of these tightly coiled microorganisms were similar to those of *Helicobacter heilmannii*. The provisional name of *H. heilmannii* has been given to a large, spiral bacteria formerly named *Gastrospi-*

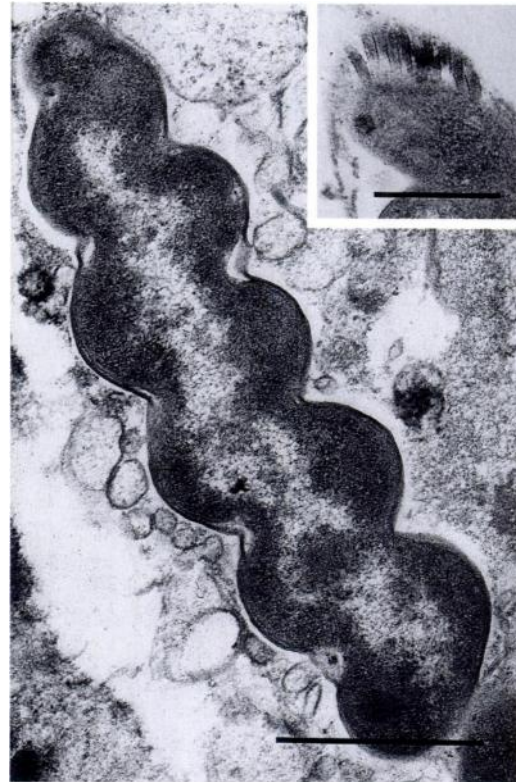

FIGURE 5. Transmission electron micrograph of a tightly coiled bacterium in the stomach of a wild rat. Note the lack of periplasmic fibers. Bar = 1  $\mu$ m. Inset showing the presence of polar flagella on the bacterium. Bar = 0.5  $\mu$ m.

*rillum* sp. or *Gastrospirillum*-like organisms (Dent et al., 1987; Heilmann and Borchard, 1991; Solnick et al. 1993). Unlike other *Helicobacter* spp., most of bacteria morphologically similar to *H. heilmannii* have not been cultured in artificial media and their identification is based on their unique morphologic features. Therefore, their definitive characterization is still lacking. Recently *H. heilmannii*-like organisms have been isolated from the human stomach (Andersen et al., 1995) and from the stomach of dogs. The name *Helicobacter bizzozeroni* has been proposed for this latter organism (Hänninen et al., 1996).

Bacteria morphologically similar to *H. heilmannii* have been observed in the stomach of several species; prevalence rates were 100% in dogs (Weber, 1958; Henry et al., 1987; Hermanns et al., 1995), 76 (Hermanns et al., 1995) to 97% (Otto et al., 1994) in cats, and 62% in swine (Barbosa et al., 1995). *Helicobacter heilmannii* infections also have been reported in humans, although prevalence in patients undergoing endoscopy is <1% (Heilmann and Borchard, 1991). It has been suggested that humans acquire *H. heilmannii* from animals (Solnick et al., 1993; Otto et al., 1994).

In humans, *H. pylori* is associated with chronic active gastritis, gastroduodenal ulcer, and more recently, with gastric adenocarcinoma and gastric mucosa-associated lymphoma (Skirrow, 1994). Chronic gastritis characterized by lymphoplasmacytic mucosal infiltration occasionally associated with lymphoid nodules has been observed in cats (Geyer et al., 1993; Otto et al., 1994), dogs (Henry et al., 1987), pigs (Mendes et al., 1990; Queiroz et al., 1990), and humans (Dent et al., 1987) infected by *H. heilmannii* or by a combination of *Helicobacter* spp., including *H. heilmannii*. Chronic gastritis developed in mice experimentally infected with two different *Helicobacter* spp., most likely *H. felis* and *H. heilmannii* (Eaton et al., 1995). In the present study, similar lesions were observed in the majority of the *H. heilmannii*

infected rats while they were rarely observed in noninfected animals. This suggests a pathogenetic role of *H. heilmannii* in inducing a gastric inflammation. The hyperplastic lesions of mucus neck cells observed in one rat with gastric spiral bacteria were similar to those described in *Gastrospirillum*-like infected mice (Eaton et al., 1995). Gastric ulceration has been associated to *Helicobacter* spp. in humans, pigs (Barbosa et al., 1995) and in experimentally infected mice (Eaton et al., 1995); similar lesions were observed in one infected rat from our study. Acute ulcers were observed in two non-infected animals which probably were trapped several hours before being euthanized. An empty stomach and stress may account for development of such lesions (Senay and Levine, 1967).

The authors wish to thank F. Origgi and O. Sonzogni for their help in capturing and post mortem examination of some of the rats.

#### LITERATURE CITED

- ANDERSEN, L. P., A. NØRGAARD, S. HOLCK, J. BLOM, AND L. ELSBORG. 1995. Isolation of a "*Helicobacter heilmannii*"-like organism from the human stomach. *European Journal of Clinical Microbiology and Infectious Diseases* 15: 95-96.
- BARBOSA, A. J. A., J. C. P. SILVA, A. M. M. F. NOGUEIRA, E. PAULINO JR., AND C. R. MIRANDA. 1995. Higher incidence of *Gastrospirillum* sp. in swine with gastric ulcer of the *pars oesophagea*. *Veterinary Pathology* 32: 134-139.
- BIZZOZERO, G. 1893. Sulla presenza di batteri nelle ghiandole rettali, e nelle ghiandole gastriche del cane. *Atti Reale Accademia delle Scienze di Torino* 2: 249-251.
- DENT, J. C., C. A. M. McNULTY, J. C. UFF, S. P. WILKINSON, AND M. W. L. GEAR. 1987. Spiral organisms in the gastric antrum. *Lancet* ii: 96.
- EATON, K. A., M. J. RADIN, AND S. KRAKOWKA. 1995. An animal model of gastric ulcer due to bacterial gastritis in mice. *Veterinary Pathology* 32: 489-497.
- FOX, J. G., A. LEE, G. OTTO, N. S. TAYLOR, AND J. C. MURPHY. 1991. *Helicobacter felis* gastritis in gnotobiotic rats: An animal model of *Helicobacter pylori* gastritis. *Infection and Immunity* 59: 785-791.
- , F. E. DEWHIRST, J. G. TULLY, B. J. PASTER, L. L. YAN, N. S. TAYLOR, M. J. COLLINS, JR., P. L. GORELICK, AND J. M. WARD. 1994. *Helico-*

- bacter hepaticus* sp. nov., a microaerophilic bacterium isolated from livers and intestinal mucosal scrapings from mice. *Journal of Clinical Microbiology* 32: 1238–1245.
- , L. L. YAN, F. E. DEWHIRST, B. J. PASTER, B. SHAMES, J. C. MURPHY, A. HAYWARD, J. C. BELCHER, AND E. N. MENDES. 1995. *Helicobacter bilis* sp. nov., a novel *Helicobacter* isolated from bile, livers, and intestines of aged, inbred mouse strains. *Journal of Clinical Microbiology* 33: 445–454.
- GEYER, C., F. COLBATZKY, J. LECHNER, AND W. HERMANNNS. 1993. Occurrence of spiral-shaped bacteria in gastric biopsies of dogs and cats. *Veterinary Record* 133: 18–19.
- HANNINEN, M. L., I. HAPPONEN, S. SAARI, AND K. JALAVA. 1996. Culture and characteristics *Helicobacter bizzozeroni*, a new canine gastric *Helicobacter* sp. *International Journal of Systematic Bacteriology* 46: 160–166.
- HEILMANN, K. L., AND F. BORCHARD. 1991. Gastritis due to spiral shaped bacteria other than *Helicobacter pylori*: clinical, histological and ultrastructural findings. *Gut* 32: 137–140.
- HENRY, G. A., P. H. LONG, J. L. BURNS, AND D. L. CHARBONNEAU. 1987. Gastric spirillosis in beagles. *American Journal of Veterinary Research* 48: 831–836.
- HERMANNNS, W., K. KREGEL, W. BREUER, AND J. LECHNER. 1995. *Helicobacter*-like organisms. Histopathological examination of gastric biopsies from dogs and cats. *Journal of Comparative Pathology* 112: 307–318.
- HUXLEY, H. E., AND G. ZUBAY. 1961. Preferential staining of nucleic acid-containing structures for electron microscopy. *Journal of Biophysical and Biochemical Cytology* 11: 273–279.
- KASAI, K., AND R. KOBAYASHI. 1919. The stomach spirochete occurring in mammals. *The Journal of Parasitology* 6: 1–11.
- LEE, A., M. W. PHILLIPS, J. L. O'ROURKE, B. J. PASTER, F. E. DEWHIRST, G. J. FRASER, J. G. FOX, L. I. SLY, P. J. ROMANIUK, T. J. TRUST, AND S. KOUPRACH. 1992. *Helicobacter muridarum* sp. nov., a microaerophilic helical bacterium with a novel ultrastructure isolated from the intestinal mucosa of rodents. *International Journal of Systematic Bacteriology* 42: 27–36.
- LILLIE, R. D. 1954. *Histopathologic technic and practical histochemistry*. The Blakiston Company, Inc., New York, New York, 501 pp.
- LUFT, J. H. 1965. Improvements in epoxy resin embedding methods. *Journal of Biophysical and Biochemical Cytology* 9: 409–415.
- LYNN, J. A. 1965. Rapid toluidine blue staining of Epon-embedded and mounted adjacent sections. *American Journal of Clinical Pathology* 44: 57–63.
- MENDES, E. N., D. M. M. QUEIROZ, G. A. ROCHA, S. B. MOURA, V. H. LEITE AND M. E. F. FONSECA. 1990. Ultrastructure of a spiral microorganism from pig gastric mucosa ("*Gastrospillum suis*"). *Journal of Medical Microbiology* 33: 61–66.
- , F. E. DEWHIRST, B. J. PASTER, B. J., S. B. MOURA, AND J. G. FOX. 1996. *Helicobacter trogontum* sp. nov., isolated from the rat intestine. *International Journal of Systematic Bacteriology* 46: 916–921.
- MILLONIG, G. AND V. MARINOZZI. 1968. Fixation and embedding in electron microscopy. In *Advances in optical and electron microscopy*, R. Barer, and V. E. Cosslett (eds.). Academic Press, New York, New York, p. 251.
- OTTO, G., S. H. HAZELL, C. R. HOWLETT, J. C. MURPHY, J. L. O'ROURKE, AND A. LEE. 1994. Animal and public health implications of gastric colonization of cats by *Helicobacter*-like organisms. *Journal of Clinical Microbiology* 32: 1,043–1,049.
- PHILLIPS, M. W., AND A. LEE. 1983. Isolation and characterization of a spiral bacterium from the crypts of rodent gastrointestinal tracts. *Applied and Environmental Microbiology* 45: 675–683.
- QUEIROZ D. M. M., G. A. ROCHA, E. N. MENDES, A. P. LAGE, A. C. T. CARVALHO, AND A. J. A. BARBOSA. 1990. A spiral microorganism in the stomach of pigs. *Veterinary Microbiology* 24: 199–204.
- REYNOLDS, E. S. 1963. The use of lead citrate at high pH as an electron opaque stain in electron microscopy. *Journal of Cell Biology* 17: 208–214.
- SALOMON, H. 1896. Über das Spirillum des Säugertiermagens und sein Verhalten zu den Belegzellen. *Zentralblatt für Bakteriologie* 19: 433–442.
- SENAY, E. C., AND R. J. LEVINE. 1967. Synergism between cold and restraint for rapid production of stress ulcers in rats. *Proceedings of the Society for Experimental Biology and Medicine* 124: 1,221–1,223.
- SKIRROW, M. B. 1994. Diseases due to *Campylobacter*, *Helicobacter* and related bacteria. *Journal of Comparative Pathology* 111: 113–149.
- SOLNICK, J. V., J. O'ROURKE, A. LEE, B. J. PASTER, F. E. DEWHIRST, AND L. S. TOMPKINS. 1993. An uncultured gastric spiral organism is a newly identified *Helicobacter* in humans. *Journal of Infectious Disease* 168: 379–385.
- WARREN, J. R., AND B. MARSHALL. 1983. Unidentified curved bacilli on gastric epithelium in active chronic gastritis. *Lancet* i: 1,273–1,275.
- WEBER, A. F., O. HASA, AND J. H. SAUTTER. 1958. Some observations concerning the presence of spirilla in the fundic glands of dogs and cats. *American Journal of Veterinary Research* 19: 677–680.
- WEBSTER, J. P., AND D. W. MACDONALD. 1995. Parasites of wild brown rats (*Rattus norvegicus*) on UK farms. *Parasitology* 111: 247–255.

Received for publication 4 December 1996.