

## Lung Parasites of Least Weasels in Finland

Authors: Laakkonen, Juha, Sundell, Janne, and Soveri, Timo

Source: Journal of Wildlife Diseases, 34(4) : 816-819

Published By: Wildlife Disease Association

URL: <https://doi.org/10.7589/0090-3558-34.4.816>

---

The BioOne Digital Library (<https://bioone.org/>) provides worldwide distribution for more than 580 journals and eBooks from BioOne's community of over 150 nonprofit societies, research institutions, and university presses in the biological, ecological, and environmental sciences. The BioOne Digital Library encompasses the flagship aggregation BioOne Complete (<https://bioone.org/subscribe>), the BioOne Complete Archive (<https://bioone.org/archive>), and the BioOne eBooks program offerings ESA eBook Collection (<https://bioone.org/esa-ebooks>) and CSIRO Publishing BioSelect Collection (<https://bioone.org/csiro-ebooks>).

Your use of this PDF, the BioOne Digital Library, and all posted and associated content indicates your acceptance of BioOne's Terms of Use, available at [www.bioone.org/terms-of-use](http://www.bioone.org/terms-of-use).

Usage of BioOne Digital Library content is strictly limited to personal, educational, and non-commercial use. Commercial inquiries or rights and permissions requests should be directed to the individual publisher as copyright holder.

---

BioOne is an innovative nonprofit that sees sustainable scholarly publishing as an inherently collaborative enterprise connecting authors, nonprofit publishers, academic institutions, research libraries, and research funders in the common goal of maximizing access to critical research.

## Lung Parasites of Least Weasels in Finland

Juha Laakkonen,<sup>1</sup> Janne Sundell,<sup>2</sup> and Timo Soveri,<sup>3</sup> <sup>1</sup> Section of Anatomy, Faculty of Veterinary Medicine, P.O. Box 57, FIN-00014 University of Helsinki, Finland (e-mail: Juha.Laakkonen@helsinki.fi); <sup>2</sup> Department of Ecology and Systematics, Division of Population Biology, P.O. Box 17, FIN-00014 University of Helsinki, Helsinki, Finland; and <sup>3</sup> Section of Physiology, Faculty of Veterinary Medicine, P.O. Box 57, FIN-00014 University of Helsinki, Helsinki, Finland.

**ABSTRACT:** Because of their constant exposure to normal rodent definitive hosts, least weasels (*Mustela nivalis*) were trapped in southern Finland in late fall 1994 and examined for lung parasites. Histological examination showed that 46% of the weasels ( $n = 46$ ) were infected with adiaspores identified as *Chrysosporium* sp. Granulomas surrounding the adiaspores consisted of mostly unorganized layers of mononuclear cells. The adiaspores from least weasels were much smaller than those reported from their prey animals. Infection with *Pneumocystis carinii* also was found in two weasels.

**Key words:** *Chrysosporium* sp., lung parasites, *Mustela nivalis*, *Pneumocystis carinii*, survey.

Least weasels (*Mustela nivalis*) are specialized predators of small mammals capable of entering the underground burrows and nests of their prey. In addition to becoming infected with macroparasites using small mammals as intermediate hosts (Jennings et al., 1982), weasels also encounter microparasites that infect their prey animals or that are present in the soil or in the air of the runways. Adiaspiromycosis is a lung disease of animals and rarely of humans, that is relatively widespread in small rodents in Finland (see Jellison, 1969). No information is available on the occurrence of the aetiological agent of adiaspiromycosis (*Chrysosporium parvum* = *Emmonsia parvum*) in mustelids in Finland. Doby and Boisseau-Lebreuil (1971) demonstrated that adiaspores developing in the lungs of prey animals are capable of germination after having passed through the gastrointestinal tract of a weasel. Based on this and their own similar findings Křivanec and Otčenášek (1977) emphasized the importance of mustelid predators in the circulation of *C. parvum*. The aim of this work was to investigate the occurrence

of adiaspiromycosis and other lung parasites in weasels in southern Finland.

During October and November 1994 least weasels were live-trapped at Renko-Loppi near the city of Hämeenlinna (61°00'N, 24°25'E) and in other locations in southern Finland. Forty-six weasels found dead in traps, or later in cages, were stored at –20 C until necropsy in October 1996. Most weasels were immature, but information on their reproductive condition often was not available. The mean weight of the male weasels was 45 g (median 43 g) and that of the females was 30 g (median 30 g). At necropsy, tissue samples from the lungs of each weasel were fixed in 10% buffered formalin, embedded in paraffin and sectioned at 5  $\mu$ m. Four sections of each sample were placed on one slide and stained with hematoxylin-eosin (H&E), Grocott's modification of Gomori's methenamine silver (GMS), and Giemsa stains (Bancroft et al., 1990). The slides were examined by light microscope at  $\times 200$  and  $\times 400$ . The sizes of parasites found in tissue sections were measured with a Cal Comp 2200 digitizer (Digitizer Products Division, Anaheim, California, USA) and a light microscope (Olympus CH, Olympus Optical Co., LTD., Tokyo, Japan), as previously described in Laakkonen and Sukura (1997). Measurements and cell layer counts of granulomas were obtained only from those *Chrysosporium* sp. spores that were sectioned on or near the equatorial plane.

Electron microscopic examination was used to confirm the identification of *Pneumocystis carinii* (see below). For this purpose, 1 mm<sup>3</sup> samples of the formalin-fixed lung tissue of two weasels were cut and fixed for 2 hr in 2.5% glutaraldehyde in

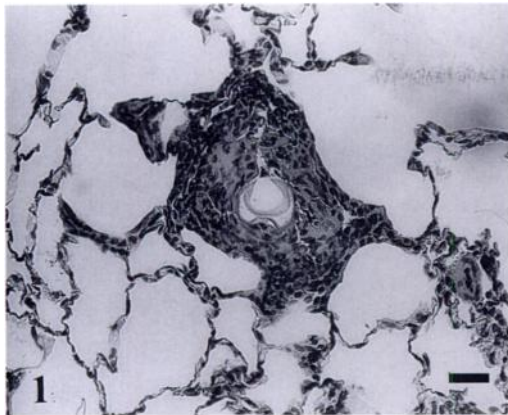


FIGURE 1. Lung section of least weasel from Finland demonstrating a nonnecrotic granuloma typically containing a single adiaspore of *Chrysosporium* sp. of various sizes. Note the partial folding of the wall of the adiaspore. H&E. Bar = 40  $\mu$ m.

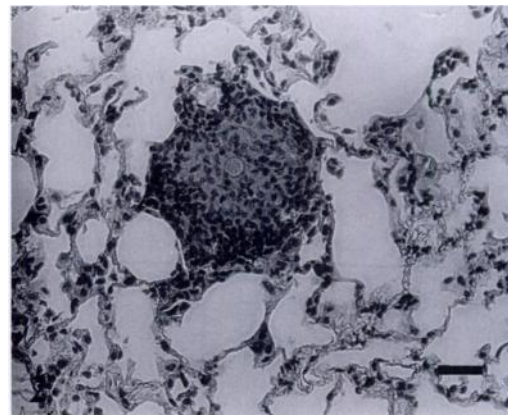


FIGURE 2. Lung section of least weasel from Finland showing an adiaspore with a poorly stained wall in the centre of a granuloma. H&E. Bar = 60  $\mu$ m.

phosphate buffer with  $\text{OsO}_4$  postfixation. After dehydration in acetone, the samples were embedded in LX 112 Epon plastic (Ladd Research Industries, Inc., Burlington, Vermont, USA.) and polymerized. Ultrathin sections were cut of both samples, and the sections were observed with a JEOL JEM 100 S electron microscope (JEOL LTD, Tokyo, Japan).

Spherical organisms with diameters 28 to 64  $\mu$ m were detected in the lungs of 21 (46%) of the 46 weasels. The organisms were identified as *Chrysosporium* sp. based on their size and distinctive appearance in H&E (Fig. 1, 2) and GMS stains (see Chandler et al., 1980). When stained with H&E, the wall of the adiaspore appeared to be composed of two zones: a thick outer zone containing a fenestrated circumferential layer, and a homogeneous inner zone. In GMS stained sections, the entire adiaspore wall was silver-positive but there were zonal differences in staining intensity revealing three zones. Fourteen (58%) of the 24 male and seven (32%) of the 22 female weasels were infected, the difference in prevalence between sexes approached significance (chi-square test,  $P = 0.07$ ; Sokal and Rohlf 1981). In samples of infected individuals, each lung section contained one to two adiaspores surround-

ed by a granuloma (Fig. 1, 2). Granulomas were situated mainly in perialveolar or alveolar positions. One granuloma was surrounded by respiratory epithelium indicating terminal bronchiole and one adiaspore without a granuloma was found free in a bronchiole surrounded by cell-free fluid. Most of the granulomas consisted of 7 to 15 unorganized layers of mononuclear cells (fibroblasts, macrophages, lymphocytes, and plasma cells), although in some cases partial concentric organization of fibroblasts could be observed. No giant cells or polymorphonuclear leucocytes were found in the granulomas.

The high (46%) prevalence of *Chrysosporium* sp. found in wild weasels in southern Finland supports previous studies which showed that this fungus is commonly found in mustelids. Sharapov (1970; cited in Křivanec and Otčenášek, 1977) reported that 55% of mustelids were infected with *C. parvum* in central Siberia. Křivanec and Otčenášek (1977) found the average prevalence of this fungus in eight species of mustelids to be 41% and 32% in least weasels. In contrast, adiaspiromycosis is relatively rarely detected in larger mustelids and other carnivores (Křivanec et al., 1976).

In the present study, the adiaspores found in least weasels were much smaller

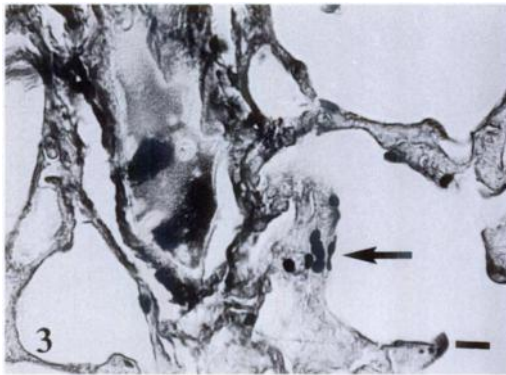


FIGURE 3. Lung section of least weasel from Finland demonstrating cyst forms (arrow) of *Pneumocystis carinii*. H&E. Bar = 9  $\mu$ m.

than those found in small rodents (Jellison, 1969). *Chrysosporium parvum* is known to exist as two varieties: *C. parvum* var. *parvum* with adiaspores achieving diameters of 40  $\mu$ m, and *C. parvum* var. *crescens*, with adiaspores achieving diameters of 400  $\mu$ m (Chandler et al., 1980). The size difference between the adiaspores from least weasels and those from their prey animals raises the question of whether this is due to the occurrence of different varieties of *C. parvum* in the predator and prey species. Alternatively, least weasels may be able to suppress the growth of adiaspores more efficiently than rodents. In addition to the possible dependency on the variety of *C. parvum*, the sizes of the adiaspores depend on the plane in which the spores were cut by the microtome as well as on the developmental stage in which they are found (Chandler et al., 1980). Reasons for the observed differences in size of adiaspores in the various hosts species could be clarified only by inoculation experiments and application of molecular methods in identification of the varieties of *C. parvum*.

Two (4%) of the 46 weasels had organisms resembling the cyst form of *Pneumocystis carinii* in their GMS-stained lung sections (Fig. 3). Electron microscopic examination confirmed the identification of *P. carinii* (Fig. 4). Since no samples were originally obtained and prepared for this

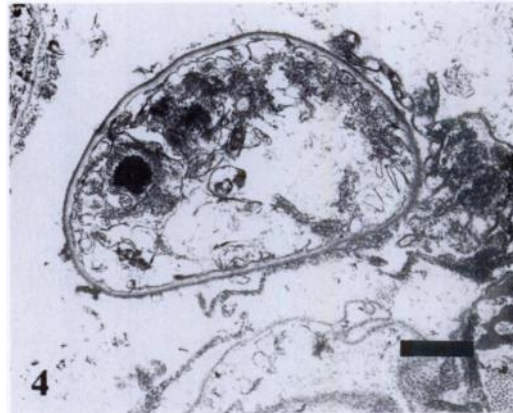


FIGURE 4. Transmission electron micrograph of a cyst form of *Pneumocystis carinii* from least weasel in Finland. The ultrastructure of the cyst is damaged due to the processing of the sample prior to preparation of the electron microscopic sample. Bar = 0.8  $\mu$ m.

purpose, the ultrastructure of the cyst could not be examined in detail. In general, only a few morphological differences have been reported between *P. carinii* from various host species (see Laakkonen and Sukura, 1997).

The mean diameter of the ascus was 4.23  $\mu$ m (SD = 0.30; median 4.21  $\mu$ m,  $n$  = 20). The size of the cyst form of *P. carinii* from least weasels was similar to that of *P. carinii* found in laboratory rats, but it was larger than those seen in shrews and field voles (Laakkonen and Sukura, 1997). It is not presently known whether the size of the cyst form of *P. carinii* varies according to the host species (different species or strains of *P. carinii*), or according to the phase of the infection (e.g., whether the majority of cysts are precysts, immature cysts or mature cysts). In both infected weasels the intensity of *P. carinii* was low, and no signs of acute infection or typical histopathological changes were seen. Adiaspores were not found in the two weasels infected with *P. carinii*.

*Pneumocystis carinii* has not been reported previously in the least weasel. Of other mustelids, the domestic ferret (*Mustela putorius puro*) has been widely used in studies of *P. carinii* infection (Arm-

strong and Cushion, 1994), but Yoshida and Ikai (1979) found the organism in none of the 15 weasels (probably *Mustela sibirica*) examined in Japan.

Because of the small number of parasites in all samples and minimal histopathological changes, the effect of the lung parasites on the condition of an individual weasel appeared insignificant. A potentially large number of adiaspores surrounded by extensive changes in host tissue could be harmful because their mere presence may reduce the area available for gas exchange and also the elasticity of the lungs. However, adiaspores do not multiply in host tissue.

We thank V. Haukisalmi for comments on a previous version of this paper, K. Laakkonen for helping in the translation of the French paper, and students of a mammalogy course for helping in the dissection of the weasels. T. Pankasalo, H. Valtonen and A. Ahonen gave valuable technical assistance.

#### LITERATURE CITED

- ARMSTRONG, M. Y. K., AND M. T. CUSHION. 1994. Animal models. In *Pneumocystis carinii* pneumonia, P. D. Walzer, (ed.). Marcel-Dekker, New York, New York, pp. 181–222.
- BANCROFT, J. D., A. STEVENS, AND D. R. TURNER. 1990. Theory and practice of histological techniques. Churchill Livingstone, Edinburgh, UK, 726 pp.
- CHANDLER, F. W., W. KAPLAN, AND L. AJELLO. 1980. A colour atlas and textbook of the histopathology of mycotic diseases. Wolfe Medical Publications, London, UK, 333 pp.
- DOBY, J. M., AND M. T. BOISSEAU-LEBREUIL. 1971. Rôle possible des animaux sauvages carnassiers (oiseaux et mammifères) dans la dissémination mécanique de l'adiaspiromycose par *Emmonsia crescens* Emmons et jellison, 1960, dans la nature. Comptes Rendus des Seances de la Société de Biologie de Rennes 165: 1119–1122.
- JELLISON, W. L. 1969. Adiaspiromycosis (= Haplomycosis). Mountain Press, Missoula, Montana, 99 pp.
- JENNINGS, D. H., W. THRELFALL, AND D. G. DODDS. 1982. Metazoan parasites and food of short-tailed weasels and mink in Newfoundland, Canada. Canadian Journal of Zoology 60: 180–183.
- KŘIVANEC, K., M. OTČENÁŠEK, AND J. ŠLAIS. 1976. Adiaspiromycosis in large free-living carnivores. Mycopathologia 58: 21–25.
- , ———, AND ———. 1977. Importance of free-living mustelid carnivores in circulation of adiaspiromycosis. Mycopathologia 60: 139–144.
- LAAKKONEN, J., AND A. SUKURA. 1997. *Pneumocystis carinii* of the common shrew, *Sorex araneus*, shows a discrete phenotype. Journal of Eukaryotic Microbiology 44: 117–121.
- SOKAL, R. R., AND F. J. ROHLF. 1981. Biometry. 2nd Edition. Freeman, San Francisco, California, 859 pp.
- YOSHIDA, Y., AND T. IKAI. 1979. *Pneumocystis carinii* pneumonia: epidemiology in Japan and cyst concentration method. Zentralblatt für Bakteriologie, Microbiologie und Hygiene. Series A 244: 405–410.

Received for publication 1 October 1997.