

SYNOVIAL JOINT DISEASE IN WILD CETACEANS

Authors: Turnbull, Beth S., and Cowan, Daniel F.

Source: Journal of Wildlife Diseases, 35(3) : 511-518

Published By: Wildlife Disease Association

URL: <https://doi.org/10.7589/0090-3558-35.3.511>

BioOne Complete (complete.BioOne.org) is a full-text database of 200 subscribed and open-access titles in the biological, ecological, and environmental sciences published by nonprofit societies, associations, museums, institutions, and presses.

Your use of this PDF, the BioOne Complete website, and all posted and associated content indicates your acceptance of BioOne's Terms of Use, available at www.bioone.org/terms-of-use.

Usage of BioOne Complete content is strictly limited to personal, educational, and non - commercial use. Commercial inquiries or rights and permissions requests should be directed to the individual publisher as copyright holder.

BioOne sees sustainable scholarly publishing as an inherently collaborative enterprise connecting authors, nonprofit publishers, academic institutions, research libraries, and research funders in the common goal of maximizing access to critical research.

SYNOVIAL JOINT DISEASE IN WILD CETACEANS

Beth S. Turnbull,^{1,3} and Daniel F. Cowan,^{1,2,3,4}

¹ Department of Pathology, University of Texas Medical Branch, Galveston, Texas 77555, USA

² Marine Biomedical Institute, University of Texas Medical Branch, Galveston, Texas 77555, USA

³ Texas Marine Mammal Stranding Network, Galveston, Texas 77551, USA

⁴ Corresponding author (E-mail: dcowan@utmb.edu)

ABSTRACT: During necropsy of cetaceans stranded or accidentally net-captured along the western coast of the Gulf of Mexico from 1991 to 1996, we found 13 of 59 (22%) animals had abnormalities of the atlanto-occipital and/or humeroscapular joints, the synovial joints. A few cases demonstrated mild roughening of the articular cartilage, while the majority exhibited complete erosion with thickened synovium and bony proliferation. The lesions resulted in ankylosis of both joints in one animal. In humans and terrestrial mammals, synovial joint diseases are known to be debilitating. Cetaceans depend on neck and flipper movement for locomotion, feeding, avoiding danger, and reaching the water's surface for breathing. Therefore, synovial joint disease may be a significant mortality factor in these marine animals.

Key words: Arthritis, cetacean, joint disease, survey, synovial joints.

INTRODUCTION

In mammals, diarthrodial or synovial joints are characterized by a free and often wide range of motion. These joints normally have excellent friction, lubrication, and wear properties, and they facilitate movement and locomotion. Articular hyaline cartilage covers the ends of the bones and provides a wear-resistant surface that allows one end of the joint to move efficiently over the other (Lane and Buckwater, 1993). Destruction of this articular cartilage may result in progressive and sometimes severe limitations in joint function and body movement.

Terrestrial mammals have several sets of synovial joints that are adapted for movement and weight bearing stress. In contrast, the synovial joints in cetaceans (dolphins and whales) consist of the atlanto-occipital, humeroscapular, small apophyseal joints of the vertebrae, and articulations of the cranial-most ribs (Rommel, 1990). The two major joints, the atlanto-occipital and humeroscapular, are adapted for movement but are not weight-bearing joints as in terrestrial mammals. Cetaceans are supported by water; therefore, the pressure in their joints is applied by adjacent muscle, not by bearing body weight.

Disorders involving the synovial joints have been identified in terrestrial mam-

mals. These joint disorders may be broadly classified into pathogenetic categories, non-inflammatory and inflammatory. The non-inflammatory category includes degenerative joint disease, traumatic joint disease, and developmental, dietary, metabolic, and neoplastic arthropathies. The inflammatory category includes infectious (bacterial, viral, fungal, protozoal) and noninfectious (immunologic, crystal-induced) arthritis (Pedersen et al., 1989). Differentiating between the non-inflammatory and inflammatory types of joint disorders can be complex, as non-inflammatory disorders may be accompanied by secondary inflammation, and inflammatory disorders commonly result in secondary, often severe degenerative changes. However, the inflammatory types of joint disease are typically characterized by systemic signs of illness.

Bone lesions such as osteomyelitis of the flippers and vertebrae, infectious and rheumatoid spondylitis, and spondylosis are well recognized in cetaceans (Cowan, 1966; Lagier, 1977; Morton, 1978; Foley, 1979; Paterson, 1984; Alexander et al., 1989). However, we have not found descriptions of disorders of the synovial joints of cetaceans. Herein the gross and light microscopic findings of synovial joint disorders found in cetaceans stranded along the western coast of the Gulf of Mexico are reported.

TABLE 1. Historical, clinical, and pathological findings in cetaceans with joint disease from the Western Gulf of Mexico.

Case number	Sex	Tooth age (yr)	Species	Type of joint disease	Joint involvement			Severity of joint disease ^d	Joint culture	Blood culture
					AO ^a	LHS ^b	RHS ^c			
1	F ^e	ND ⁱ	<i>Lagenodelphis hosei</i>	Infectious	—	+	+	Severe	Positive	Positive
2	IM ^f	ND	<i>Tursiops truncatus</i>	Degenerative	+	NE ^j	NE	Severe	NC ^k	Negative
3	IF ^g	9	<i>Tursiops truncatus</i>	Degenerative	+	+	NE	Severe	NC	Positive
4	F	11	<i>Tursiops truncatus</i>	Infectious	+	+	—	Severe	Negative	Positive
5	IM	3.5	<i>Tursiops truncatus</i>	Infectious	+	—	—	Severe	NC	NC
6	M ^h	24	<i>Tursiops truncatus</i>	Degenerative	+	+	—	Severe	Negative	Positive
7	F	13	<i>Tursiops truncatus</i>	Infectious	—	+	—	Mild	Positive	Positive
8	M	17	<i>Tursiops truncatus</i>	Degenerative	—	+	—	Severe	NC	Positive
9	F	ND	<i>Stenella attenuata</i>	Degenerative	+	—	—	Mild	NC	Positive
10	M	23	<i>Tursiops truncatus</i>	Degenerative	NE	+	NE	Severe	NC	NC
11	M	ND	<i>Kogia breviceps</i>	Degenerative	+	NE	NE	Severe	NC	NC
12	M	14	<i>Tursiops truncatus</i>	Degenerative	—	+	—	Severe	Negative	Positive
13	IF	7	<i>Tursiops truncatus</i>	Infectious	+	+	+	Severe	NC	NC

^a Atlantooccipital joint.^b Left humeroscapular joint.^c Right humeroscapular joint.^d Mild roughening of the articular cartilage versus severe erosion of the articular cartilage with thickened synovium and destruction of bone.^e Mature female.^f Immature male.^g Immature female.^h Mature male.ⁱ Not determined.^j Not examined.^k Not cultured.

MATERIALS AND METHODS

Animals in this study

The cetaceans in this study were stranded or accidentally net-captured animals collected between April 1991 and November 1996 by the Texas Marine Mammal Stranding Network (Galveston, Texas, USA), under the auspices of the National Marine Fisheries Service (Silver Spring, Maryland, USA). The collection area ranged in the south from Cameron County (Texas, USA; 25°57'N, 97°09'W) at the Mexican border to the north in Cameron County (Louisiana, USA; 29°30'N, 92°40'W).

Fifty-nine cetaceans without obvious bloating or decay were examined: 49 Atlantic bottlenose dolphins (*Tursiops truncatus*), one Fraser's dolphin (*Lagenodelphis hosei*), one striped dolphin (*Stenella coeruleoalba*), two spotted dolphins (*Stenella attenuata*), one short-finned pilot whale (*Globicephala macrorhynchus*), one rough-toothed dolphin (*Steno bredanensis*), one infant sperm whale (*Physeter macrocephalus*), one false killer whale (*Pseudorca crassidens*), one pygmy sperm whale (*Kogia breviceps*), and one Antillean beaked whale (*Mesoplodon europaeus*).

Selection and sampling

The animals were taken to a central laboratory at Texas A&M University (Galveston, Texas) for post-mortem examination, microbiological testing, and histological sampling of all organs and tissues. The atlanto-occipital joint and at least one, but usually both humeroscapular joints were examined grossly.

Blood cultures were aspirated from the hearts of animals in which the blood had not clotted prior to necropsy. Eight to 10 ml of blood were placed in BACTEC Plus Aerobic F and BACTEC standard Anaerobic F culture vials (Becton Dickinson Diagnostic Instrument Systems, Sparks, Maryland, USA) and monitored by the BACTEC 9240 automated detection system for up to 7 days. Aerobic gram positive cocci and bacilli were plated onto blood agar, while anaerobic gram positive cocci and bacilli were plated onto a 5% trypticase soy agar with 5% sheep blood and a Brucella blood agar with hemin and vitamin K1. Aerobic gram negative bacilli were plated onto blood agar, chocolate agar, and MacConkey agar, while anaerobic gram negative bacilli were plated onto blood agar and Brucella blood agar with hemin

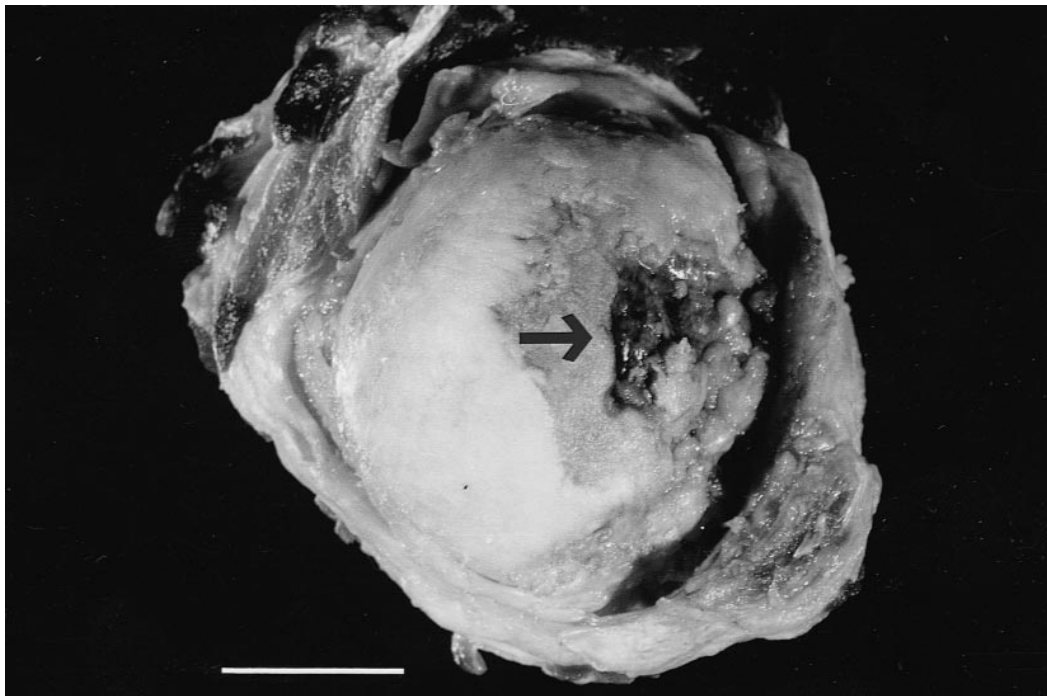


FIGURE 1. Case 6, 24-yr-old mature male *Tursiops truncatus* (Atlantic bottlenose dolphin). Head of the left humerus with an extensively and deeply eroded articular surface, and exposure of underlying bone (arrow). Histologically, this is typical of degenerative arthritis. Bar = 2 cm.

and vitamin K1. Aerobic plates were incubated at 35 C in 5% CO₂ for 24 to 48 hr and anaerobic plates were incubated at 35 C in 5% H₂, 10% CO₂, and 85% N₂ for 48 hr until sufficient growth was present. Aerobic gram positive cocci growth was tested with catalase. Catalase positive cocci were tested with a rapid slide latex agglutination procedure (Staphaurex, Murex Biotech Limited, Dartford, UK). Catalase negative cocci were tested with a slide latex agglutination assay for categorization into *Streptococcus* Lancefield groups A, B, C, F, or G (PathoDx, Diagnostic Products Corp., Los Angeles, California, USA) or a Vitek GPI card (BioMerieux Vitek, Hazelwood, Missouri, USA) was inoculated to identify *Streptococcus* Group D or *Enterococcus* spp. Anaerobic gram negative bacilli were identified as *Edwardsiella* spp., *Enterobacter* spp., *Pasteurella* spp., *Pleisiomonas* spp., *Pseudomonas* spp., or *Vibrio* spp. using the Vitek automated identification and susceptibility system. Anaerobic gram positive or gram variable bacilli were identified using the RapID ANA II System (Remel, Norcross, Georgia, USA).

Joints appearing septic were swabbed with sterile culturettes. Aerobic cultures were inoculated to trypticase soy agar with 5% sheep

blood, chocolate agar, MacConkey agar, and thioglycolate broth. Anaerobic cultures were inoculated to Brucella blood agar with hemin and vitamin K1 and CDC anaerobe laked blood agar with kanamycin and vancomycin. Incubation conditions and identification procedures for bacteria were the same as for blood cultures. Fungal cultures were inoculated to brain heart infusion agar and inhibitory mold agar (Becton-Dickinson) and incubated at 30 C for up to 3 wks.

Sections for routine histology were taken from the synovium, cartilage, and bone of each joint. Tissue samples were fixed in 10% neutral buffered formalin, decalcified when necessary, dehydrated through a graded series of alcohol solutions, embedded in paraffin, sectioned at 5 µm, and stained with hematoxylin and eosin (H&E) or hematoxylin, phloxine and saffron (HPS), a trichrome stain used mainly to discriminate muscle from collagen (Preece, 1972).

Diagnosis of joint disease

The diagnosis of joint disease in the cetaceans was made during gross and histological examination. The animals were typically found stranded dead or died shortly after stranding

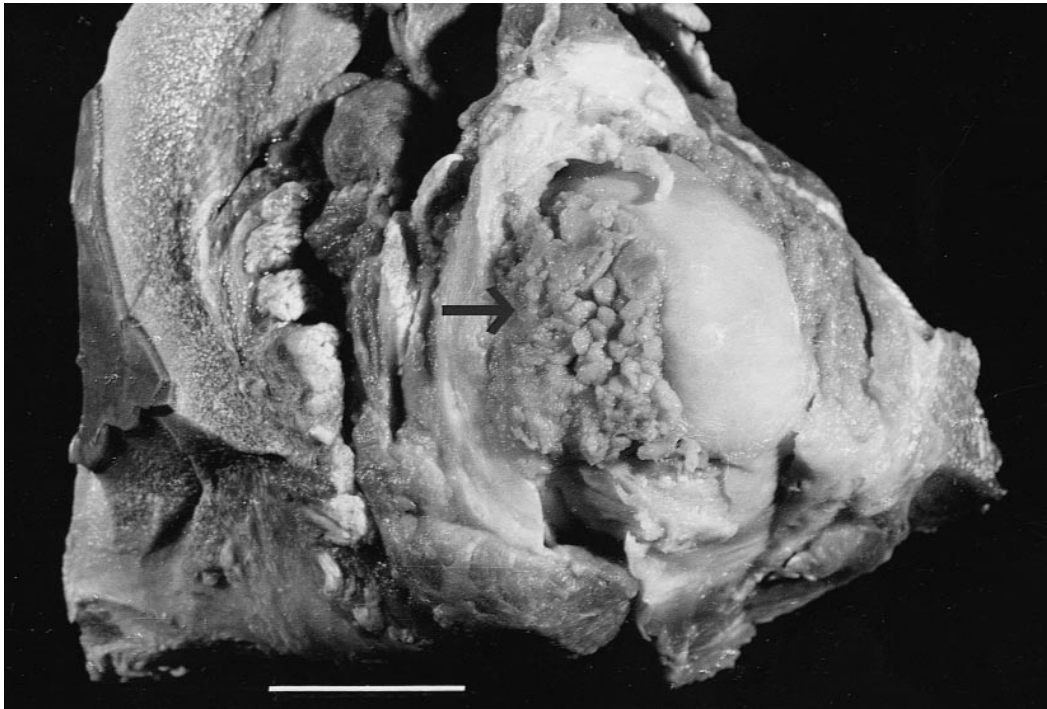


FIGURE 2. Case 10, 23-yr-old mature male *Tursiops truncatus*. Head of the left humerus with marked villous thickening of the synovium covering a deeply eroded articular surface (arrow). Histologically, this is typical of degenerative arthritis. Bar = 2 cm.

and thus no clinical information was available. Therefore, the joint lesions were classified on a morphological basis, occasionally supplemented by microbiologic cultures. Diagnostic criteria used to differentiate degenerative joint disease and infectious inflammatory arthritis were those described by Pedersen et al. (1989).

Lesions were diagnosed as degenerative joint disease when one or more joints displayed degeneration of articular cartilage with eburnation of subchondral bone, outgrowths of marginal osteophytes, sclerosis, and/or changes in the synovial membrane. Histologically, there may have been fibrillation and erosion of the articular cartilage, fissuring or flaking of the articular cartilage and subchondral bone, villous hypertrophy and fibrosis of the synovial membrane, and/or bone proliferation at the joint margins. Acute inflammation was absent while mild chronic inflammatory changes may have been present (Pedersen et al., 1989).

Lesions were diagnosed as infectious inflammatory arthritis when destructive and aggressive inflammatory changes in the synovial membrane were present in one joint or several joints with or without fibrous and bony ankylosis. The joint space was typically narrowed due to cartilage erosion and formation of granulation tis-

sue in the synovium. Histologically, fragments of bone or cartilage may have been incorporated into the synovium that was infiltrated with polymorphonuclear leukocytes, lymphocytes, plasma cells, and histiocytes (Pedersen et al., 1989).

The lesions were classified as mild, moderate, or severe depending upon the extent of the gross and histological changes. Mild joint disease was diagnosed with roughening or erosion of the articular cartilage, involving part or all of a joint. Severe joint disease was diagnosed with deep erosion of the articular cartilage, destruction of the bony articular plate, and alteration of the shape of the joint, with or without fusion.

Sexual maturity and tooth aging

Sexual maturity of the animals in this study was determined by histological examination of the testes or ovaries. Males with mature spermatogenic cells and spermatozoa in the seminiferous tubules were considered sexually mature. Females with mature ovarian follicles, corpus luteum, or corpus albicans were considered sexually mature.

Tooth ages were determined for 29 of the animals by the method described by Hohn et

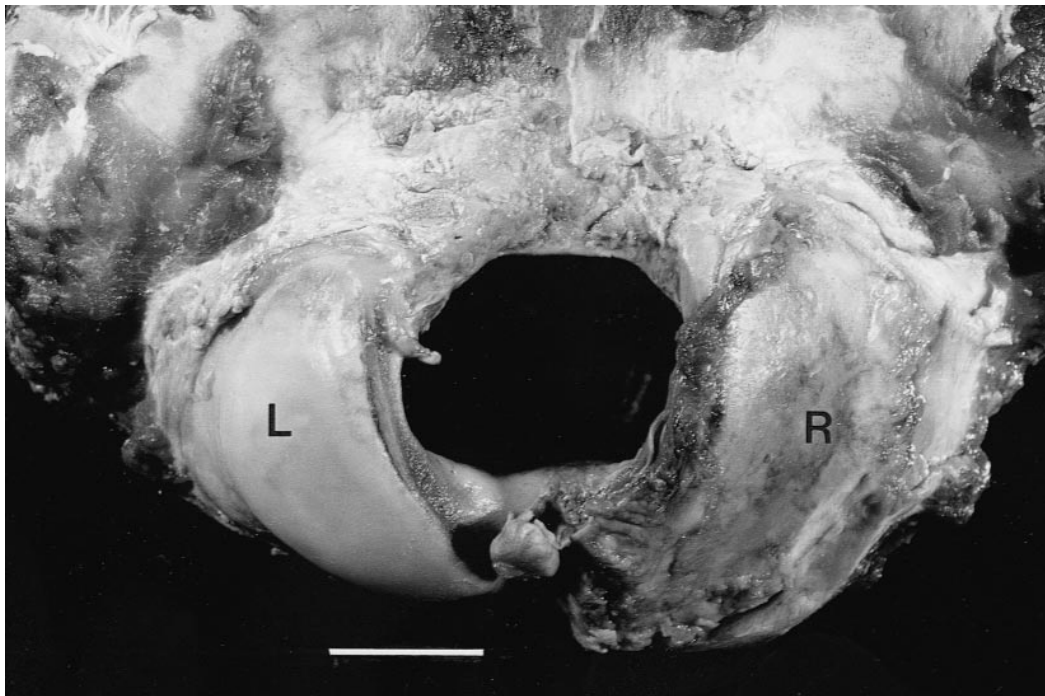


FIGURE 3. Case 3, 9-yr-old immature female *Tursiops truncatus*. Occipital condyles with complete loss of articular surface of the right condyle (R). The articular plate is thickened and rough. Histologically this is typical of degenerative arthritis. The left condyle (L) appears normal. The opposing surface of the atlas showed similar changes. Bar = 2 cm.

al. (1989). Teeth were extracted from the dolphins at necropsy, preserved in formalin, stored in 100% glycerin, thick-sectioned at 2 to 3 mm, decalcified, thin-sectioned at 25 μ m, and stained with hematoxylin. A compound microscope was used to count the repeating patterns of dentinal laminations, or growth layer groups (GLG), a minimum of five times to insure accuracy.

RESULTS

Joint disorders in the atlanto-occipital and/or humeroscapular joints were identified in 13 of 59 (22%) of animals. The gross, histological, and microbiological findings revealed that degenerative joint disease was present in eight animals, while infectious arthritis was present in five animals. Historical, clinical, and pathological findings are tabulated (Table 1).

Gross appearance of the joint lesions ranged from mild roughening of the articular cartilage in two animals (cases 7 and 9) to complete erosion of the articular car-

tilage in the other 11 animals (Figs. 1–4). In the severe cases, the synovium was thickened, and there was destruction of bone causing defects and deformities. Case 13 had ankylosis of the atlanto-occipital and humeroscapular joints. Cases 6 and 11 not only had erosive lesions of the atlanto-occipital and humeroscapular joints but also had spondylitis involving the costo-vertebral joints or the cervical vertebrae.

Histological examination of the joint lesions of cases 2, 3, 6, 8, 9, 10, 11, and 12 revealed degenerative joint disease with chondrocyte proliferation, synovial inflammation with villous hypertrophy (Fig. 5), flaking and fibrillation, vertical fissures, eburnation, sclerosis, and/or osteophytes. Formation of cystic cavities beneath the articular plate were found in one animal (Fig. 6). Histological examination of the joint lesions of cases 1, 4, 5, 7, and 13 revealed infectious arthritis with inflamma-

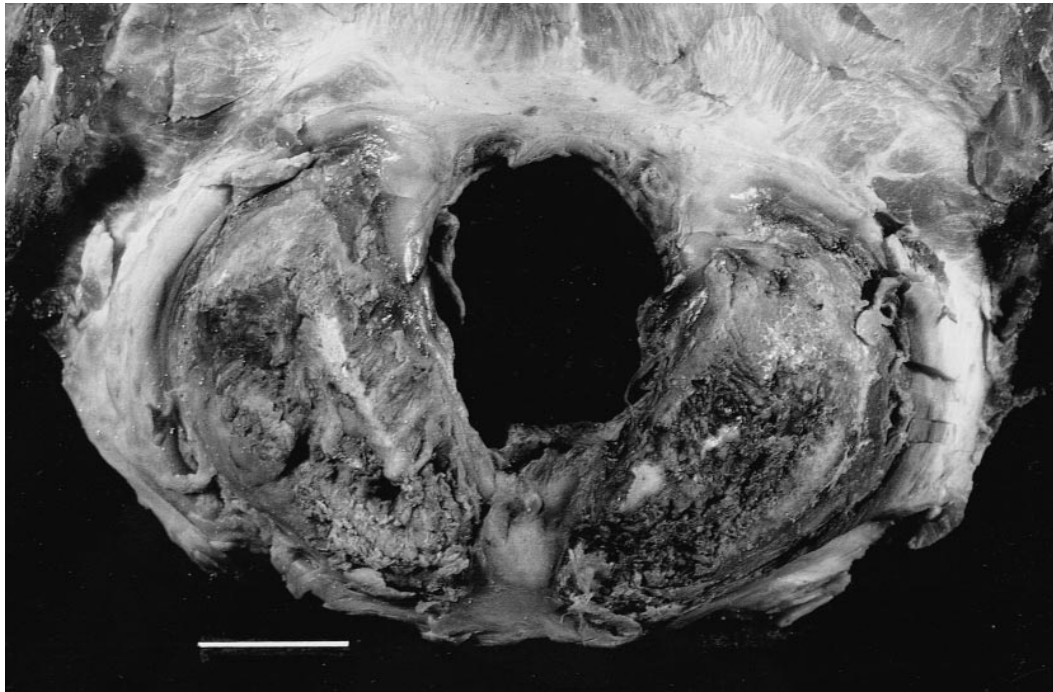


FIGURE 4. Case 10, 23-yr-old mature male *Tursiops truncatus*. Occipital condyles with complete loss of both the right and left articular surfaces, with destruction of the underlying articular plates. Histologically this is typical of degenerative arthritis. The opposing surface of the atlas showed similar changes. Bar = 2 cm.

tion and necrosis of bone, hyperemic and edematous synovium, polymorphonuclear leukocytes, lymphocytes, fibrocytes, and/or histiocytes (Fig. 7).

Bacteriological cultures from affected animals were obtained from joint lesions, venous blood, and/or other tissues (intes-

tine, lung, air sinus, cerebrospinal fluid, and/or abscesses). Two of five atlanto-occipital and/or humeroscapular joint cultures were positive for *Vibrio alginolyticus* or *Edwardsiella tarda*. The left humeroscapular joint of case 4 was distended with

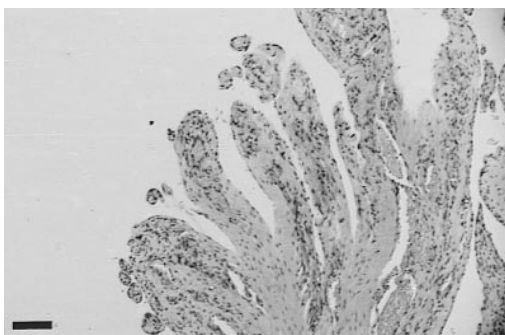


FIGURE 5. Case 6, 24-yr-old mature male *Tursiops truncatus*. Section of the synovium of the right humeroscapular joint with villous thickening, fibrosis, and mild inflammatory infiltrate. This is typical of degenerative arthritis. HPS stain. Bar = 100 μ m.

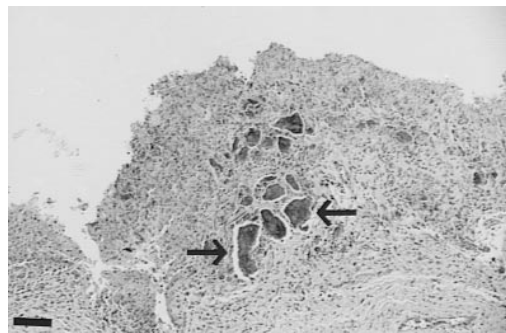


FIGURE 6. Case 4, 11-yr-old mature female *Tursiops truncatus*. Section of the synovium of the atlanto-occipital joint with marked inflammation and embedded fragments of bone (arrow) from the articular plate. This is typical of infectious arthritis. HPS stain. Bar = 100 μ m.

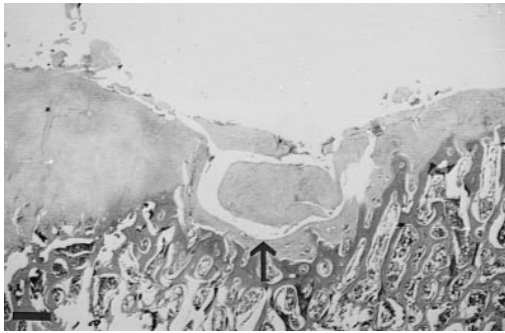


FIGURE 7. Case 11, mature male *Kogia breviceps* (pygmy sperm whale). Section of the articular surface of the atlanto-occipital joint with extensive erosion of the articular cartilage and formation of a cystic space beneath the articular plate (arrow). This is typical of degenerative arthritis. HPS stain. Bar = 50 μ m.

a purulent exudate; however, bacteriological cultures were negative. Eight of nine venous blood and tissue cultures were positive for an array of microorganisms including bacteria such as *Bacillus*, *Clostridium*, *Edwardsiella*, *Enterobacter*, *Pasteurella*, *Plesiomonas*, *Pseudomonas*, *Staphylococcus*, *Streptococcus*, and/or *Vibrio*.

DISCUSSION

Degenerative joint disease (also known as osteoarthritis or osteoarthrosis), a non-inflammatory arthritis, is common in most domestic mammals (Jubb et al., 1985), numerous species of wild mammals (Fox, 1939), and in millions of adult humans (McKeag, 1992). It was identified in eight cetaceans in this study. Many factors have been implicated in the pathogenesis of degenerative joint disease including increasing age, obesity, genetics, abnormal joint alignment, ligamentous instability, excessive stress, prior injury, decreased bone growth/remodeling, decreased joint lubrication, local inflammation, hormonal influences, and neuromuscular abnormalities (McKeag, 1992; Lane and Buckwalter, 1993; O'Connor and Brandt, 1993). Unlike terrestrial mammals, cetaceans live in a buoyant, weight supporting medium and consequently do not bear excessive weight on their joints. Therefore, joint stress was probably not involved in the etiology of

the degenerative lesions. In addition, two of the cetaceans included in this study which had degenerative joint disease were sexually immature. Thus, aging and obesity were not likely to have played a role in the development of the degenerative lesions in the joints of these two animals.

Five of the cetaceans included in this study had gross and histological changes consistent with infectious joint disease; although, only two of these animals had positive bacteriological joint cultures. These findings are similar to those observed in humans where cultures and gram stains of synovial tissue or joint effusions typically identify only one third of infectious arthritis cases (Smith and Piercy, 1995).

Synovial joint disease was found in 22% of the cetaceans stranded along the western coast of the Gulf of Mexico during the years 1991–96. The joint lesions in these cetaceans were similar to that seen in humans and terrestrial animals where the clinical presentation includes limitation of joint movement and pain. Therefore, we can postulate that the cetaceans had similar clinical symptoms. These symptoms could potentially lead to the demise of the animals which depend on neck and flipper movement for feeding, avoiding danger, and reaching the water's surface for breathing. However, even though the marine environment is exceptionally demanding, allowing no respite such as that which might be available to a terrestrial mammal, cetaceans are able to survive long enough for advanced disease, including bony ankylosis, to develop. Nevertheless, we expect that synovial joint disease in cetaceans is a life-shortening phenomenon.

The classification of joint disease used here to categorize the lesions in the cetaceans must be taken as a hypothesis for testing for several reasons. First, no other cases of cetacean synovial joint disease have been reported in the literature. Second, all of the cetaceans in this study stranded dead or died shortly after stranding; therefore, no historical or clinical supporting information, other than microbio-

logical cultures, was available. Finally, although cetaceans are nonweight-bearing aquatic mammals, the criteria used to classify their joint lesions were the same as those which are used to classify joint lesions in weight-bearing terrestrial mammals.

ACKNOWLEDGMENTS

We thank J. P. Turner for determining dental ages of some of the animals; M. B. Smith for microbiological consultation; L. S. Clark, E. M. Haubold, and the Texas Marine Mammal Stranding Network; and T. Bednarek for photography. This work was supported by grant #NA16RGO457-01 from the National Oceanic and Atmospheric Administration through the National Sea Grant College Program, in part by grant MX822147-01-0 from the Environmental Protection Agency Gulf of Mexico Program, and in part by grant #T35 ES07294 from the National Institutes of Environmental Health Sciences Toxicology Training Grant.

LITERATURE CITED

- ALEXANDER, J. W., M. A. SOLANGI, AND L. S. RIEGEL. 1989. Vertebral osteomyelitis and suspected diskospondylitis in an Atlantic bottlenose dolphin (*Tursiops truncatus*). *Journal of Wildlife Diseases* 25: 118–121.
- COWAN, D. F. 1966. Pathology of pilot whale (*Globicephala melaena*), a comparative study. *Archives of Pathology* 82: 178–189.
- FOLEY, R. H. 1979. Osteomyelitis of the flipper of a bottle-nosed dolphin. *Journal of the American Veterinary Medical Association* 175: 999.
- FOX, H. 1939. Chronic arthritis in wild mammals. *Transactions of the American Philosophical Society* 31: 73–124.
- HOHN, A. A., M. D. SCOTT, R. S. WELLS, J. S. SWEE-
NY, AND A. B. IRVINE. 1989. Growth layers in
teeth from known age, free-ranging bottlenose
dolphins. *Marine Mammal Science* 5: 315–342.
- JUBB, K. V. F., P. C. KENNEDY, AND N. PALMER. 1985. *Pathology of domestic animals*, Vol. 1. 3rd Edition. Academic Press Inc., San Diego, California, 574 pp.
- LAGIER, R. 1977. Spondylosis in the whale—an anatomicoradiological study of an osteophyte. *Scandinavian Journal of Rheumatology* 6: 245–249.
- LANE, N. E., AND J. A. BUCKWALTER. 1993. Exercise: a cause of osteoarthritis? *Rheumatic Disease Clinics of North America* 19: 617–633.
- MCKEAG, D. B. 1992. The relationship of osteoarthritis and exercise. *Clinics in Sports Medicine* 11: 471–487.
- MORTON, B. 1978. Osteomyelitis (pyogenic spondylitis) of the spine in a dolphin. *Journal of the American Veterinary Medical Association* 173: 1119–1120.
- O'CONNOR, B. L., AND K. D. BRANDT. 1993. Neurogenic factors in the etiopathogenesis of osteoarthritis. *Rheumatic Disease Clinics of North America* 19: 581–605.
- PATERSON, R. A. 1984. Spondylitis deformans in a Byrde's whale (*Balaenoptera edeni* Anderson) stranded on the southern coast of Queensland. *Journal of Wildlife Diseases* 20: 250–252.
- PEDERSEN, N. C., A. WIND, J. P. MORGAN, AND R. R. POOL. 1989. Joint Disease of Dogs and Cats. *In* *Textbook of veterinary internal medicine*. Vol. 2. 3rd Edition. S. J. Ettinger (ed.). W. B. Saunders, Philadelphia, Pennsylvania, pp. 2329–2377.
- PREECE, A. 1972. *A manual for histologic technicians*, 3rd Edition. Little Brown & Company, Boston, Massachusetts, 428 pp.
- ROMMEL, S. 1990. Osteology of the bottlenose dolphin. *In* *The bottlenose dolphin*, S. Leatherwood and R. R. Reeves, (eds.). Academic Press, San Diego, California, pp. 29–49.
- SMITH, J. W., AND E. A. PIERCY. 1995. Infectious arthritis. *Clinical Infectious Diseases* 20: 225–231.

Received for publication 7 October 1998.