

Systemic Sarcocystosis in a Wild Turkey from Georgia

J. P. Dubey,¹ C. F. Quist,^{2,4} and D. L. Fritz³ ¹ Parasite Biology and Epidemiology Laboratory, Livestock and Poultry Sciences Institute, United States Department of Agriculture, Agricultural Research Service, Beltsville, Maryland 20705-2350, USA; ² Southeastern Cooperative Wildlife Disease Study, College of Veterinary Medicine, The University of Georgia, Athens, Georgia 30602, USA; ³ Pathology Division, U.S. Army Medical Research Institute of Infectious Disease, 1425 Porter Street, Fort Detrick, Maryland 21702-8011, USA; ⁴ Corresponding author (e-mail: cqquist@cvm.vet.uga.edu).

ABSTRACT: Acute sarcocystosis was diagnosed in an adult female wild turkey (*Meleagris gallopavo*) that was collected from Early County (Georgia, USA) in February of 1998. Marked inflammatory lesions were seen in the heart, lung, and liver and were associated with protozoal schizonts and merozoites. The organisms were identified as *Sarcocystis* sp. (Acomplexa: Sarcocystidae) based on structure and antigenicity. Protozoa divided by endopolygony, merozoites lacked rhoptries, and the organisms did not react to anti-*S. falcatula* antibodies but reacted to anti-*S. cruzi* antibodies.

Key words: Acute sarcocystosis, case report, *Meleagris gallopavo silvestris*, myocarditis, pneumonia, *Sarcocystis* sp., schizont, wild turkey.

Clinical sarcocystosis has been reported once in chickens (Mutalib et al., 1995), a red lory (Page et al., 1989), a cockatiel (Jacobson et al., 1984), and other psittacine birds (Hillyer et al., 1991; Clubb and Frenkel, 1992) but is rarely observed in other avian species. Sarcocystosis has been reported in an eagle (Dubey et al., 1991b), a goshawk (Aguilar et al., 1991), and a wild turkey (Teglas et al., 1998). We are reporting another case of acute sarcocystosis in an eastern wild turkey (*Meleagris gallopavo silvestris*) and providing more details of the structure and identifying characteristics of the parasite.

An adult female Eastern wild turkey was found dead in a squatted position in a fire-break by foresters in Early County (Georgia, USA, 31°22'N; 84°56'W) on February 9, 1998. The bird was transported to the Southeastern Cooperative Wildlife Disease Study (Athens, Georgia, USA) where it was examined at necropsy 2 days later.

On gross examination, the bird weighed 3.4 kg with few subcutaneous or internal body fat reserves and moderate wasting of

pectoral muscles. Tissues were slightly dehydrated and pale, but the carcass was slightly autolyzed. A mild peritoneal effusion was noted, and the pericardial sac contained a moderate amount of serosanguinous fluid. A yellow flat 6 mm plaque was present on the right ventricular wall. The liver was pale, mottled, and had faint pinpoint to 1 mm dark foci across the capsular surface.

Specimens of heart, skeletal muscle, lung, liver, spleen, kidney, pancreas, gastrointestinal tract, cerebrum, and cerebellum were fixed in 10% buffered neutral formalin. Paraffin embedded sections were stained with hematoxylin and eosin (HE) and examined microscopically. Selected sections also were tested with anti-*Sarcocystis cruzi*, anti-*Toxoplasma gondii*, anti-*Neospora caninum*, anti-*Sarcocystis falcatula*, and anti-*Sarcocystis neurona* polyclonal rabbit antibodies (Dubey et al., 1991a, 1998; Hamir et al., 1993; Lindsay and Dubey, 1989). The peroxidase-antiperoxidase reaction was used to reduce nonspecific reactions associated with peroxidases in poultry tissues. Pieces of lung and heart were embedded in methacrylate, and 3 µm were stained with HE or periodic acid schiff (PAS) reaction. Formalin-fixed lung tissue also was processed for transmission electron microscopy as described previously (Dubey et al., 1995). A representative specimen of the parasite has been deposited at the U.S. National Parasite Collection (Beltsville, Maryland, USA; Accession number 89097).

Histologically, the right ventricle of the heart (including sections through the grossly visible pale focus) had multiple foci of myofiber degeneration with mild to

moderate interstitial edema and inflammation consisting predominantly of lymphocytes, plasma cells and macrophages. Protozoal schizonts were found in association with inflammatory foci. Widely scattered foci of myofiber necrosis, mononuclear inflammation, and clusters of protozoal zoites also were seen in the left ventricular wall. Similar multiple small foci of inflammation and necrosis containing protozoa were present in the lungs, liver, and spleen. Mild perivascular lymphocytic cuffing was noted in sections of cerebrum and cerebellum with mild vacuolar degeneration of white matter and rare gliosis, but no organisms could be identified on routine sections.

Protozoa were more commonly found in the heart and lungs than in other tissues. Organisms were not found in vascular endothelium. The host cell parasitized could not be determined with certainty but appeared to be a myocyte or macrophage. Only asexual stages were seen and consisted of immature and mature schizonts and individual merozoites (Fig. 1B–G). Schizonts divided by multiple nuclear division (Fig. 1D). A parasitophorous vacuole was not seen, except around individual merozoites (Fig. 1C). Schizonts were elongated in the heart and were seen following the long axis of the myofibers (Fig. 1D, E) whereas they were small in lungs. A residual body was seen occasionally in schizonts in lungs (Fig. 1G). Schizonts in heart were slender and up to 50 μm long (Fig. 1E). In regular HE stained sections, merozoites were difficult to identify. In plastic embedded sections stained with HE, merozoites were 3–4 μm long and up to 1 μm wide ($n = 10$). Individual merozoites contained a centrally-located nucleus. Schizonts and merozoites were negative with periodic acid Schiff reaction. In the lungs, organisms were located in alveolar septa, and some schizonts were present in alveoli (Fig. 1G). Schizonts and merozoites stained with anti-*S. cruzi* serum but not with anti-*S. neurona*, anti-*S. falcatula*, anti-*T. gondii*, and anti-*N. caninum* sera.

Ultrastructurally, the parasite was located freely in host cytoplasm and divided by endopolygony (Dubey et al., 1989). The nucleus became multilobed and merozoites budded from the surface (Fig. 2). Merozoites contained organelles found in coccidian merozoites except there were no rhoptries (Fig. 3).

In those *Sarcocystis* spp. in which the life cycle is known, the intermediate host, often a herbivore, becomes infected with *Sarcocystis* sp. by ingesting sporocysts from feces of the definitive host, which is usually a carnivore. Sporocysts release the sporozoites initiating an asexual cycle consisting of schizonts, which are usually found in vascular endothelium, and sarcocysts, which are found in muscle. It is the invasion of the endothelium by the schizonts that generally results in the pathogenic effects associated with sarcocystosis (Dubey et al., 1989).

The life cycle of *S. falcatula* is unusual in that the asexual life cycle occurs in birds and the sexual life cycle occurs in opossums (*Didelphis virginiana*) (Box et al., 1984). After ingestion by a susceptible bird, the schizonts of *S. falcatula* can persist up to 5 mo and can be highly pathogenic to some species of birds (Smith et al., 1987a, b, 1989). *Sarcocystis falcatula* has been shown to be infective to canaries, finches, budgerigars, and pigeons but not to gallinaceous birds (Box and Smith, 1982). Food contamination with *S. falcatula* sporocysts from opossum feces or from cockroaches that have ingested opossum feces is thought to be the source of the infection in several outbreaks in psittacine birds (Hillyer et al., 1991; Clubb and Frenkel, 1992).

Organisms in the present turkey from southwest Georgia were structurally similar to those found in the previously reported wild turkey from West Virginia (Teglas et al., 1998). As in that case, organisms were not found in endothelial cells, which contrasts reports of infections with *S. falcatula* in psittacine birds (Teglas et al., 1998). Organisms were found in

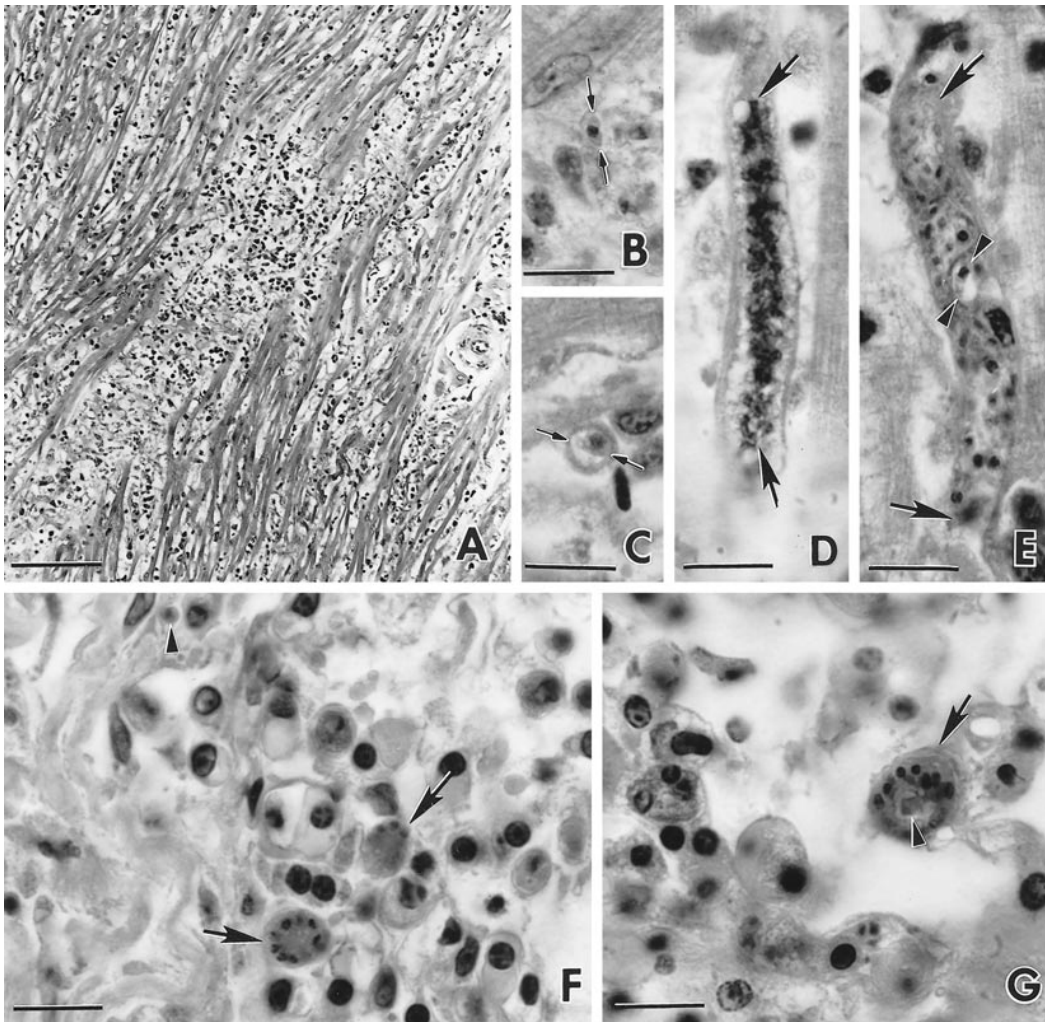


FIGURE 1. Lesions and *Sarcocystis* sp. in sections of heart (Fig. 1A–E) and lungs (Fig. 1F, G) of the wild turkey from Georgia, USA. Bar in A is 200 μ m, Bars in B to G = 10 μ m. H&E stain. A. Focus of necrosis and inflammation. Note degeneration of myofibers and inflammatory exudate. B. Zoite (double arrows) with central nucleus. C. Merozoite differentiating into uninucleate meront with centrally located nucleus. There appears to be a space around the zoite. D. Elongate schizont with multilobed nucleus (arrows). E. Mature elongated tortuous schizont with merozoites. One merozoite is cut longitudinally (arrowheads). F. Two multinucleated schizonts (arrows). G. Schizont (arrow) with a residual body (arrowhead).

neural tissues in the previous wild turkey. In the present case, inflammation was present in the brain. While no organisms could be found, infection of neural tissues may have been the cause of this inflammation.

The parasite in the present turkey was not *S. falcatula* because schizonts were not found in endothelial cells and because the organisms did not react to anti-*S. falcatula*

antibody. Ultrastructurally and antigenically, the parasite is a species of *Sarcocystis* but the species has yet to be identified. Whether wild or domestic turkeys are abnormal or normal hosts for this parasite remains to be determined.

This work was conducted through the sponsorship from the fish and wildlife agencies of Alabama, Arkansas, Florida, Georgia, Kentucky, Louisiana, Maryland,

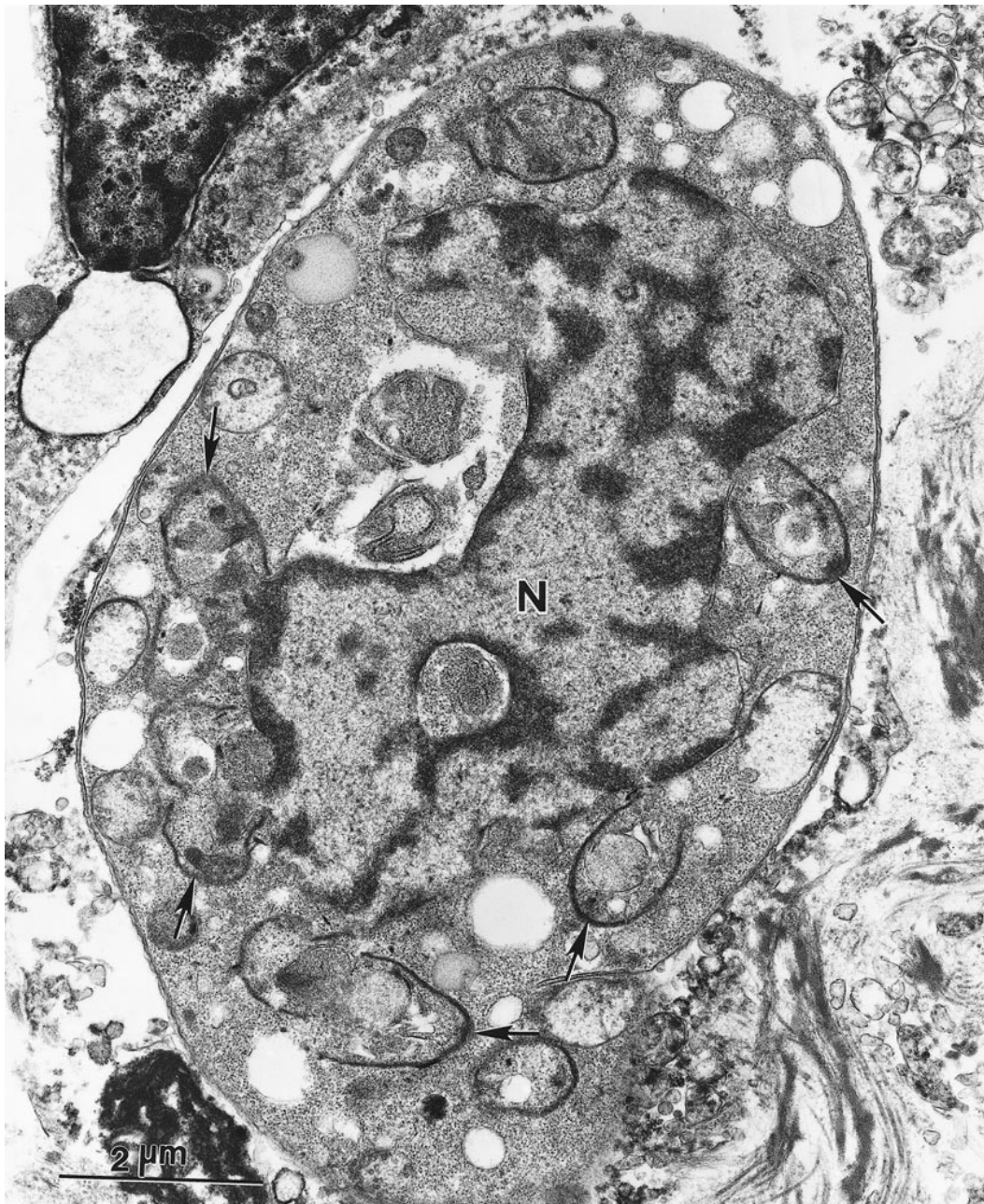

FIGURE 2. Transmission electron micrograph of an immature schizont of *Sarcocystis* sp. from a wild turkey with multilobed nucleus (N) and merozoite analagen (arrows).

Mississippi, Missouri, North Carolina, Puerto Rico, South Carolina, Tennessee, Virginia, and West Virginia. Funds were provided by the Federal Aid to Wildlife Restoration Act (50 Stat. 917) and through Grant Agreement 1445-GT09-96-0002,

U.S. Geological Survey (U.S. Department of the Interior, Washington, D.C., USA). Support was also received through Cooperative Agreement 98-9613-0032-CA with Veterinary Services (Animal and Plant Health Inspection Service, U.S. Depart-

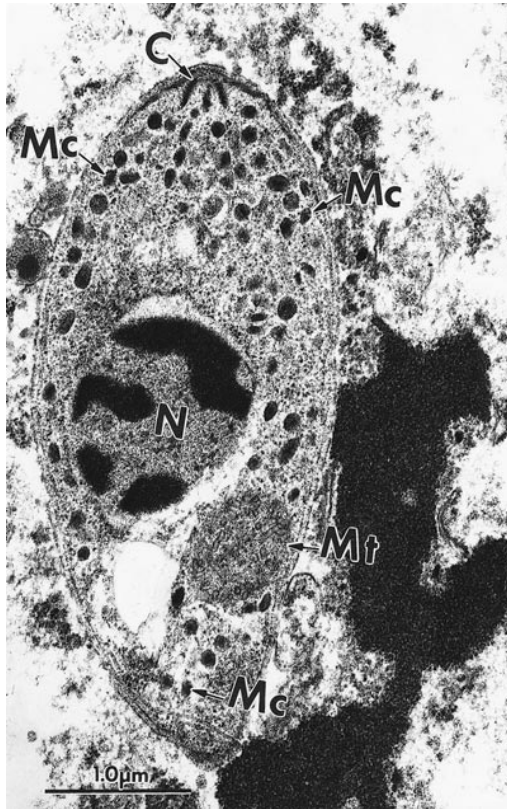


FIGURE 3. Transmission electron micrograph of a longitudinally cut merozoite of *Sarcocystis* sp. from a wild turkey with a conoid (C), nucleus (N), numerous micronemes (Mc) extending up to the non-conoidal end, a prominent mitochondrion (Mt), and an intact pellicle (arrows). Note the absence of rhoptries.

ment of Agriculture, Washington, D.C., USA).

LITERATURE CITED

- AGUILAR, R. F., D. P. SHAW, J. P. DUBEY, AND P. REDIG. 1991. *Sarcocystis*-associated encephalitis in an immature northern goshawk (*Accipiter gentilis atricapillus*). *Journal of Zoo and Wildlife Medicine* 22: 466–469.
- BOX, E. D., J. L. MEIER, AND J. H. SMITH. 1984. Description of *Sarcocystis falcatula* Stiles, 1893, a parasite of birds and opossums. *Journal of Protozoology* 31: 521–524.
- , AND J. H. SMITH. 1982. The intermediate host spectrum in a *Sarcocystis* species of birds. *The Journal of Parasitology* 68: 668–673.
- CLUBB, S. L., AND J. K. FRENKEL. 1992. *Sarcocystis falcatula* of opossums: Transmission by cockroaches with fatal pulmonary disease in psittacine birds. *The Journal of Parasitology* 78: 116–124.
- DUBEY, J. P., F. L. METZGER JR., A. L. HATTEL, D. S. LINDSAY, AND D. L. FRITZ. 1995. Canine cutaneous neosporosis: Clinical improvement with clindamycin. *Veterinary Dermatology* 6: 37–43.
- , C. A. SPEER, AND D. S. LINDSAY. 1998. Isolation of a third species of *Sarcocystis* in immunodeficient mice fed feces from opossums (*Didelphis virginiana*) and its differentiation from *Sarcocystis falcatula* and *Sarcocystis neurona*. *The Journal of Parasitology* 84: 1158–1164.
- , S. W. DAVIS, C. A. SPEER, D. D. BOWMAN, A. DE LAHUNTA, D. E. GRANSTROM, M. J. TOPPER, A. N. HAMIR, J. F. CUMMINGS, AND M. M. SUTER. 1991a. *Sarcocystis neurona* n. sp. (Protozoa: Apicomplexa), the etiologic agent of equine protozoal myeloencephalitis. *The Journal of Parasitology* 77: 212–218.
- , S. L. PORTER, A. L. HATTEL, D. C. KRADEL, M. J. TOPPER, AND L. JOHNSON. 1991b. Sarcocystosis-associated clinical encephalitis in a golden eagle (*Aquila chrysaetos*). *Journal of Zoo and Wildlife Medicine* 22: 233–236.
- , C. A. SPEER, AND R. FAYER. 1989. *Sarcocystosis of animals and man*. CRC Press, Boca Raton, Florida. 215 pp.
- HAMIR, A. N., G. MOSER, D. T. GALLIGAN, S. W. DAVIS, D. E. GRANSTROM, AND J. P. DUBEY. 1993. Immunohistochemical study to demonstrate *Sarcocystis neurona* in equine protozoal myeloencephalitis. *Journal of Veterinary Diagnostic Investigation* 5: 418–422.
- HILLYER, E. V., M. P. ANDERSON, E. C. GREINER, C. T. ATKINSON, AND J. K. FRENKEL. 1991. An outbreak of *Sarcocystis* in a collection of psittacines. *Journal of Zoo and Wildlife Medicine* 22: 434–445.
- JACOBSON, E. R., C. H. GARDINER, A. NICHOLSON, AND C. D. PAGE. 1984. *Sarcocystis* encephalitis in a cockatiel. *Journal of the American Veterinary Medical Association* 185: 904–906.
- LINDSAY, D. S., AND J. P. DUBEY. 1989. Immunohistochemical diagnosis of *Neospora caninum* in tissue sections. *American Journal of Veterinary Research* 50: 1981–1983.
- MUTALIB, A., R. KEIRS, W. MASLIN, M. TOPPER, AND J. P. DUBEY. 1995. *Sarcocystis*-associated encephalitis in chickens. *Avian Diseases* 39: 436–440.
- PAGE, C. D., R. E. SCHMIDT, G. B. HUBBARD, AND P. C. LANGLINAIS. 1989. *Sarcocystis* myocarditis in a red lory (*Eos bornea*). *Journal of Zoo and Wildlife Medicine* 20: 461–464.
- SMITH, J. H., J. L. MEIER, P. J. G. NEILL, AND E. D. BOX. 1987a. Pathogenesis of *Sarcocystis falcatula* in the budgerigar. I. Early pulmonary schizogony. *Laboratory Investigation* 56: 60–71.
- , ———, ———, AND ———. 1987b. Pathogenesis of *Sarcocystis falcatula* in the budgerigar. II. Pulmonary pathology. *Laboratory Investigation* 56: 72–84.

———, P. J. G. NEILL, AND E. D. BOX. 1989. Pathogenesis of *Sarcocystis falcatula* in the budgerigar. III. Pathologic and quantitative parasitologic analysis of extrapulmonary disease. *The Journal of Parasitology* 75: 270–287.

TEGLAS, M. B., S. E. LITTLE, K. S. LATIMER, AND J.

P. DUBEY. 1998. *Sarcocystis*-associated encephalitis and myocarditis in a wild turkey (*Meleagris gallopavo*). *The Journal of Parasitology* 84: 661–663.

Received for publication 20 September 1999.