

Giardiasis in a White Stork in The Netherlands

F. F. J. Franssen,^{1,4} J. Hooimeijer,² B. Blankenstein,³ and D. J. Houwers^{3,1} Department of Parasitology and Tropical Veterinary Medicine, Institute of Infectious Diseases and Immunology, Utrecht University, Utrecht, The Netherlands; ² Clinic for Birds, Meppel, The Netherlands; ³ Veterinary Microbiological Diagnostic Center, Institute of Infectious Diseases and Immunology, Utrecht University, Utrecht, The Netherlands; ⁴ Corresponding author (e-mail: f.franssen@vet.uu.nl).

ABSTRACT: *Giardia* sp. was found in the white stork (*Ciconia ciconia*) in The Netherlands for the first time. The *Giardia* sp. trophozoites that were found in the feces of a 6-wk-old white stork, were examined by light microscopy. The parasites closely resembled *Giardia ardeae* that had been isolated by others from several species of wading birds belonging to the order Ciconiiformes, sharing a deeply notched adhesive disk, a single caudal flagellum, and a single round median body. Serologically, the parasites did not react with anti-*Giardia intestinalis* monoclonal antibodies. Although no signs of intestinal disease were observed in the stork chick, the presence of parasites in all stages of development and the huge number of parasites show that the stork chick was experiencing an active infection with *G. ardeae* type parasites.

Key words: Case report, *Ciconia ciconia*, *Giardia ardeae*, morphology, serology, white stork.

Species of the genus *Giardia* affect numerous hosts, ranging from mammals to amphibians and birds. Traditionally, species have been named on the basis of their morphology and their assumed host specificity. Although the taxonomy of *Giardia* spp. remains unclear, four morphologically and biologically distinguishable groups have been described. These groups include *G. intestinalis* (syn. *G. duodenalis*, *G. lamblia*) of humans and other mammals, *G. muris* of rodents, *G. agilis* of amphibians and *G. ardeae* of several wading birds, belonging to the order of Ciconiiformes (Lymbery and Tibayrenc, 1994; Kulda and Nohýnková, 1995). Members of these four groups can be distinguished morphologically by the shape, position and number of the median bodies, the morphology of the adhesive disk and the number of caudal flagella. *G. psittaci*, a species that causes clinical problems in parakeets, is placed within the *G. intestinalis* group by some authors on morphological

grounds (Kulda and Nohýnková, 1995), but distinguished as a separate group by others, on the basis of its inability to infect mammals in experimental studies (Lymbery and Tibayrenc, 1994). The classification of *Giardia* spp. found in birds of the orders Charadriiformes, Passeriformes, and Piciformes remains unclear.

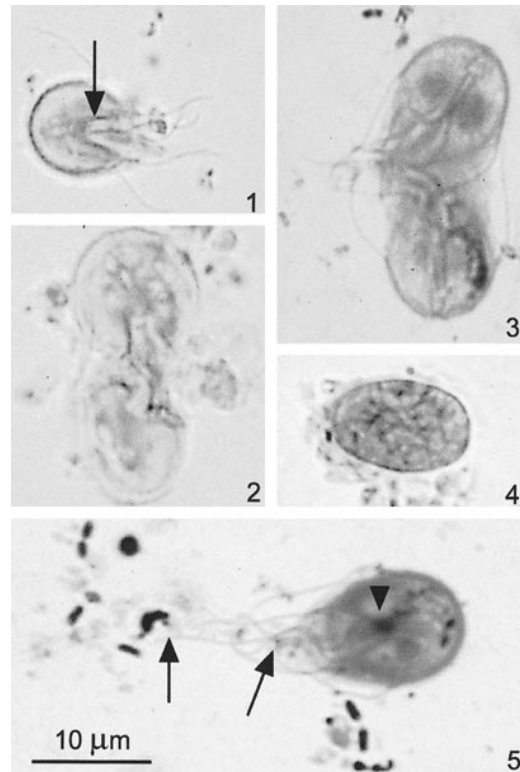
Nöller (1920) described a *Giardia* sp. possessing a single caudal flagellum, which was found in a gray heron (*Ardea cinerea*) and was named *G. ardea* (Kulda and Nohýnková, 1995). More recently, *G. ardeae* was isolated from the great blue heron (*A. herodias*) and characterized genetically (Erlandsen et al., 1990). Phenotypically identical *Giardia* spp. were observed in the green heron (*Butorides virescens*), the purple heron (*A. pupurea*), the cocoi heron (*A. cocoi*) and in several species of egrets (Erlandsen et al., 1990; Kulda and Nohýnková, 1995). An Australian *Giardia* sp. isolate from the straw-necked ibis (*Threskiornis spinicollis*) resembled *G. ardeae* morphologically (Forshaw et al., 1992), but differed genetically, possibly representing a distinct strain of the species *G. ardeae* (McRoberts et al., 1996). This is the first report of a *Giardia* sp. in a white stork (*Ciconia ciconia*).

An emaciated 6-wk-old white stork chick (*C. ciconia*) from a wild colony near the city of Meppel (The Netherlands; 53°20'N, 6°10'E), was presented to the Clinic for Birds (Meppel, The Netherlands) with an open bone fracture. A routine fecal sample was taken and microscopically examined for parasitic protozoa. The sample was sent for confirmation to the Veterinary Microbiological Diagnostic Center (Utrecht, The Netherlands), where it was examined microscopically in wet lu-

gol stained films and methanol fixed/Giemsa stained preparations. In addition, the fecal sample was tested in the ProSpecT Giardia Microplate Assay (Alexon-Trend, Ramsey, Minnesota, USA) following the manufacturer's instructions. This assay is an enzyme immunoassay based on the detection of a 65 kDa glycoprotein (GSA 65) by use of monoclonal antibodies specific for *G. intestinalis*. Since the stork chick was euthanized, directly after taking the fecal sample, no attempt could be made to culture the parasites. No signs of intestinal disease were observed in the stork chick.

Microscopically, the fecal sample was found to contain large numbers of *Giardia* sp. trophozoites, 12–14 μm long and 8–9 μm wide. The morphology of the parasites closely resembled that of *G. ardeae*, with a pyriform body and the posterior edge of the dorsal adhesive disk being deeply notched (Fig. 1). The single, round median body was positioned below the two teardrop shaped to oval-round nuclei on the caudal axonemes (Fig. 5). Some parasites possessed club shaped median bodies positioned longitudinally between the axonemes (not shown). The parasites possessed one single caudal flagellum, as observed in Giemsa-stained smears by light microscopy (Fig. 5). The *Giardia* sp. in the white stork fecal sample were found in all stages of development, including dividing parasites, which were seen in Lugol's iodine direct smears (Fig. 2) and in Giemsa stained smears (Fig. 3), and cysts (Fig. 4).

Although *Giardia* sp. trophozoites and cysts were found in large numbers microscopically, the fecal sample of the white stork chick did not give a positive result in the ProSpecT Giardia Microplate Assay, which is sensitive and specific for *G. intestinalis* (Zimmerman and Needham, 1993; Garcia and Shimizu, 1997). This assay utilizes monoclonal antibodies against a 65 kDa *Giardia* Specific Antigen glycoprotein (GSA 65), which is produced by the proliferating *G. intestinalis* trophozoites in the hosts intestinal tract and is present in both trophozoites and cysts in the



FIGURES 1–5. *Giardia* sp. from the white stork chick in direct smears with Lugol's iodine (Fig. 1, 2 and 4) and in methanol fixed and Giemsa stained smears (Fig. 3 and 5). The *Giardia* sp. trophozoites possessed a deeply notched posterior edge of the dorsal adhesive disk (Fig. 1, arrow), two oval-round to teardrop shaped nuclei (Fig. 3 and 5), a single median body positioned on the caudal axonemes (Fig. 5, arrowhead). A single caudal flagellum is visible (Fig. 5, arrow left), where the other caudal flagellum appears rudimentary (Fig. 5, arrow right). Parasites were seen in late stage of cell division in direct smears with Lugol's iodine (Fig. 2) and in Giemsa stained smears, showing differentiated daughter cells (Fig. 3). Also, *Giardia* sp. cysts were present (Fig. 4).

stool of giardiasis patients (Rosoff and Stibbs, 1986). Experimental efforts to infect mammalian hosts with *G. ardeae*, or to infect avian hosts with *G. intestinalis* were unsuccessful (Erlandsen, 1994). *Giardia* sp. cysts, which are shed in surface waters by the white stork, are therefore unlikely to represent a threat to humans.

This is the first report of *Giardia* spp. in the white stork (*C. ciconia*). Previous

papers report *G. ardeae* in herons, egrets, and ibis. The white stork chick that was presented to the veterinary practice, was raised in a nest some 100 m away from a gray heron breeding colony. Gray herons were observed to scavenge the nests of white stork for remains of prey, which presents a possible route of cross infection between the two bird species. Morphologically, the *Giardia* sp. found in the white stork, closely resembled *G. ardeae* observed in herons. The apparently single caudal flagellum, the deeply notched adhesive disk, the shape and position of the median body, and the nuclei were in accordance with those reported for *G. ardeae* of gray heron and great blue heron (Georgi et al., 1986; Erlandsen et al., 1990; Forshaw et al., 1992). The morphological characteristics of the trophozoites found in our white stork chick support the classification of these parasites within the *G. ardeae* group. Although no signs of intestinal disease were observed, the presence of parasites in all stages of development and the huge number of parasites show that the stork chick was experiencing an active infection with *G. ardeae* type parasites.

The authors thank M. Koene for technical assistance and A. W. C. A. Cornelissen for critically reading the manuscript.

LITERATURE CITED

- ERLANDSEN, S. L., W. J. BEMRICK, C. L. WELLS, D. E. FEELY, L. KNUDSON, S. R. CAMPBELL, H. VAN KEULEN, AND E. L. JARROLL. 1990. Axenic culture and characterization of *Giardia ardeae* from the great blue heron (*Ardea herodias*). *The Journal of Parasitology* 76: 717–724.
- . 1994. Biotic transmission—Is giardiasis a zoonosis? In *Giardia: From molecules to disease*, R. C. A. Thompson, J. A. Reynoldson and A. J. Lymbery (eds.). CAB International, Wallingford, U.K., pp. 83–97.
- FORSHAW, D., D. G. PALMER, S. A. HALSE, R. M. HOPKINS, AND R. C. A. THOMPSON. 1992. *Giardia* in straw-necked ibis (*Threskiornis spinicollis*) in Western Australia. *The Veterinary Record* 131: 267–268.
- GARCIA, L., AND R. Y. SHIMIZU. 1997. Evaluation of nine immunoassay kits (enzyme immunoassay and direct fluorescence) for detection of *Giardia lamblia* and *Cryptosporidium parvum* in human fecal specimens. *The Journal of Clinical Microbiology* 35: 1526–1529.
- GEORGI, M. E., M. S. CARLISLE, AND L. E. SMILEY. 1986. Giardiasis in a great blue heron (*Ardea herodias*) in New York state: Another potential source of waterborne giardiasis. *The American Journal of Epidemiology* 123: 916–917.
- KULDA, J., AND E. NOHÝNKOVÁ. 1995. *Giardia* in humans and animals. In *Parasitic protozoa*, Vol. 10, J. P. Kreier (ed.). Academic Press, San Diego, California, pp. 225–422.
- LYMBERY, A. J., AND M. TIBAYRENC. 1994. Population genetics and systematics: How many species of *Giardia* are there? In *Giardia: From molecules to disease*, R. C. A. Thompson, J. A. Reynoldson and A. J. Lymbery (eds.). CAB International, Wallingford, U.K., pp. 71–79.
- MCRROBERTS, K. M., B. P. MELONI, U. M. MORGAN, R. MARANO, N. BINZ, S. L. ERLANDSEN, S. A. HALSE, AND R. C. A. THOMPSON. 1996. Morphological and molecular characterization of *Giardia* isolated from the straw-necked ibis (*Threskiornis spinicollis*) in western Australia. *The Journal of Parasitology* 82: 711–718.
- NÖLLER, W. 1920. Kleine Beobachtungen an parasitischen Protozoen. *Archiv für Protistenkunde* 41: 169–189.
- ROSOFF, J. D., AND H. H. STIBBS. 1986. Isolation and identification of a *Giardia lamblia*-specific stool antigen (GSA 65) useful in coprodiagnosis of giardiasis. *The Journal of Clinical Microbiology* 23: 905–910.
- ZIMMERMAN, S. K., AND C. A. NEEDHAM. 1995. Comparison of conventional stool concentration and preserved-smear methods with Merifluor *Cryptosporidium/Giardia* Direct Immunofluorescence Assay for detection of *Giardia lamblia*. *The Journal of Clinical Microbiology* 33: 1942–1943.

Received for publication 5 November 1999.