

RETROSPECTIVE STUDY OF PROLIFERATIVE PAPILLARY VULVITIS IN FLORIDA PANTHERS

Authors: Rotstein, David S., Taylor, Sharon K., Birkenhauer, Adam,
Roelke-Parker, Melody, and Homer, Bruce L.

Source: Journal of Wildlife Diseases, 38(1) : 115-123

Published By: Wildlife Disease Association

URL: <https://doi.org/10.7589/0090-3558-38.1.115>

The BioOne Digital Library (<https://bioone.org/>) provides worldwide distribution for more than 580 journals and eBooks from BioOne's community of over 150 nonprofit societies, research institutions, and university presses in the biological, ecological, and environmental sciences. The BioOne Digital Library encompasses the flagship aggregation BioOne Complete (<https://bioone.org/subscribe>), the BioOne Complete Archive (<https://bioone.org/archive>), and the BioOne eBooks program offerings ESA eBook Collection (<https://bioone.org/esa-ebooks>) and CSIRO Publishing BioSelect Collection (<https://bioone.org/csiro-ebooks>).

Your use of this PDF, the BioOne Digital Library, and all posted and associated content indicates your acceptance of BioOne's Terms of Use, available at www.bioone.org/terms-of-use.

Usage of BioOne Digital Library content is strictly limited to personal, educational, and non-commercial use. Commercial inquiries or rights and permissions requests should be directed to the individual publisher as copyright holder.

BioOne is an innovative nonprofit that sees sustainable scholarly publishing as an inherently collaborative enterprise connecting authors, nonprofit publishers, academic institutions, research libraries, and research funders in the common goal of maximizing access to critical research.

RETROSPECTIVE STUDY OF PROLIFERATIVE PAPILLARY VULVITIS IN FLORIDA PANTHERS

David S. Rotstein,¹ Sharon K. Taylor,^{2,3} Adam Birkenhauer,⁴ Melody Roelke-Parker,⁵ and Bruce L. Homer^{6,7}

¹ Department of Physiology, College of Veterinary Medicine, University of Florida, P.O. Box, 110144, Gainesville, Florida, 32611 USA

² Florida Fish and Wildlife Conservation Commission, 4005 South Main Street, Gainesville, Florida 32601, USA

³ Present address: Environmental Protection Agency, Research Triangle Park, North Carolina 27711, USA

⁴ College of Veterinary Medicine, North Carolina State University, Raleigh, North Carolina 27606, USA

⁵ National Cancer Institute, Laboratory of Genomic Diversity, Box B, Frederick, Maryland 21702, USA

⁶ Department of Pathobiology, College of Veterinary Medicine, University of Florida, P.O. Box, 110880, Gainesville, Florida 32611, USA

⁷ Corresponding author (e-mail: homerb@mail.vetmed.ufl.edu)

ABSTRACT: Proliferative, papillary vulvitis was identified in 16 of 34 (47%) free-ranging and captive female Florida panthers (*Puma concolor coryi*) monitored over a period from 1983–98. Gross lesions were characterized by extensive papilliferous proliferation in the mucosa of the vestibulum vaginae. Within lesions, the mean length and width of vestibular papillae were 1.07 ± 0.39 mm (CV = 36%) and 0.55 ± 0.11 mm (CV = 20%) respectively. Histologically, three to 12 layers of non-cornified stratified squamous epithelium with various degrees of basal cell spongiosis and rete ridge formation covered fibrous papillae. Mixed leukocytic mucosal inflammation also was observed. Infectious organisms were not observed, and immunohistochemical testing for the presence of papillomavirus antigens in specimens from seven panthers was negative. Lesions in nearly all of the panthers were first observed during a six-year period (1986–92), with one each in 1983, 1996 and 1998. There were no significant differences between the number of females having litters, the number of litters between age-matched and interval-matched females, and the interval between litters among lesion positive and lesion negative females over the 15 yr period. The severity of lesions did not appear to differ between parous and nulliparous free-ranging lesion-positive females. The cause of proliferative vulvitis remains unknown. However, the lesion did not appear to have a significant effect on reproduction.

Key words: Florida panther, cougar, *Puma concolor coryi*, proliferative vulvitis, vestibulum vaginae, pathology, reproduction.

INTRODUCTION

Lesions, characterized by extensive papilliferous proliferation and epithelial hyperplasia of vestibular mucosa, have been identified in Florida panthers (*Puma concolor coryi*) since 1983 (Roelke and Glass, 1992; Homer et al., 1995). Variability in lesion size and degree of involvement of the vestibulum vaginae were observed in panthers in the field and at the time of necropsy. Panthers examined sequentially did not have evidence of lesion regression. Although the etiology of the condition is unknown, underlying infectious diseases, environmental irritants, or hormonal changes (hyperestrogenism) may be possible causes.

Infectious agents that have been associated with inflammatory disease of the vulva and vagina in cats include *Escherich-*

ia coli, *Staphylococcus* spp., *Streptococcus* spp., and *Mycoplasma* spp. (Barsanti, 1998; Greene, 1998). Certain viral agents, such as feline herpesvirus-1 (Gaskell and Dawson, 1998) can induce cutaneous ulcerative or hyperplastic lesions in cats, but the affected site is usually not the vulva and vagina. Productive papillomavirus infections have been recognized in several taxa of felids including Florida panthers (*Puma concolor coryi*), Asian lions (*Panthera leo*), snow leopards (*Panthera uncia*), bobcats (*Lynx rufus*), clouded leopards (*Neofelis nebulosa*), and domestic cats (*Felis domesticus*) (Sundberg et al., 2000), and have been associated with glossal, oral mucosal, and cutaneous epithelial hyperplastic lesions. Foci of degenerating cells within the upper stratum spinosum and granulosum, cytoplasmic inclusion bodies,

and a round centrally or eccentrically placed nucleus (koilocytes) were consistent findings in the papillomavirus-induced lesions (Sundberg et al., 2000).

It is not known if the vestibular lesions in panthers have impeded coitus due to pain or other factors, or have otherwise prevented fertilization. Since successful reproduction and kitten survival are essential for a highly endangered species like the Florida panther, it is important to determine if the presence of vestibular lesions affect reproductive success. The objectives of this retrospective study were to evaluate the gross and microscopic changes associated with the proliferative vestibular lesions in Florida panthers, determine potential effects upon reproductive success, and determine if papillomavirus infection was associated with the lesions.

MATERIALS AND METHODS

Biopsy samples of lesions in the vestibulum vaginae were collected from 12 of 13 free-ranging and 3 captive Florida panthers from peninsular south Florida (south of 27°00'N, USA) over a 15 yr period (1983–98) during routine field capture for the purpose of physical examination and sample procurement. The stage of the reproductive cycle at the time of biopsy collection was not determined. Most panthers were evaluated three or more times during this time period. Single biopsy samples were obtained from five panthers, two sequential samples were obtained from six panthers and three sequential samples were obtained from one panther. Thirty four adult female panthers, ranging from 1 to 13 yr, were examined during this time period. The capture event involved treeing panthers by a houndsman (Maehr et al, 1990), and a 3 cc intramuscular dart with a 1.5 × 20 mm uncollared needle was delivered via a CO₂ powered rifle (Telinject®, Saugus, California, USA). Several combinations of anesthetic drugs were used for anesthesia including ketamine hydrochloride (Ketaset®, Fort Dodge Laboratories, Inc., Fort Dodge, Iowa, USA), xylazine hydrochloride (Rompun®, Mobay Corporation Animal Health Division, Shawnee, Kansas, USA), and tiletamine hydrochloride/zolazepam hydrochloride (Telazol®, Fort Dodge Laboratories, Inc). Animals were given complete physical examinations, weighed, vaccinated against feline viral rhinotracheitis, calicivirus, panleukopenia (Fel-O-Vax PCT®, Fort

Dodge Laboratory, Fort Dodge, Iowa, USA), rabies (Imrab 3®, Rhone Merieux, Athens, Georgia, USA), and dewormed with ivermectin (Ivomec®, Merck and Company, Rahway, New Jersey, USA) and praziquantel (Droncit®, Bayer Corporation, Shawnee Mission, Kansas, USA).

Vestibular biopsies were performed as follows. Aseptic preparation of the vestibulum vaginae was performed and then an 4 × 2 × 1 mm punch biopsy sample including the mucosa and propria-submucosa was obtained using alligator biopsy forceps or with surgical scissors. Specimens were fixed in neutral buffered 10% formalin solution for histologic examination. Nine panthers with lesions received a complete necropsy examination (eight at College of Veterinary Medicine, University of Florida, Gainesville, Florida, USA; one at College of Medicine, University of Miami, Miami, Florida, USA). One 3-yr-old uncollared Florida panther without a vestibular lesion was euthanized after being struck by a vehicle. The reproductive status was unknown. A section of normal appearing vestibulum vaginae was prepared for histologic examination.

For morphometric analysis, five randomly chosen formalin-fixed samples of vestibulum vaginae (numbers 14, 21, 22, 38, 205) were analyzed using the Kontron IBAS image processing system, version 2.0 (Kontron IBAS-AT®, Kontron Elektronik GmbH, Munich, Germany). A millimeter scale was created at a focal distance of 65 cm. The length and width of the mucosal papilli from each specimen were measured three times each and the average length and width was calculated for each sample. The mean, standard deviation, and coefficient of variation were determined for the morphometric analysis using Graph Pad InStat (Graph Pad InStat, Incorporated, San Diego, California, USA). Fixed tissues were processed and embedded routinely in paraffin, sectioned at 5 to 6 µm and stained with hematoxylin and eosin (H&E). Sections were then examined by light microscopy. Special stains, such as Brown and Brenn for bacteria and GMS for fungi, were utilized as needed (Arrington, 1994). Specimens were evaluated for the degree of epithelial hyperplasia by counting the number of epithelial layers, and for the presence of degenerate epithelial changes and degree and type of inflammation. Paraffin-embedded sections of vestibulum vaginae from seven panthers with lesions were evaluated for papillomavirus group-specific antigens by an immunohistochemical protocol (Haines and Chelack, 1991), using a standard avidin-biotin complex kit (Vectastain Elite kit; Vector Laboratories, Inc., Burlingame, California, USA). A rabbit polyclonal antibody (Catalog #B580, DAKO corp., Car-

penteria, California, USA) that cross-reacts with mammalian and avian papillomavirus group specific antigens (Sundberg et al., 2000) was used. The positive control was a cutaneous papilloma from a horse. Controls for cytokeratin were also used to ensure immunoreactivity of the samples.

Representative vestibular lesions from two panthers (numbers 18 and 205) were examined electron microscopically for evidence of microorganisms. Formalin-fixed samples of vestibulum vaginae were sliced into 1 mm cubes, post-fixed in 2% osmium tetroxide, dehydrated through graded alcohols, and embedded in Spurr's Epon (1:1) resin (Bozzola and Russell, 1992). Ultrathin sections were stained with uranyl acetate and Reynold's lead citrate, and examined on a Hitachi H-7000 transmission electron microscope (Hitachi Instruments, Danbury, Connecticut).

A period prevalence was determined from the examination of medical records of 34 female panthers and a frequency histogram was generated to determine if there was a time trend in lesion observation. Several comparisons were done between lesion positive and lesion negative females to assess reproductive success. This included determining if there were differences in the total number of litters among free ranging lesion positive females ($n = 13$) and lesion negative females ($n = 18$). Three lesion positive females removed from the wild population for a captive breeding study were excluded from this analysis because the study was suspended, and no breeding took place. Numbers of litters in lesion positive and lesion negative panthers were compared by computation of a chi-square using Graph Pad InStat (Graph Pad Software, San Diego, California). Secondly, an age-matched and interval-matched comparison of lesion positive ($n = 6$) and lesion negative females ($n = 6$) was done to determine if there were differences in the number of litters per panther. A Wilcoxon signed rank test was used for this comparison. Finally, a Kaplan-Meier curve was generated for the comparison of the median interlitter interval between age-matched lesion positive and lesion negative females. The purpose of this analysis was to determine if lesion positive females had an increased duration between litters and, thus, conception. The Kaplan-Meier analysis allows for censoring of panthers that entered the study at various times and that did not have litters by the study cut-off. The number of progeny produced was not compared due to inaccuracies associated with the inability to account for losses of kittens prior to locating and visiting the den site. SAS program (SAS Institute, Incorporated, Cary, North Carolina,

USA) was used for statistical analyses of numbers of litters and interlitter interval in age-matched panthers. Lesions in free-ranging parous ($n = 6$) and nulliparous ($n = 3$) females were compared to determine if certain histologic differences in the vulvar lesions were present more often in nulliparous females than parous females, using a Fisher's exact test from the Graph Pad InStat. Comparisons were made according to the number of panthers exhibiting specific types of lesions, rather than a grading system for each type of lesion.

RESULTS

Some panthers died during the study period and others were recruited into the study after 1983. Sixty-nine percent (11/16) of the lesion positive panthers did not have vestibular lesions when first examined and developed lesions over the course of the study. Lesions were not noted to regress in panthers over the course of the study. Grossly, the lesions in all affected Florida panthers were characterized as extensive areas of mucosal papilliferous proliferation overlying longitudinal folds in the dorsal to dorsolateral wall, or circumferentially, in the vestibulum vaginae (Fig. 1, 2). Morphometric analysis revealed a mean (\pm SD) papillary length and width of 1.07 ± 0.39 mm (CV = 36%) and 0.55 ± 0.11 mm (CV = 20%) respectively, with a range of 0.49–1.97 mm and 0.41–0.75 mm respectively.

Histologic changes in the vestibular lesions occurred in various combinations (Table 1). Variably wide fibrous papillae were covered by three to 12 layers of variously hypertrophied noncornified stratified squamous epithelium (Figs. 3, 4, 5). Strata granulosum and corneum were not observed in any of the specimens. There was occasional superficial dissociation of keratinocytes and perinuclear cytoplasmic vacuolation with exfoliation of superficial epithelium (Fig. 4). Various degrees of mucosal epithelial neutrophil and/or lymphocyte infiltration were present in lesions of most animals. Basal spongiosis was observed in vestibular lesions of 10 panthers (Fig. 4). Rete ridge formation was usually mild, with the longest rete ridges in lesions

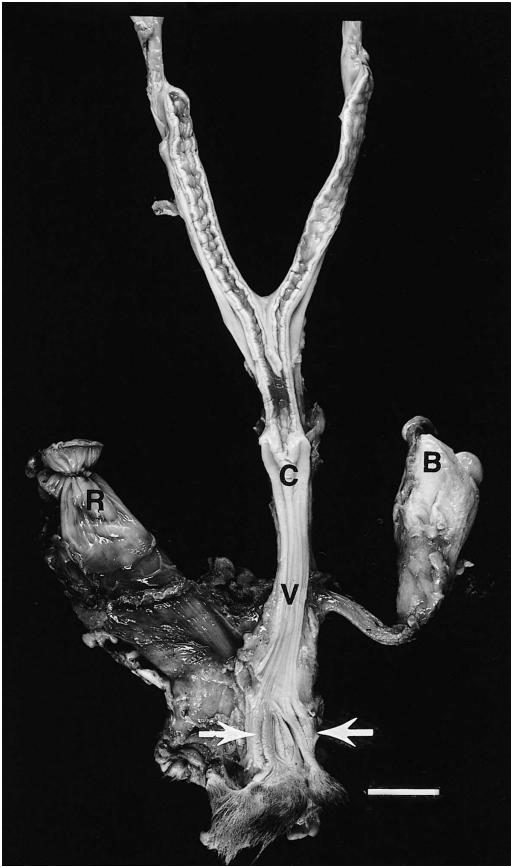

FIGURE 1. Reproductive tract of a 2-yr-old nulliparous Florida panther (#205) showing vestibulum vaginae (arrows) that has a raised roughened mucosa. The cervix (C); urinary bladder (B); rectum (R) and vagina (V) are designated. Bar = 4 cm.

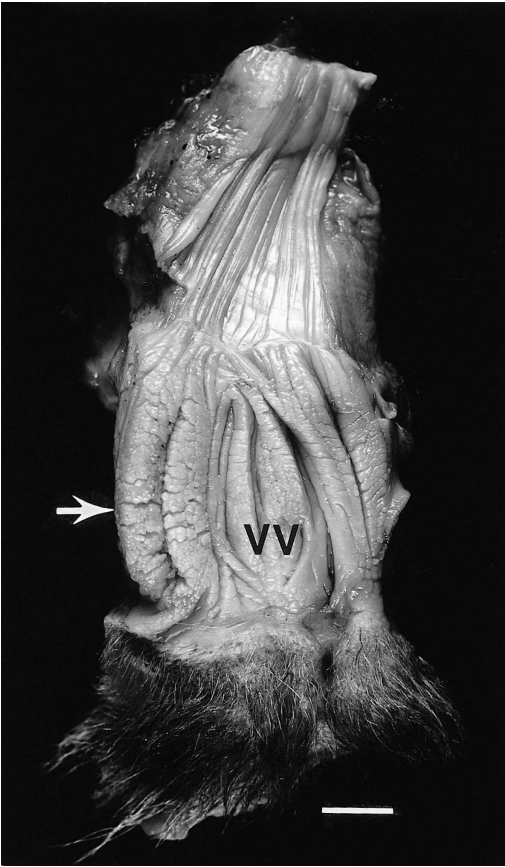


FIGURE 2. Reproductive tract of same panther in Fig. 1 showing the thickened longitudinal folds in the vestibulum vaginae (VV) that have a cobblestone to papillary dull mucosal surface. Bar = 1 cm.

with the fewest epithelial layers (Fig. 5). Frequent scattered, perivascular infiltrates of lymphocytes, plasma cells, and neutrophils were present in the superficial stroma. Leukocytes sometimes formed lichenoid infiltrates or infiltrated the walls of blood vessels. Edema of the superficial propria-submucosa, with greater than expected numbers of fibroblasts with plump, ovoid nuclei was observed in eight panthers. A normal appearing vaginal sample from a necropsied 3-yr-old Florida panther was three to four cell layers wide, with uniformly small epithelial cells, and did not have any evidence of inflammation (Fig. 6). Bacteria, fungi, protozoa, and viral inclusions were not detected in any of the

samples. Immunohistochemical testing of lesions for papillomavirus group specific antigens was negative.

Electron microscopic examination did not reveal microorganisms. In affected tissues, hyperplastic epithelial layers were infiltrated multifocally by neutrophils (Fig. 7). Some neutrophils and dissociated epithelial cells had pyknotic nuclei. The width of intercellular spaces increased toward the basal layers. Stromal fibroblasts with long cytoplasmic processes, abundant rough endoplasmic reticulum, and plasmalemmal vesicles (caveolae) were surrounded by normal appearing collagen fibrils.

Of the nine necropsied panthers, one

TABLE 1. Comparison of histologic features of proliferative vestibular lesions in Florida panthers (*Puma concolor coryi*) between free-ranging parous (*n* = 6) and free ranging (*n* = 3) and captive (*n* = 3) nulliparous females. Numbers in parentheses correspond to the number of free-ranging nulliparous females that have the observed histologic changes.

Lesion	Free-ranging parous	Captive and free-ranging nulliparous
Florida panther identification number	9, 11, 14, 19, 31, 32	18 ^a , 21, 22 ^a , 38 ^a , 204, 205
Mean age at biopsy (yr)	7.25	4.5
Average number of layers of epithelium	\bar{x} = 6	\bar{x} = 7
Superficial dissociation of keratinocytes and perinuclear cytoplasmic vacuolation	3 ^b	2 (1)
Epithelial neutrophilic infiltrates	3	5 (2)
Epithelial lymphocytic infiltrates	2	1 (0)
Basal spongiosis	5	5 (3)
Elongated rete ridges	4	2 (0)
Lichenoid infiltrates	4	2 (1)
Edema in propria-submucosa	4	4 (1)
Superficial stromal leukocytic infiltrates	6	5 (2)
Perivascular leukocytic infiltrates	6	5 (3)

^a Free-ranging nulliparous females.
^b Indicates number of biopsy specimens from this group that exhibited this change.

panther (#205) died following surgery to repair an atrial septal defect, and one panther (#19) died as the result of an aortic aneurysm. The remaining panthers died as the result of vehicular trauma or intraspecific aggression. Additional reproductive tract abnormalities and evidence of systemic disease were not observed.

The period prevalence was 47% (16/34) with lesions observed in 2- to 11-yr-old panthers over the course of the study. The lesion negative population ranged from 1 to 13 yr. The average age of panthers when lesions were first observed was $\bar{x} \pm \text{SD} =$

6 ± 2.7 yr. Nearly all of the vestibular lesions (*n* = 13) were initially observed in panthers between 1986–1992 (Fig. 8), with one each observed in 1983, 1996, and 1998. The percent of free ranging lesion positive and negative females that had litters was 54% (7/13) and 61% (11/18), respectively. Significant differences were not observed for the number of litters and the interval between litters. The median interval between litters was approximately 2 yr

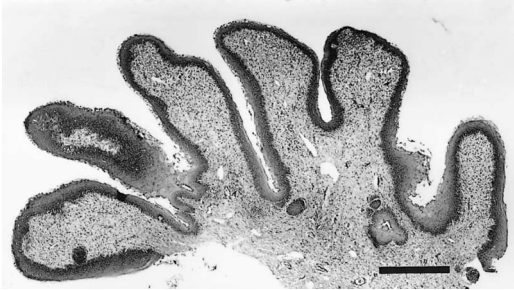

FIGURE 3. Section obtained from the vestibulum vaginae of Florida panther #205 at necropsy (see Fig. 1). Mucosa is composed of moderately broad papillae that are supported by fibrous stroma. H&E. Bar = 400 μm .

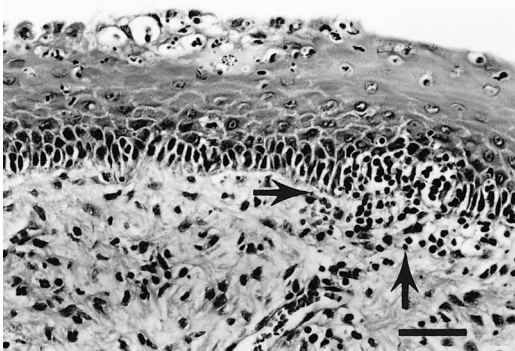


FIGURE 4. Higher magnification of Figure 3 illustrates superficial keratinocyte dissociation and vacuolation, basal spongiosis, focal lichenoid leukocytic infiltration (arrows), mild edema in the superficial propria-submucosa, and several fibroblasts with plump ovoid nuclei. H&E. Bar = 40 μm .

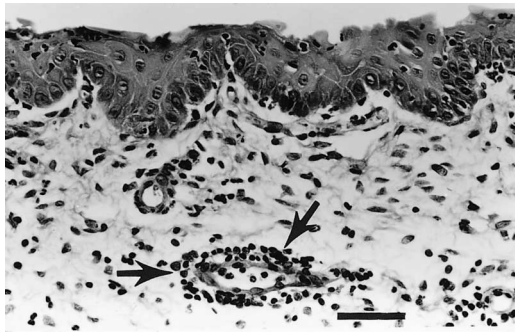


FIGURE 5. Vestibulum vaginae from a 3-yr-old multiparous Florida panther (#32). There are shallow rete ridges, stromal edema, superficial mixed leukocytic infiltrates, and perivascular leukocytic infiltration (arrows). H&E. Bar = 43 μ m.

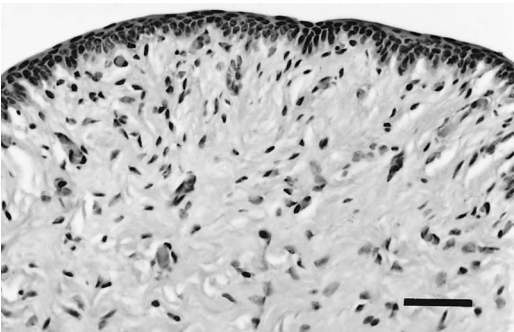


FIGURE 6. Normal appearing vestibulum vaginae from an uncollared 3-yr-old Florida panther. The mucosa is three to four cell layers wide and there is no evidence of hyperplasia or inflammation. H&E. Bar = 45 μ m.

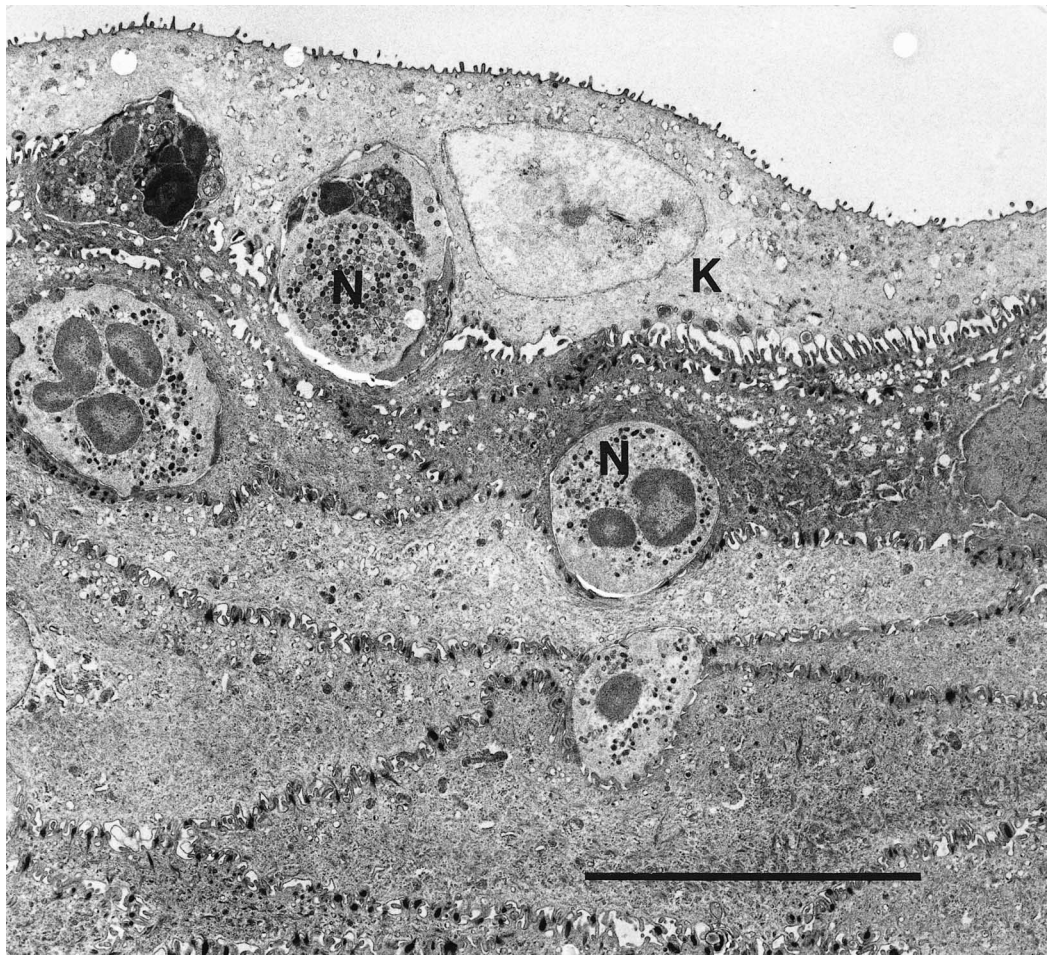

FIGURE 7. Transmission electron photomicrograph of vestibulum vaginae of Florida panther #205. Epithelial mucosa contains several neutrophils (N). No microorganisms are evident. A keratinocyte is designated (K). Bar = 10 μ m.

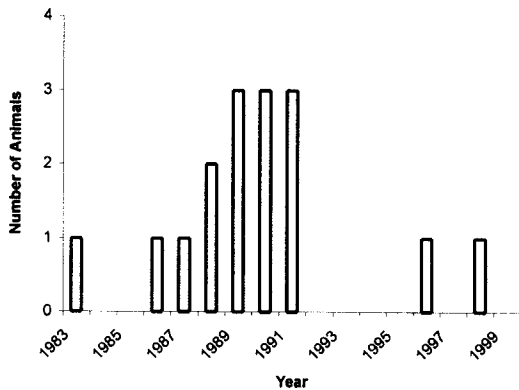


FIGURE 8. Histogram depicts the initial date of observation of proliferative vestibular lesions during the period from 1983–1998 in Florida panthers.

for both populations. Females with lesions had 16 litters over 15 yr with an average of 1.1 litter per year, and females without lesions had 20 litters with an average of 1.3 litters per year. When numbers of panthers with histologic changes were compared between free-ranging parous and nulliparous females, there was no significant difference.

DISCUSSION

In this study, the lesions in the vestibulum vaginae had similar histologic appearances, although there was variability in the degree of epithelial hyperplasia and hypertrophy, size and shape of vestibular papillae, and the severity and location of inflammation. The cause of the vestibular lesions in Florida panthers remains unknown. The clustering of cases first observed from 1986 to 1992 suggests the lesions were due to an infectious cause or transient environmental process. There was no association between the lesion and systemic illness in the panthers. The vestibular lesions did not resemble those associated with vulvar infections described in domestic animals (Kennedy et al., 1993; McEntee, 1990). The absence of suppuration and granulomatous reactions decreases the likelihood of a fungal or bacterial etiology. Furthermore, neither fungal hyphae nor bacterial colonies were

observed by histologic examination with special stains. Viral inclusions were not detected by light microscopy, and ultrastructural studies did not reveal virus particles. The sample size for electron microscopy was small, so further specimen screening may be needed to demonstrate viral pathogens or other minute microbes such as *Mycoplasma* or *Ureaplasma*. Papillomavirus-induced proliferative glossal lesions have been observed in two free-ranging bobcats (*Felis rufus*) and two free-ranging panthers from Florida (Sundberg et al., 2000). Screening of seven animals with lesions by immunohistochemistry for papillomavirus did not reveal viral antigens. This may be due to an absence of virus, intermittent infection states, or the possibility of a unique host-species specific papillomavirus that did not react with the polyclonal antisera (Sundberg et al., 1996).

Metabolic or toxic etiologies and chronic irritation may also cause edema and swelling of the vulva and vagina, and proliferative papilloma-like lesions (Sundberg et al., 1996). Vaginal polyps can form as a consequence of chronic vaginal edema (McEntee, 1990). Hyperestrogenism, associated with functional ovarian tumors or estrogenic mycotoxicosis, can lead to vulvar edema and enlargement in domestic animals (McEntee, 1990). Ovarian abnormalities have not been identified during necropsy of any females with vestibular lesions. Wildlife species can be exposed to endocrine disrupting compounds in the environment such as phytoestrogens from paper mill effluent and synthetic estrogens (polychlorinated biphenyls, methoxychlor) that may have estrogenic effects (Kendall et al., 1995). These compounds are known to effect the reproductive system and hormone concentrations of several species including birds, fish, reptiles, and mammals (Kendall et al., 1995). Species such as fish and reptiles have a constant exposure either via oral or dermal exposure. However, dietary exposure to one contaminant-laden prey source would be unlikely in the panther because of variations in food choice

and source (Maehr et al., 1990). Preliminary studies of the estrogen and testosterone ratio have been conducted on Florida panthers focusing almost exclusively on males and the proposed relationship between cryptorchidism and abnormal spermatozoa with chemical exposure (Face-mire et al., 1995). The conclusion was that there was no significant evidence of hyperestrogenism. No conclusions could be made about females in that study. Chronic irritation may lead to vulvar papillary changes such as that observed in human females with hirsutoid papillomas (Xia et al., 1994), but would be unlikely to occur in free-ranging panthers.

The papilliferous lesions did not appear to have a noticeable affect on reproductive success in free-ranging parous females with lesions compared to females without lesions. It is possible that the exophytic and expansile nature of the papillary vestibular lesions predisposed them to abrasion and decreased the vestibular lumen size leading to pain during coitus. However, no observations were made during the breeding process to substantiate this. No corresponding lesions have been noted on the male lower genital tract.

ACKNOWLEDGMENTS

We extend our appreciation for the telemetry and capture expertise provided by O. L. Bass, D. Jansen, E. D. Land, M. A. Lotz, D. Maehr, R. McBride, J. W. McCown, and J. C. Roof. We thank J. P. Sundberg for providing immunohistochemical analyses of vaginal samples and for insightful review of this manuscript. We thank K. Kelly for preparing sections for electron microscopy and providing photographs. We also extend our deepest thanks to D. Singler and B. Hutson for additional data extraction and statistical support, respectively. Funding for this study was provided through the Florida Fish and Wildlife Conservation Commission, the Florida Panther Research and Management Trust Fund, the Florida Non-game Wildlife Trust Fund, and the Endangered Species Project E-1. Published as University of Florida College of Veterinary Medicine Journal Series No. 594.

LITERATURE CITED

- ARRINGTON, J. 1994. Bacteria, fungi and other microorganisms. *In* Laboratory methods in histotechnology, 2nd Edition, E. B. Prophet, B. Mills, J. B. Arrington, and L. H. Sobin (eds.). American Registry of Pathology, Washington, D.C., pp. 203–234.
- BARSANTI, J. A. 1998. Genitourinary infections. *In* Infectious diseases of the dog and cat, 2nd Edition, C. E. Greene (ed.). W. B. Saunders Company, Philadelphia, Pennsylvania, pp. 626–640.
- BOZZOLA, J., AND L. RUSSELL. 1992. Electron microscopy. Jones and Bartlett, Boston, Massachusetts, 519 pp.
- FACEMIRE, C. F., T. S. GROSS, AND L. J. GUILLETTE, JR. 1995. Reproductive impairment in the Florida panther: Nature or Nurture? *Environmental Health Perspectives* 103 (supplement 4): 79–86.
- GASKEL, R., AND S. DAWSON. 1998. Feline respiratory disease. *In* Infectious diseases of the dog and cat, 2nd Edition, C. E. Greene (ed.). W. B. Saunders Company, Philadelphia, Pennsylvania, pp. 97–106.
- GREENE, C. E. 1998. Mycoplasma, Ureaplasma, and L-form infections. *In* Infectious diseases of the dog and cat, 2nd Edition, C. E. Greene (ed.). W. B. Saunders Company, Philadelphia, Pennsylvania, pp. 174–178.
- HAINES, D. M., AND B. J. CHELACK. 1991. Technical considerations for developing enzyme immunohistochemical staining procedures on formalin-fixed paraffin-embedded tissues for diagnostic pathology. *Journal of Veterinary Diagnostic Investigation* 3: 101–112.
- HOMER, B. L., A. BIRKENHEUER, B. HALL, M. DUNBAR, J. SUNDBERG, AND M. ROELKE. 1995. Characterization of proliferative vestibulo-vaginitis in cougars (*Felis concolor* spp.). *Veterinary Pathology* 32: 583.
- KENDALL, R., R. DICKERSON, J. GEISY, AND W. SUK (EDS.). 1995. Principles and processes for evaluating endocrine disruption in wildlife, 1st Edition. SETAC Press, Pensacola, Florida, 491 pp.
- KENNEDY, P. C., AND R. B. MILLER. 1993. The female genital system. *In* Pathology of domestic animals, 4th Edition, K. V. Jubb, P. C. Kennedy, and N. Palmer (eds.). Academic Press, San Diego, California, pp. 446–454.
- MAEHR, D. S., R. C. BELDEN, E. D. LAND, AND L. WILKINS. 1990. Food habits of panthers in southwest Florida. *The Journal of Wildlife Management* 54: 420–423.
- MCENTEE, K. 1990. Reproductive pathology of domestic animals, Academic Press, San Diego, California, 401 pp.
- ROELKE, M. E., AND C. M. GLASS. 1992. Florida panther biomedical studies—annual performance report. Florida Game and Fresh Water Fish Commission. Gainesville, Florida, 76 pp.

- SUNDBERG, J. P., M. VAN RANST, R. D. BURK, AND A. B. JENSON. 1996. The nonhuman (animal) papillomaviruses: Host range, epitope conservation, and molecular diversity. *In* Human papillomavirus-infections in dermatology and venereology, G. Gross, and G. von Krogh (eds.). CRC-Press, Boca Raton, Florida, pp. 47–68.
- , VAN RANST, M., R. MONTALI, B. L. HOMER, W. H. MILLER, P. H. ROWLAND, D. W. SCOTT, J. J. ENGLAND, R. W. DUNSTAN, I. MIKAELIAN, AND A. B. JENSON. 2000. Feline papillomas and papillomaviruses. *Veterinary Pathology* 37: 1–10.
- XIA, M., W. ZHU, H. LI, Q. LU, W. WANG, AND Z. XU. 1994. Hirsutoid papillomas of the vulvae: Absences of human papilloma virus (HPV) DNA by polymerase chain reaction. *Journal of Dermatological Science* 7: 84–88.

Received for publication 21 February 2000.