

## **Chytridiomycosis in Native Arizona Frogs**

Authors: Bradley, Gregory A., Rosen, Philip C., Sredl, Michael J., Jones, Thomas R., and Longcore, Joyce E.

Source: Journal of Wildlife Diseases, 38(1) : 206-212

Published By: Wildlife Disease Association

URL: <https://doi.org/10.7589/0090-3558-38.1.206>

---

The BioOne Digital Library (<https://bioone.org/>) provides worldwide distribution for more than 580 journals and eBooks from BioOne's community of over 150 nonprofit societies, research institutions, and university presses in the biological, ecological, and environmental sciences. The BioOne Digital Library encompasses the flagship aggregation BioOne Complete (<https://bioone.org/subscribe>), the BioOne Complete Archive (<https://bioone.org/archive>), and the BioOne eBooks program offerings ESA eBook Collection (<https://bioone.org/esa-ebooks>) and CSIRO Publishing BioSelect Collection (<https://bioone.org/csiro-ebooks>).

Your use of this PDF, the BioOne Digital Library, and all posted and associated content indicates your acceptance of BioOne's Terms of Use, available at [www.bioone.org/terms-of-use](http://www.bioone.org/terms-of-use).

Usage of BioOne Digital Library content is strictly limited to personal, educational, and non-commercial use. Commercial inquiries or rights and permissions requests should be directed to the individual publisher as copyright holder.

---

BioOne is an innovative nonprofit that sees sustainable scholarly publishing as an inherently collaborative enterprise connecting authors, nonprofit publishers, academic institutions, research libraries, and research funders in the common goal of maximizing access to critical research.

## Chytridiomycosis in Native Arizona Frogs

Gregory A. Bradley,<sup>1,6</sup> Philip C. Rosen,<sup>2</sup> Michael J. Sredl,<sup>3</sup> Thomas R. Jones,<sup>4</sup> and Joyce E. Longcore<sup>5</sup>

<sup>1</sup> Arizona Veterinary Diagnostic Laboratory, Department of Veterinary Science and Microbiology, The University of Arizona, 2831 N. Freeway, Tucson, Arizona 85705, USA; <sup>2</sup> Department of Ecology and Evolutionary Biology, The University of Arizona, Tucson, Arizona 85721, USA; <sup>3</sup> Arizona Game and Fish Department, 2221 W. Greenway Road, Phoenix, Arizona 85023, USA; <sup>4</sup> Department of Biology, Grand Canyon University, 3300 W. Camelback Road, Phoenix, Arizona 85017, USA; <sup>5</sup> Department of Biological Sciences, University of Maine, Orono, Maine, 04469, USA; <sup>6</sup> Corresponding author (email: gabrad@ag.arizona.edu).

**ABSTRACT:** Twenty seven adult/sub-adult lowland leopard frogs (*Rana yavapaiensis*), two larval lowland leopard frogs, two adult Chirichua leopard frogs (*Rana chiricahuensis*), and two adult canyon tree frogs (*Hyla arenicolor*) collected from populations experiencing mortality events at eight sites were found to have characteristic lesions of chytrid fungus infection (*Batrachochytrium dendrobatidis*). The mortalities occurred during December 1992 and between October and February in 1997–98 and December and February in 1998–99. Gross lesions varied from none to diffuse reddening of the skin of the abdomen, pelvic area, and legs. Microscopic lesions were characteristic of those previously reported for the disease and included diffuse epidermal hyperplasia, hyperkeratosis, and colonization of the keratinized layers of the epidermis by sporangia of the chytrid. Bacterial cultures did not yield a primary pathogenic agent. Virus isolation from frog tissues was negative. *Batrachochytrium dendrobatidis* was isolated from the skin of two of 10 *R. yavapaiensis* and one of two *H. arenicolor* cultured following necropsy. An additional nine of 11 clinically affected or dead *R. yavapaiensis* from the same locations, but not necropsied, were culture positive for *B. dendrobatidis*.

**Key words:** Chytridiomycosis, *Batrachochytrium dendrobatidis*, dermatitis, *Rana yavapaiensis*, *Rana chiricahuensis*, *Hyla arenicolor*, lowland leopard frog, canyon tree frog.

Chytridiomycosis is a recently recognized cutaneous infection of both wild frogs and toads (Berger et al., 1998; Bosch et al., 2000) and captive frogs (Pessier et al., 1999) caused by the fungal agent *Batrachochytrium dendrobatidis*. The organism has been identified as the proximate cause of massive frog mortalities and some local extinctions in the montane forests of Central America and Australia (Berger et al., 1998), mass mortality in the common midwife toad (*Alytes obstetricans*) of central Spain (Bosch et al., 2000), and as a

cause of mortality in frogs in a zoological collection (Pessier et al., 1999). Clinical signs include lethargy, abnormal posture, loss of the righting reflex, and death (Daszak et al., 1999). The infection results in a severe diffuse dermatitis characterized by epidermal hyperplasia, hyperkeratosis, and variable degrees of cutaneous ulceration and hyperemia. Spherical structures consisting of developing, mature, and empty zoosporangia of fungal organisms are identifiable microscopically in the keratinized layers of the epidermis. Motile zoospores are produced in culture (Longcore, 1999) and it is likely that the organism is transmitted by the release of these zoospores into the water from sporangia that eventually contact a susceptible animal, penetrate the skin, and establish an infection (Pessier et al., 1999). This mechanism would explain why lesions are more severe on the ventral parts of the body as these areas are in more frequent contact with water (Pessier et al., 1999). The alterations in the skin, epidermal hyperplasia and hyperkeratosis in particular, are postulated to cause mortality by interfering with skin functions, including maintaining fluid and electrolyte homeostasis, respiration, and the skin's role as a barrier to toxic and infectious agents (Berger et al., 1998; Pessier et al., 1999). The possibility that the chytrid organism produces a toxin has been mentioned but as yet is unsubstantiated (Berger et al., 1998). Here we report mortality in wild populations of three Arizona frog species associated with *B. dendrobatidis* infection.

During December of 1992 and between the months of October through February

TABLE 1. Geographic location, dates of mortalities, and results of histologic examination and fungal cultures in frogs with chytridiomycosis in Arizona (USA).

Species	Location/elevation <sup>a</sup>	Date of collection	Number with lesions <sup>b</sup> / number examined	Culture +/- number cultured
<i>Rana yavapaiensis</i>	Big Spring 32°56'N, 109°48'W 920 m	December 1992	3/3	ND <sup>d</sup>
	Blue River Crossing 33°17'N, 109°12'W 1280 m	November 1997	7/7	ND
	Cienega Creek 32°02'N, 110°32'W 1336 m	February 1998 February 1999	2/2 1/1	ND ND
	Cottonwood Creek 33°47'N, 112°18'W 570 m	December 1998 February 1999	6/6 ND	1/6 1/1
	Rock Creek 33°44'N, 111°30'W 1585 m	January 1999 January 1999	3/3 ND	ND 8/10
	Montrose Canyon 32°28'N, 110°55'W 890 m	January 1999	6/6 <sup>e</sup>	1/4
	Buehman Canyon 32°25'N, 110°36'W 975 m	February 1999	1/1	ND
	San Bernardino Wildlife Refuge 31°28'N, 110°55'W 1148 m	October 1997	2/2	ND
	Montrose Canyon 32°28'N, 110°55'W 890 m	January 1999	2/2	1/2
<i>Rana chiricahuensis</i>	San Bernardino Wildlife Refuge 31°28'N, 110°55'W 1148 m	October 1997	2/2	ND
<i>Hyla arenicolor</i>	Montrose Canyon 32°28'N, 110°55'W 890 m	January 1999	2/2	1/2

<sup>a</sup> Elevation in meters above sea level.<sup>b</sup> Characteristic lesions and chytrid fungus identified histologically in skin.<sup>c</sup> *Batrachochytrium dendrobatidis* cultured from skin.<sup>d</sup> ND = not done.<sup>e</sup> Includes two larval *R. yavapaiensis*.

in 1997–98 and December through February in 1998–99, field biologists reported large numbers of dead and dying frogs from eight different locations in eastern, central, and southern Arizona (USA; Table 1). Few clinically unaffected adult or subadult frogs were seen at the sites during these events, suggesting high morbidity and mortality. Larval stages appeared healthy. Dead and dying frogs were collected, placed in individual plastic bags, and taken to the Arizona Veterinary Diagnostic Laboratory (AZVDL; Tuscon, Arizona) for examination. Field personnel disinfected equipment after use by im-

mersion in 5–10% chlorine bleach solution, a 3.2% solution of didecyl dimethyl ammonium chloride (Waxie Enterprises Incorporated, San Diego, California, USA), or 70% alcohol. An exception was the Cottonwood Creek site where equipment was air-dried between uses. Cottonwood Creek site personnel did not visit other locations. Complete necropsies were performed on 27 adult/subadult and two larval *Rana yavapaiensis*, two adult *Rana chiricahuensis*, and two adult *Hyla arenicolor*. Frogs that arrived alive were euthanized by carbon dioxide (US Airwelding, Phoenix, Arizona) inhalation prior to nec-

ropsy (Beaver et al., 2001). Unused tissues from the necropsies were incinerated. Contaminated surfaces and instruments were disinfected by scrubbing with Beta-dine® surgical scrub (The Purdue Frederick Company, Norwalk, Connecticut, USA) after each use.

Gross lesions were found in eight of 27 *R. yavapaiensis* adults and were characterized by diffuse reddening of the skin of the abdomen, medial thighs, pelvis, and feet. Similar erythematous changes were not found in the two *R. chiricahuensis* or the two *H. arenicolor*. One of the subadult *R. yavapaiensis* and one *H. arenicolor* from the Montrose Canyon site (Table 1) had scattered, 1 mm diameter, red nodules consistent with embedded trombiculid mites in the skin of the pelvis, thighs, and abdomen. Gross lesions were not observed in the larval *R. yavapaiensis*. Tissue samples, including the skin of the pelvis, abdomen, and legs, liver, lung, heart, kidney, spleen, stomach, small and large intestine, gonads, skeletal muscle, esophagus, and the keratinized mouthparts (tadpoles only), were collected at necropsy, fixed in 10% formalin, routinely processed, sectioned at 5 µm, and stained with hematoxylin and eosin for light microscopic examination. For bacterial cultures, fresh liver, lung, skin, and small intestine were collected at necropsy from the 31 frogs and were inoculated onto trypticase soy agar plates with 5% sheep blood and tergitol-7 agar (Hardy Diagnostics, Higley, Arizona). Duplicate blood agar plates were incubated at 37 C and room temperature. Tergitol-7 inoculated plates (Hardy Diagnostics) were incubated at 37 C only. The culture plates were examined at 48 hr for pathogenic bacteria (Carter and Cole, 1990). For virus isolation, frozen samples of skin, liver, lung, and small intestine were homogenized, passed through a 0.45 µm filter, and inoculated onto a monolayer of brown bullhead trunk cells (BB, American Type Culture Collection, Manassas, Virginia, USA; CCL 59) (Ganzhorn and LaPatra, 1994). Cells were incubated at

room temperature and observed for 3 wk. If changes suspicious of cytopathic effect were observed, one blind passage was performed and the culture incubated for an additional 3 wk. Isolation of chytrid fungus was performed in the laboratory of one of us (JCL) following the procedures as previously described (Longcore et al., 1999). Skin of six *R. yavapaiensis* collected from Cottonwood Creek (Table 1) and four *R. yavapaiensis* and two *H. arenicolor* collected from Montrose Canyon were packed on gel ice-packs and shipped overnight following necropsy at the AZVDL. An additional ten *R. yavapaiensis* from Rock Creek (Table 1) and one *R. yavapaiensis* from Cottonwood Creek, collected at the same time but not subjected to necropsy, were shipped directly to the laboratory for culture. The two larval *R. yavapaiensis* were not cultured.

The skin sections from all adult and subadult frogs contained similar lesions (Fig. 1), including diffuse epidermal hyperplasia, mild to moderate hyperkeratosis, intercellular edema, erosion, and ulceration. The superficial, keratinized layers of the epidermis contained large numbers of *B. dendrobatidis* sporangia. These were recognized as 7–15 µm diameter spherical structures with an amorphous, lightly basophilic internal structure, and multiple nuclei surrounded by a smooth cell wall or similar-sized, spherical structures with internal subdivisions. Some sporangia were flask-shaped. These histologic features were the same as those described by Berger et al. (1998) and Pessier et al. (1999) for the organism that caused chytridiomycosis in wild and caged amphibians. Skin sections from the majority of frogs did not contain significant numbers of inflammatory cells in the dermis or epidermis, however, sections from a few contained minimal to moderate, dermal and/or deep epidermal, infiltrations of lymphocytes, macrophages, and neutrophils. The keratinized mouthparts, but not the epidermis of the two *R. yavapaiensis* tadpoles, contained morphologic lesions of mucosal epithelial

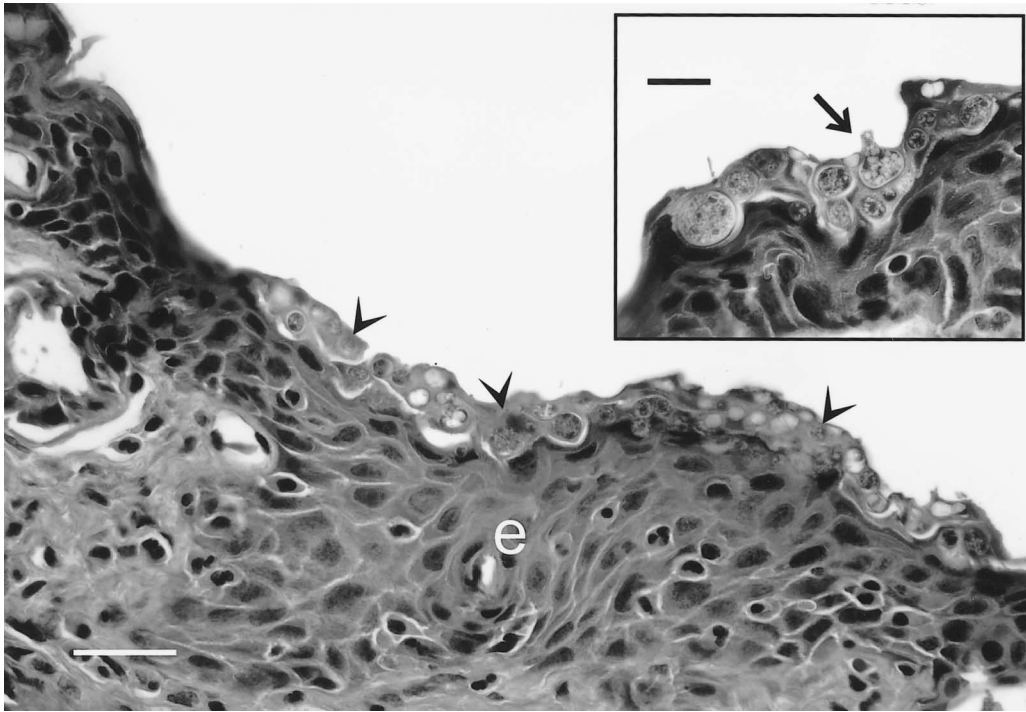


FIGURE 1. Skin of a *Rana yavapaiensis* with chytridiomycosis demonstrating diffuse epidermal hyperplasia (e) and colonization of the hyperkeratotic surface by chytrid sporangia (arrow heads). H&E. Bar = 45  $\mu$ m. Inset: Higher magnification of the keratinized layer of the epidermis with several spherical and one flask-shaped (arrow) chytrid sporangia. H&E Bar = 15  $\mu$ m.

hyperplasia and hyperkeratosis with colonization of the keratinized layers by chytrid sporangia. There was mild intercellular edema and intercellular infiltration of lymphocytes, neutrophils, and macrophages in the epidermis. Other tissues contained no significant lesions.

No one species of bacterial organism was consistently recovered from the frog tissues. In general, mixed enteric organisms often including *Aeromonas* sp., were isolated from one or more of the tissues and tended to occur in greater numbers and with a wider tissue distribution in the frogs that were dead when received for necropsy. Frogs received live had smaller numbers of bacteria or yielded no bacterial growth from internal organs. The tissue cultures were all negative for cytopathic effect indicating the absence of cytopathic viruses. *Batrachochytrium dendrobatidis* was isolated from the skin of one of four

*R. yavapaiensis* and one of two *H. arenicolor* collected from Montrose Canyon, two of seven *R. yavapaiensis* from Cottonwood Creek and eight of 10 *R. yavapaiensis* from Rock Creek (Table 1). Skin specimens from the other frogs were either overgrown with contaminant oomycete fungi or yielded negative results due to freezing by contact with the ice pack during transport.

Both the gross and microscopic lesions found in the frogs were consistent with those described for chytridiomycosis (Berger et al., 1998) and this disease was considered the cause of death in all of the frogs. In addition, the causative agent, *B. dendrobatidis*, was isolated from the skin of several of the frogs. The bacterial isolates were considered contaminants. No consistent bacterial agents were identified in the culture specimens and none of the frogs contained microscopic lesions com-



patible with bacterial infection. The contribution of viral pathogens was ruled out by the negative culture results and lack of virus-associated lesions at necropsy.

All seven native ranid frog species in Arizona have experienced significant population declines in all or parts of their range (Clarkson and Rorabaugh, 1989; Hale et al., 1995; Sredl, 1997). The state of Arizona considers six of these species wildlife of special concern. Two species are categorized as endangered (*R. tarahumarae* and *R. blairi*), one as threatened (*R. chiricahuensis*), two as candidates (*R. pipiens* and *R. yavapaiensis*), and one as extinct (*R. onca*). The recently described *R. subaquavocalis* has not yet been considered for this list. Introduction of non-native species and habitat modification and loss have been considered important contributory factors in these declines (Jennings and Hayes, 1994; Rosen and Schwalbe, 1995; Rosen et al., 1996), however, chytridiomycosis may prove to be equally important and the presence of this disease in already threatened populations of native frogs is of great concern.

The apparent seasonality of the mortalities in these populations is of interest. All of the die-offs were recorded in the cooler months from October to February. The preference of *B. dendrobatidis* for cooler temperatures in culture has been noted (Longcore et al., 1999). In broth, the organism grows fastest at 23 C. Growth still occurs at 28 C but at a slower rate and substantial growth was not observed in cultures incubated at 29 C for 2 wk. The minimum temperature at which the organism can be cultured has not been defined. Stock cultures of *B. dendrobatidis*, in broth, continue to grow and produce zoospores when refrigerated at 6 C (J. E. Longcore, pers. obser.). However, the fungus is reportedly susceptible to freezing (Berger et al., 2000). This temperature sensitivity has been postulated as an explanation for the localization of outbreaks in Central America and Australia to montane locales where cooler temperatures are pre-

sent (Berger et al., 1998). Estimates of winter (December, January, February) average air and water temperatures from the sites where our dead frogs were found were 16.9 C and 12.9 C respectively. Estimates of summer (June, July, August) average air and water temperatures from these sites (when no dead frogs were found) were 30.2 C and 25.8 C respectively. Maximum temperatures in the region frequently exceed 38 C during the summer months. Mean air temperatures generally remain well above freezing during the winter (Western Regional Climate Center, Desert Research Institute, University and Community College System of Nevada, Reno, Nevada, USA; <http://www.wrcc.dri.edu/cgi-bin/cliRECtMpl?aztu17>). Therefore, during the warmer months, temperatures may rise to the range within which the organism cannot effectively reproduce in adequate numbers to cause disease.

Little quantitative data are available regarding the activity of these species of frogs during the cooler months and how this might influence disease transmission. They may become less active but do not hibernate *per se*. Winter activity varies from high in warm years to infrequent and sporadic in colder years and occurs both day and night. They are often present at high densities and co-mingle by chance either on the banks or in the water (M. J. Sredl, pers. obser.). *Rana yavapaiensis* breeds during late September to early November and again from late January through June (Ruibal, 1959; Collins and Lewis, 1979; Frost and Platz, 1983; Sartorius and Rosen, 2000; M. J. Sredl, pers. obser.) thus overlapping the early and late ranges of the die-offs but not matching it entirely. How these behaviors affect the transmission of the chytrid is unclear. Certainly some contact between frogs appears to occur during the season when the disease has been seen. However, since the disease is likely transmitted by motile zoospores released into the water, close con-

tact between frogs may not be necessary for disease transmission.

How *B. dendrobatidis* persists in the environment between outbreaks has not been established. The organisms are susceptible to both desiccation and freezing (Berger et al., 2000). To date, a resting spore stage for this organism has not been identified. Several possible survival mechanisms have been proposed. It may exist in the environment as a saprobe. *Batrachochytrium dendrobatidis* colonizes keratinized tissues exclusively and may use amphibian keratin as a food source (Daszak et al., 1999). The organism has been grown in boiled snakeskin in the laboratory (Longcore et al., 1999). Shed skin or animal carcasses in the water may provide a substrate for growth of the organism between outbreaks (Daszak et al., 1999). Secondly, it may survive in the keratinized mouthparts of tadpoles until the next outbreak (Berger et al., 1998). The tadpoles apparently do not suffer ill effects of the infection, probably because their epidermis is not keratinized and the infection remains localized to the keratinized mouthparts. Larvae of *R. yavapaiensis* may metamorphose in the same year they were oviposited or remain pre-metamorphic through the winter (Collins and Lewis, 1979). The larval period may be as short as 3 mo and as long as 9 mo (M. J. Sredl, pers. obser.). Thus larvae may serve as a bridge between seasons. Finally, healthy frogs of exotic and/or native species may serve as a reservoir of infection. In Australia, apparently healthy cane toads (*Bufo marinus*) have been found to harbor small numbers of chytrid organisms in the skin of the digits (Berger et al., 2000). Healthy cricket frogs (*Acris crepitans*) in Illinois (USA) harbored small numbers of the organism in focally hyperkeratotic axillary and inguinal skin folds (Pessier et al., 1999). We have observed the same low-level infection in healthy bullfrogs (*Rana castesbiana*) at the Cienega Creek site in Arizona (data not shown) but exotic species have not been found at all sites.

We thank D. K. Nichols for help with the initial identification of the chytrid organism in tissue sections and E. Enderson, B. Healy, V. Miera, S. Seim, F. Sredl, D. Swann, L. Thirkill, S. Weimann, D. Caldwell, K. Cobble, J. Fonseca, S. Hale, A. Schwendiman, A. Titcomb, E. Wallace, C. Wolner, and C. Rose for their initiative in searching for and collecting field samples upon which this study is based. Isolation of *Batrachochytrium* cultures was supported by a seed grant to JEL from the Declining Amphibian Populations Task Force.

#### LITERATURE CITED

- BEAVER, B. V., W. REED, S. LEARY, B. MCKIERNAN, F. BAIN, R. SCHULTZ, B. T. BENNET, P. PASCOE, E. SHULL, L. C. CORK, R. FRANCIS-FLOYD, K. D. AMASS, R. JOHNSON, R. H. SCHMIDT, W. UNDERWOOD, G. W. THORNTON, AND B. KOHN. 2001. 2000 Report of the AVMA panel on euthanasia. *Journal of the American Veterinary Medical Association* 218: 670–696.
- BERGER, L., R. SPEARE, P. DASZAK, D. E. GREEN, A. A. CUNNINGHAM, C. L. GOGGIN, R. SLOCOMBE, M. A. RAGAN, A. D. HYATT, K. R. McDONALD, H. B. HINES, K. R. LIPS, G. MARANTELLI, AND H. PARKES. 1998. Chytridiomycosis causes amphibian mortality associated with population declines in the rain forests of Australia and Central America. *Proceedings of the National Academy of Science USA* 95: 9031–9036.
- , ———, AND A. D. HYATT. 2000. Chytrid fungi and amphibian declines: Overview, implications and future directions. *In* *Declines and disappearances of Australian frogs*, A. Campbell (ed.). Environmental Australia, Canberra, Australia, pp. 21–31.
- BOSCH, J., I. MARTINEZ-SOLANO, AND M. GARCIA-PARIS. 2001. Evidence of a chytrid fungus infection involved in the decline of the common midwife toad (*Alytes obstetricans*) in protected areas of central Spain. *Biological Conservation* 97: 331–337.
- CARTER, G. R., AND J. R. COLE. 1990. Diagnostic procedures in veterinary bacteriology and mycology. 5th Edition. Academic Press, New York, New York, 620 pp.
- CLARKSON, R. W., AND J. C. RORABAUGH. 1989. Status of leopard frogs (*Rana pipiens* complex: Ranidae) in Arizona and southeastern California. *Southwestern Naturalist* 34: 531–538.
- COLLINS, J. P., AND M. A. LEWIS. 1979. Overwintering tadpoles and breeding season variation in the *Rana pipiens* complex in Arizona. *Southwestern Naturalist* 24: 371–373.

- DASZAK, P., L. BERGER, A. A. CUNNINGHAM, A. D. HYATT, D. E. GREEN, AND R. SPEARE. 1999. Emerging infectious diseases and amphibian population declines. *Emerging Infectious Diseases* 5: 735–748.
- FROST, J. S., AND J. E. PLATZ. 1983. Comparative assessment of modes of reproductive isolation among four species of leopard frogs (*Rana pipiens* complex) in Arizona. *Evolution* 37: 66–78.
- GANZHORN, J., AND S. E. LAPATRA. 1994. General procedures for virology. In *Suggested procedures for the detection and identification of certain finfish and shellfish pathogens*. 4th Edition, Version 1. J. C. Thoesen (ed.). Fish Health Section, American Fisheries Society, Bethesda, Maryland, pp. 1–3.
- HALE, S. F., C. R. SCHWALBE, J. L. JARCHOW, C. MAY, C. H. LOWE, AND T. B. JOHNSON. 1995. Disappearance of the Tarahumara frog. In *Our Living Resources: A report to the nation on the distribution, abundance and health of U.S. plants, animals, and ecosystems*, E. T. LaRoe, G. S. Farris, C. E. Puckett, P. D. Doran, and M. J. Mac. (eds.). U.S. Department of Interior, National Biological Service, Washington, D.C., pp. 138–140.
- JENNINGS, M. R., AND M. P. HAYES. 1994. The decline of native ranids in the desert southwest. In *Herpetology of the North American Deserts: Proceedings of a symposium*, P. R. Brown and J. W. Wright (eds.). Southwestern Association of Herpetologists Special Publication 5, Los Angeles, California, pp. 183–211.
- LONGCORE, J. E., A. P. PESSIER, AND D. K. NICHOLS. 1999. *Batrachochytrium dendrobatidis* gen. et sp. nov., a chytrid pathogenic to amphibians. *Mycologia* 91: 219–227.
- PESSIER, A. P., D. K. NICHOLS, J. E. LONGCORE, AND M. S. FULLER. 1999. Cutaneous chytridiomycosis in poison dart frogs (*Dendrobates* spp.) and White's tree frogs (*Litoria caerulea*). *Journal of Veterinary Diagnostic Investigation* 11: 194–199.
- ROSEN, P. C., AND C. R. SCHWALBE. 1995. Bullfrogs: Introduced predators in southwestern wetlands. In *Our Living Resources: A report to the nation on the distribution, abundance, and health of U.S. plants, animals, and ecosystems*, E. T. LaRoe, G. S. Farris, C. E. Puckett, P. D. Doran, and M. J. Mac (eds.). U.S. Department of Interior, National Biological Service, Washington, D.C., pp. 452–454.
- , ———, AND S. S. SARTORIUS. 1996. Effects of introduced fishes and bullfrogs on the decline of the Chiricahua leopard frog in southeastern Arizona. Final Report I92052. Arizona Game and Fish Department, Heritage Program. Arizona Game and Fish Department, 2221 W. Greenway Road, Phoenix, Arizona, 85023.
- RUIBAL, R. 1959. Ecology of a brackish water population of *Rana pipiens*. *Copeia* 1959: 315–322.
- SARTORIUS, S. S., AND P. C. ROSEN. 2000. Breeding phenology of the lowland leopard (*Rana yavapaiensis*): Implications for conservation and ecology. *Southwestern Naturalist* 45: 267–273.
- SREDL, M. J. 1997. Ranid frog conservation and management. Technical Report 121, Nongame Branch, Arizona Game and Fish Department, Phoenix, Arizona, 89 pp.

Received for publication 16 July 2000.