

Aberrant *Toxocara canis* in a Red Fox

Gregory S. Pietsch,¹ Gary Averbeck,¹ and Bert Stromberg^{1,2} ¹Department of Veterinary PathoBiology, College of Veterinary Medicine, University of Minnesota, St. Paul, Minnesota 55108, USA, ²Corresponding author (e-mail: b-stro@umn.edu)

ABSTRACT: During necropsy of a red fox (*Vulpes vulpes*) heart an adult, male *Toxocara canis* was found under the pericardium at the junction of the right ventricle and right atrium. The life cycle of *T. canis* is complex and includes tracheal and somatic migrations of larvae, and they can be found in many tissues throughout the host's body. However, it is rare for adult ascarids to be recovered outside of the small intestine. This is the first report of an adult *T. canis* inside the pericardial space.

Key words: Aberrant parasitism, ascarid, case report, pericardium, red fox, *Toxocara canis*, *Vulpes vulpes*.

The heart from a male red fox (*Vulpes vulpes*) was collected by a hunter on February 16, 2000 near Lowry, Minnesota (45°39'N, 95°31'W). The heart was frozen and submitted to the Laboratory of Parasitology at the College of Veterinary Medicine, University of Minnesota (St. Paul, Minnesota, USA). While dissecting this specimen the pericardium was incised and reflected away from the heart and a large, stout, whitish nematode was in the coronary groove at the junction of the right atrium and ventricle (Fig. 1). The worm was removed and placed in lactic acid (85%) to be cleared for examination. The worm was 7.5 cm long, approximately 1 mm wide at midshaft, had two slightly unequal winged spicules, a post-cloacal finger-like projection with five post-cloacal papillae on each side, a double subventral papilla on each side of the cloaca, a ventriculus at the end of the esophagus, and >17 pre-cloacal papillae. On the basis of morphology the worm was identified as an adult male *Toxocara canis* after the description of Sprent (1958).

Toxocara canis is a common intestinal parasite of both wild and domestic canids including the red fox (Soulsby, 1982). Blagburn et al. (1996) reported that 14.5% of dogs surveyed in the United States had

patent *T. canis* infections. The life cycle of *T. canis* is complex and was reviewed by Overgaauw (1997). Infections occur through several modes including ingestion of infective eggs, intrauterine, transmammary, and ingestion of paratenic hosts. Adults develop in the intestines either directly (paratenic hosts) or by tracheal migration (intrauterine, transmammary, or ingestion of infective eggs). During tracheal migration, larvae penetrate the mucosal wall and migrate to the liver through the lymphatics, mesenteric vessels, and portal vein. After larvae have reached the liver they migrate to the lungs through the hepatic vein, vena cava, heart, and pulmonary arteries. Once they reach the pulmonary capillaries they break through the alveolar wall, are coughed into the pharynx, and swallowed. Adult worms may be found in the duodenum 20–30 days post-infection.

After young canids reach 1–2 mo of age a phenomenon known as age resistance occurs. Fewer *T. canis* larvae undergo tracheal migration and produce patent infections. Instead, larvae undergo somatic migrations (Greve, 1971; Oshima, 1976). During somatic migrations, *T. canis* larvae migrate throughout the body including skeletal and cardiac muscle, kidneys, and neural tissue. Acquired immunity is an important factor in age-resistance phenomenon (Barriga, 1988). In aberrant host species these migrations are referred to as visceral larva migrans (Beaver et al., 1952).

While somatic migrations of larvae are well known in all ascarid species, it is unusual for any adult ascarid to be found outside the intestine. Adult ascarids survive by feeding on intestinal contents and an adequate source of nutrition is generally not found in other areas of the body. Sprent

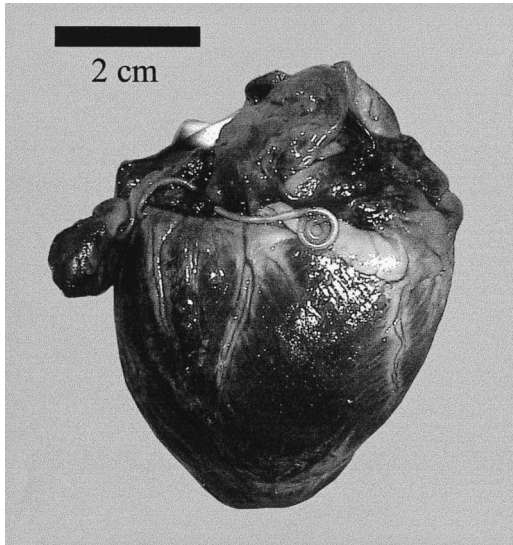


FIGURE 1. An adult, male *Toxocara canis* in situ in the pericardial space of a male red fox from near Lowry, Minnesota.

(1958) reported 2nd and 3rd stage larvae in the cardiac muscle of two young domestic dogs, but our case is the first report of an adult *T. canis* to be found in the pericardial space.

Unfortunately only the heart was submitted and no further information regarding the age, health, or parasite burden of this fox is available. This report is noteworthy because despite the propensity for ascarid larvae to migrate to virtually all areas of the body, there are few reports of aberrant adult ascarids. There are proba-

bly no management implications other than sanitation for managed or farmed foxes.

The authors thank L. Lewis for submitting this sample and the College of Veterinary Medicine Friends and Alumni Association for their support of this study.

LITERATURE CITED

- BARRIGA, O. O. 1988. A critical look at the importance, prevalence and control of toxocarosis and the possibilities of immunological control. *Veterinary Parasitology* 29: 195–234.
- BEAVER, P. C., H. SNYDER, G. CARRERA, J. DENT, AND J. LAFFERTY. 1952. Chronic eosinophilia due to visceral larva migrans: Report of three cases. *Pediatrics* 9: 7–19.
- BLAGBURN, B. L., D. S. LINDSAY, J. L. VAUGHAN, N. S. RIPPEY, J. C. WRIGHT, R. C. LYNN, W. J. KELCH, G. C. RITCHIE, AND D. I. HELPER. 1996. Prevalence of canine parasites based on fecal flotation. *Compendium on Continuing Education for the Practicing Veterinarian* 18: 483–509.
- GREVE, J. H. 1971. Age resistance to *Toxocara canis* in ascarid-free dogs. *American Journal of Veterinary Research* 32: 1185–1192.
- OSHIMA, T. 1976. Observations of the age resistance, eosinophilia, and larval behavior in the helminth-free beagles infected with *Toxocara canis*. *Japanese Journal of Parasitology* 25: 447–455.
- OVERGAAUW, P. A. 1997. Aspects of *Toxocara* epidemiology: Toxocarosis in dogs and cats. *Critical Reviews in Microbiology* 23: 233–251.
- SOULSBY, E. J. L. 1982. *Helminths, Arthropods and Protozoa of Domesticated Animals*, 7th Edition. Lea & Febiger, Philadelphia. 809 pp.
- SPRENT, J. F. A. 1958. Observations on the development of *Toxocara canis* (Werner, 1782) in the dog. *Parasitology* 48: 184–209.

Received for publication 29 November 2000