

FIRST IDENTIFICATION OF A RANAVIRUS FROM GREEN PYTHONS (CHONDROPYTHON VIRIDIS)

Authors: Hyatt, A. D., Williamson, M., Coupar, B. E. H., Middleton, D., Hengstberger, S. G., et al.

Source: Journal of Wildlife Diseases, 38(2) : 239-252

Published By: Wildlife Disease Association

URL: <https://doi.org/10.7589/0090-3558-38.2.239>

BioOne Complete (complete.BioOne.org) is a full-text database of 200 subscribed and open-access titles in the biological, ecological, and environmental sciences published by nonprofit societies, associations, museums, institutions, and presses.

Your use of this PDF, the BioOne Complete website, and all posted and associated content indicates your acceptance of BioOne's Terms of Use, available at www.bioone.org/terms-of-use.

Usage of BioOne Complete content is strictly limited to personal, educational, and non - commercial use. Commercial inquiries or rights and permissions requests should be directed to the individual publisher as copyright holder.

BioOne sees sustainable scholarly publishing as an inherently collaborative enterprise connecting authors, nonprofit publishers, academic institutions, research libraries, and research funders in the common goal of maximizing access to critical research.

FIRST IDENTIFICATION OF A RANAVIRUS FROM GREEN PYTHONS (*CHONDROPYTHON VIRIDIS*)

A. D. Hyatt,^{1,4} M. Williamson,¹ B. E. H. Coupar,¹ D. Middleton,¹ S. G. Hengstberger,¹
A. R. Gould,¹ P. Selleck,¹ T. G. Wise,¹ J. Kattenbelt,¹ A. A. Cunningham,² and J. Lee³

¹ CSIRO, Division of Animal Health, Australian Animal Health Laboratory (AAHL), P.O. Bag 24, Geelong, 3220, Australia

² Institute of Zoology, Zoological Society of London, Regent's Park, London NW1 4RY, UK

³ Australian Quarantine Inspection Service, Cairns International Airport, Australia

⁴ Corresponding author: (e-mail: alex.hyatt@li.csiro.au)

ABSTRACT: Ten juvenile green pythons (*Chondropython viridis*) died or were euthanized shortly after having been illegally imported into Australia from Indonesia in 1998. Histologic examination of two of the three snakes that died revealed moderately severe chronic ulceration of the nasal mucosa and focal or periacinar degeneration and necrosis of the liver. In addition there was severe necrotizing inflammation of the pharyngeal submucosa accompanied by numerous macrophages, heterophils, and edema. An iridovirus was isolated in culture from several tissues and characterized by immunohistochemistry, electron microscopy, enzyme-linked immunosorbent Assay, polyacrylamide gel electrophoresis, polymerase chain reaction and sequence analysis, restriction endonuclease digestion, and DNA hybridization. This is the first report of a systemic ranavirus infection in any species of snake and is a new member of the genus, *Ranavirus*.

Key words: *Chondropython viridis*, green python, iridoviruses, ranaviruses.

INTRODUCTION

Iridoviruses are large enveloped viruses that contain a linear double stranded DNA genome. The family *Iridoviridae* encompasses four genera: *Iridovirus*, *Chloriridovirus*, *Ranavirus*, *Lymphocystivirus* (van Regenmortel et al., 2000). Many ranaviruses have been identified in amphibian or piscine hosts, with the remainder isolated from reptiles (Hyatt et al., 2000). Other iridovirus-like viruses, e.g., erythrocytic viruses, have also been identified in lower vertebrates but these remain unclassified (Hyatt et al., 2000).

The frequency of reports describing iridoviruses in vertebrate poikilotherms is increasing. Within Australia, ranaviruses have been isolated from redfin perch (*Percia fluviatilis*) and rainbow trout (*Oncorhynchus mykiss*) (epizootic hematopoietic necrosis virus [EHNV]; Langdon et al., 1986) and from the ornate burrowing frog (*Limnodynastes ornatus*) (Bohle iridovirus [BIV]; Speare and Smith 1992; Hengstberger et al., 1993). Other viruses belonging to the family *Iridoviridae* have also been identified in Australian fish and reptiles. These viruses include lymphocystis viruses from a range of Australian marine fish

(Ashburner, 1975; Pearce et al., 1990; Durham et al., 1996), uncharacterized iridovirus-like viruses in ornamental fish imported into Australia (Anderson et al., 1993; Fraser et al., 1993), and an erythrocytic virus infecting a diamond python (*Morelia spilota spilota*) in Australia (Hyatt and MacCracken, unpubl. observations).

Similarly, the only large icosahedral viruses reported from snakes outside of Australia are the erythrocytic viruses. Examples of these viruses include those formerly considered to be the protozoa *Toddia* spp. (Marquardt and Yaeger, 1967; Smith et al., 1994; Johnsrude et al., 1997) and a lizard erythrocytic virus, formerly *Pirhemocytion* spp., which infects snakes as well as lizards and turtles, resulting in severe anemia characterized by anisocytosis, poikilocytosis, and albuminoid bodies in erythrocytes (Daly et al., 1980; Johnsrude et al., 1997).

The potentially lethal characteristic of ranaviruses has been demonstrated by Moody and Owens (1994), Cullen et al. (1995), and Hyatt (1998). These authors showed the potential of BIV to infect and kill fish (*Lates calcarifer*) and Australian native anurans (*Limnodynastes terraere-*

ginae and *Litoria latopalmata*) and Guatopo virus to infect and kill *Bufo marinus* and *Litoria infrafrenata*. Although the above infections were laboratory based, Mao et al. (1999) showed that at least one species of ranavirus can naturally infect animals of different taxonomic classes (fish and amphibian). Collectively, data indicate that ranaviruses have the potential to infect and kill a wide range of poikilotherms. This information indicates there is a major risk associated with the national and international trade in wildlife and the co-translocation of pathogens.

In 1998, a person was apprehended at Cairns International Airport, Queensland, Australia attempting to smuggle green pythons (*Chondropython viridis*) into Australia. This paper describes the isolation and characterization of a new species of ranavirus from two of these snakes. This is the first description of an ophidian ranavirus and the episode provides an example of the benefits of effective quarantine inspection procedures coupled with commensurate veterinary monitoring and diagnostic support.

MATERIALS AND METHODS

History

On 25 May 1998, 10 green pythons were seized at Cairns International airport after being illegally imported into Australia from Papua New Guinea. The snakes were classified as juvenile on the basis of their small size (30 cm length) and distinctive yellow coloration. The snakes were originally collected from Wamena Village (approximately 4°8'S, 138°56'E) in the Irian Jaya central highlands of Indonesia.

The pythons were confiscated and placed under specialist care in quarantine facilities without contact with other fauna. One python (snake 3, reference #980958) was depressed and anorexic compared to the other snakes and had a prolapsed rectum. The snakes were subsequently divided into two cages to reduce overcrowding. There were six in one group and four (including the sick snake) in the other. The ill snake developed what was reported as an infected mouth that was treated by debridement and administration of antibiotics. Over 4 days the other three snakes in the same group became less lively compared to the remaining animals. Fifteen days after the snakes were

seized, one of the four ill snakes (snake 1, reference #980804) died and was submitted to the Australian Animal Health Laboratory (AAHL), Geelong, Australia for examination. A third snake (snake 2, reference #980814) developed ulceration of the buccal mucosa and died 2 days later. Two days later snake 3 died. The fourth member of the group returned to normal activity without therapeutic intervention. It was subsequently euthanized together with the snakes in the second group. No clinical disease was observed in the six snakes in the second group and they were sent to a major city zoo for care until euthanasia 44 days after the death of snake 1.

Postmortem examination, histology, immunohistochemistry, and bacteriology

Postmortem examinations were performed on all 10 snakes. Samples for histopathologic examination including major viscera (liver, lung, heart, kidney, spleen, stomach, intestine), brain, and gross lesions where these were present were collected from all 10 snakes, fixed in 10% buffered neutral formalin, dehydrated in graded alcohols, and embedded in paraffin. Paraffin-embedded sections were prepared by routine methods and stained with hematoxylin and eosin. Serial sections for immunohistochemistry were stained by an indirect immunoperoxidase method developed for the detection of ranavirus EHNV as previously described (Hyatt et al., 1991). This immunoperoxidase assay has been demonstrated to cross-react with known ranaviruses grown in cell culture (Hyatt et al., 2000).

Samples from oral cavity lesions together with lung, liver, kidney, and intestines of snakes 2 and 3 were cultured on sheep blood agar and selective media for *Salmonella* spp. at room temperature and 37 C. Similar specimens were collected aseptically for virus isolation and frozen at -80 C.

Virology

Tissues collected at necropsy from each snake (Table 1) were pooled and adsorbed (10% homogenates) for 1 hr at either 22 C or 30 C onto confluent monolayers of a range of cell lines. Following infection, chinook salmon embryo cells (CHSE-14, ATCC-CRL 1681), bluegill fry cells (BF-2, ATCC-CCL91), fathead minnow cells (FHM, ATCC-CCL 42), Russell's viper heart cells (VH2, ATCC-CCL40), and gekko lung cells (GL-1, ATCC-CCL111) were incubated at 22 C, while African green monkey kidney cells (Vero, ATCC-Monash Medical Centre, Victoria, Australia) were incubated at 30 C. Vero, CHSE, and FHM cells were main-

TABLE 1. Green pythons submitted for laboratory examination.

Snake and reference numbers	History	Virus isolation
1 (980804)	Died	+
2 (980814)	Died	+
3 (980958)	Died	Not suitable for virus isolation
4 (980984)	Healthy ^a	—
5 (980984)	Healthy	—
6 (981005)	Healthy	—
7 (981006)	Healthy	—
8 (981007)	Healthy	—
9 (981008)	Healthy	—
10 (981009)	Healthy	—

^a Snake 4 was ill but recovered and was healthy at the time of euthanasia.

tained with Eagle's minimum essential medium (EMEM) and 10% fetal calf serum (FCS), GL-1 and VH2 cells with Basal Medium Eagle (BME) with Hank's salts, 10% FCS, and (x1) non essential amino acid (NEAA), and BF-2 cells were maintained with Earl's minimum essential media (MEM). The cells were monitored daily for cytopathic effect (CPE). If CPE was observed, the supernatants were examined using enzyme-linked immunosorbent assay (ELISA) and electron microscopy, as described below.

Temperature trials

A range of cells, including BF-2, CHSE-14, VH2, and GL-1 cells, were infected with the virus isolate from snake 1 and incubated at a range of temperatures (10 ± 1 C, 15 ± 1 C; 22 ± 1 C; 30 ± 1 C; 37 ± 1 C, and 40 ± 1 C). Based upon molecular data, isolate 980804 was selected as being representative of all isolates from the green pythons. The cell types were selected because they were able to survive over a wide range of temperatures. Initially, CHSE-14 and FHM cells were grown at 15 C, VH2 and GL-1 cells were grown at 30 C, and Vero cells were grown at 37 C. All cells were placed at temperatures of 10 C, 15 C, 22 C, 30 C, 37 C, and 40 C after reaching confluency to determine the temperature range over which they would survive and support virus replication. Only confluent monolayers of Vero cells were shown to survive at temperatures from 15–40 C if grown to confluency at 37 C. Virus titers were therefore determined in infected Vero cells. Specifically, Vero cells were infected at 37 C and incubated at temperatures from 10–40 C. After 7 days incubation, or when CPE affected 100% of the monolayer, the cells were

frozen and stored at -80 C. Viral titers were determined as described by Schmidt (1979).

Antigen capture ELISA

Viruses in the culture supernatant of cells manifesting CPE were analyzed using the Office International des Epizooties (OIE) accepted EHNV antigen-capture ELISA (Office International des Epizooties, 2000). This ELISA was used to determine whether the viruses cross-reacted with EHNV antisera because the assay detects a large number of ranaviruses (Hyatt et al., 2000). Details of the assay, including controls, are described by Hyatt et al. (2000).

Electron microscopy

Vero cells were seeded at approximately 1×10^6 cells in 25 cm² flasks. At approximately 18 hr postinfection (pi), infected cells were scraped and fixed as described by Hyatt et al. (2000). Processing of tissues was similar to that described by Hyatt and Selleck (1996).

Sections were examined using a Hitachi H7000 scanning-transmission electron microscope at 100 kV or a PHILIPS CM120 transmission electron microscope. The microscope was calibrated with a 2,160 lines/mm standard (ProSci Tech, P.O. Box 111 Thuringowa, Queensland 4817, Australia). Cytoplasmic virus aggregations were photographed at $\times 40,000$ magnification. The photographs were digitized and the diameter of viruses measured vertex to vertex via software package Image-Pro Plus, Media Cybernetics, 8484 Georgia Avenue, Suite 200, Silver Spring, Maryland, USA). Only viruses with electron dense cores and clearly defined capsids were measured.

Supernatants from infected Vero cells were adsorbed to parlodion filmed, carbon coated gold grids and labelled with antibodies raised against EHNV and protein A-gold (Hyatt, 1992).

Pulse radiolabelling and SDS-PAGE analysis of viral polypeptides

Vero cells were seeded at 2×10^5 cells/well in 24 well Linbro TC plates 18 hr prior to infection and cultured at room temperature (24 C, RT). Cells (approximately 90% confluent) were mock treated or inoculated with tissue culture-passaged viruses (isolates 980804, 980814; these numbers correlate to the reference number of snakes from which viruses were isolated) for 1 hr, then inoculum was replaced by fresh medium. At approximately 29 hr pi, cells were washed and incubated 30 min in deficient EMEM (Met-, Cys-; ICN Pharmaceuticals, 3300 Hyland Avenue Costa Mesa, California, USA); this was subsequently re-

placed by deficient EMEM which contained 200 $\mu\text{Ci/ml}$ of a $^{35}\text{S-Met/Cys}$ mixture (Tran ^{35}S -Label, ICN Pharmaceuticals) from 30–36 hr pi. Preparations were then processed as described by Hyatt et al. (2000).

DNA purification, restriction endonuclease analyses, and DNA hybridization

DNA was prepared from virus-infected cells (isolate 980804, frog virus 3 [FV3], EHNV, BIV, and two ranaviruses from the U.K. [RUK11], [BUK2]; Table 2) as described by Hyatt et al. (2000). Restriction endonuclease digestions, agarose gel electrophoresis, hybridization, deprobing and reprobing of membranes (with nick translated ^{32}P -labelled DNA probes) were carried out as described by Coupar et al. (1990) and Hyatt et al. (2000). DNA from vaccinia virus was used as a negative control.

Polymerase chain reaction (PCR), cloning, and sequencing

To identify relationships of isolate 980804 with known Australian ranaviruses and those held within the AAHL reference collection, phylogenetic comparisons were performed on a 586 nucleotide stretch of the genomes including the C-terminal 163 amino acids of the major capsid proteins (MCP) and on a 1469 nucleotide stretch containing the entire MCP coding region and a 3'-terminal non-coding region of the major capsid protein. DNA oligonucleotides were synthesized on a DNA synthesizer (Perkin Elmer Biosystems 850, Applied Biosystems, Foster City, California) using phosphoramidite biochemistry (Hyatt et al., 2000). Purified oligonucleotides were used to amplify regions of the viral genomes (representing the MCP, or a region thereof) to give dsDNA copies using the PCR as described by Hyatt et al. (2000). The products were either sequenced directly using the Cyclone Cycle sequencing System (GeneWorks, Rundle Mall, Adelaide, South Australia, Australia) or cloned by blunt end ligation into *Sma*I-CIP treated pUC18 after 5'-terminal phosphorylation using polynucleotide kinase (Promega, Madison, Wisconsin, USA) and then sequenced using T7 DNA polymerase and dideoxynucleotide terminators (Sequenase, USB Amersham Life Sciences, Cleveland, Ohio, USA). Analyses were performed on positive sense DNA using both Clone Manager and the sequence alignment program Align PLUS (Scientific and Educational Software, Durham, North Carolina, USA) as well as the Clustal V program subset within PCGENE (Intelligenetics, Department of Medical Biochemistry, University of Switzerland) and DNADIST and PHYLIP programs of

TABLE 2. Host and source of viruses (other than listed in Table 1) used in this study.

Virus	Host	Country or region of origin	Reference
Bohle iridovirus (BIV)	<i>Limnodymastes ornatus</i>	Australia	Hengstberger et al. (1993)
Frog virus 3 (FV3)	<i>Rana pipiens</i>	North America	Granoff et al. (1965)
Sheatfish iridovirus (ESV)	<i>Silurus glanis</i>	Europe (Germany)	Ahne et al. (1989)
Epizootic haematopoietic necrosis virus (EHNV)	<i>Perca fluviatilis</i> ; <i>Oncorhynchus mykiss</i>	Australia	Langdon et al. (1986)
Guppyfish ranavirus (GV6)	<i>Poecilia reticulata</i>	South-East Asia	Hedrick and McDowell (1995)
Venezuelan ranavirus (GV)	<i>Bufo marinus</i>	South America (Venezuela)	Zuppanovich et al. (1998)
<i>Rana temporaria</i> United Kingdom ranavirus 1 (RUK11)	<i>Rana temporaria</i>	Europe (United Kingdom)	Hyatt et al. (2000)
<i>Bufo bufo</i> United Kingdom ranavirus 1 (BUK2)	<i>Bufo bufo</i>	Europe (United Kingdom)	Hyatt et al. (2000)

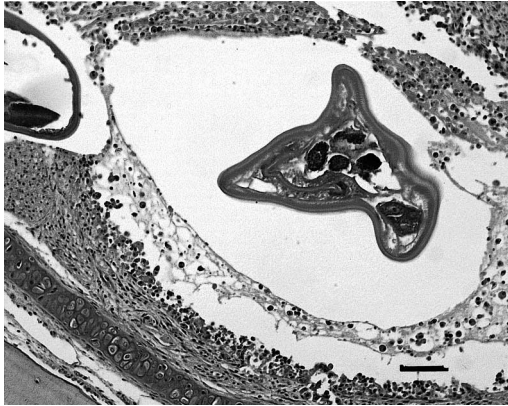

FIGURE 1. Severe ulcerative rhinitis and cross-section of nasal nematode in juvenile green python infected with novel ranavirus. HE. Bar = 50 μ m.

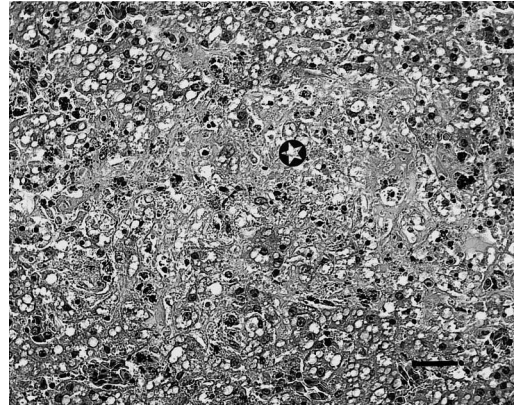


FIGURE 2. Focal hepatic necrosis (*) in juvenile green python infected with novel ranavirus. HE. Bar = 33 μ m.

Felsenstein (1989). Initial nucleotide and amino acid sequence comparisons were done using EMBL FASTA and BLITZ alignment programs (National Center for Biotechnology Information, <http://www.ncbi.nlm.nih.gov/>). Each PCR product was sequenced twice. This sequence was re-confirmed by sequence analysis of another independent PCR amplification (Gould et al., 1995). The amino acid sequence of the MCP of isolate 980804 was deduced and aligned with those of BIV, FV3 and EHNV.

RESULTS

Postmortem examination

At postmortem examination snakes 1, 2, and 3 were in poor body condition based on the presence of minimal internal fat deposits. They had deep erosive lesions throughout the buccal mucosa filled with purulent material including areas of caseation. In snake 3 (980958) there was extension of the erosive process into the right mandible. The remaining seven snakes were longer and thicker than snakes 1, 2, and 3 and had substantial internal fat deposits. No gross abnormalities were detected in these animals.

Histopathology

On histologic examination, snake 1 had moderately severe chronic ulcerative rhinitis with necrotizing inflammation extending into the submucosa (Fig. 1). Macrophages were prominent within the inflam-

matory infiltrate. Nematodes were observed in the lumen of the nasal cavity together with a macrophage and proteinaceous exudate. The nematodes were visualized as mid-body sections only and could not be identified further. The oral mucosa was eroded and ulcerated without significant inflammatory infiltrate. Also noted was severe diffuse periacinar necrosis of the liver with cytoplasmic vacuolation of remaining hepatocytes. There was thickening of the pulmonary alveolar walls, with swelling of the epithelial lining of alveoli and increased numbers of free alveolar macrophages. Cellular debris and fibrin were evident within many blood vessels of the heart and lung together with numerous intravascular macrophages in the pulmonary vasculature. Additionally, mononuclear cuffing in the submucosal blood vessels of the stomach was found. There was focal peracute tubular necrosis in the kidney and a myocardial infarction. Two species of nematode parasite, subsequently identified as *Kalicephalus* sp. and *Abbreviata* sp. (I. Beveridge, pers. comm.) were recognized in the stomach and intestinal contents.

In snake 2 a similar but less severe lesion was present in the liver comprising occasional focal areas of hepatocyte necrosis (Fig. 2). There was also severe necrotizing inflammation of the connective tis-

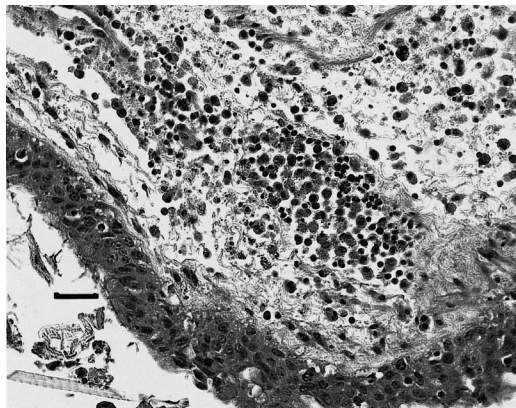


FIGURE 3. Pharyngeal inflammation in juvenile green python infected with novel ranavirus. Note submucosal infiltration by mixed inflammatory cells and submucosal edema. HE. Bar = 50 μ m.

sue surrounding the pharynx, trachea, and thyroid gland characterized by numerous macrophages, heterophils, and edema (Fig. 3). Diffuse acute necrosis of the spleen with deposition of fibrin and obliteration of the normal splenic architecture was observed. Nematodes were also identified in the nasal cavity together with *Abbreviata* sp. (I. Beveridge, pers. comm.) in the intestinal contents.

Tissue samples from snake 3 were autolytic and not suitable for histologic or immunohistochemical examination. No histologic lesions were found in tissues from the seven snakes that were euthanized including the snake that appeared to recover from an illness.

Immunohistochemistry

In snakes 1 and 2 specific immunostaining for ranaviruses was identified in endothelial cells of arteries and veins as well as connective tissue cells in many organs (Fig. 4). Furthermore, there was immunostaining of hepatic sinusoidal lining cells and hepatocytes. There was also positive immunostaining of leucocytes and dendritic cells of the spleen. In the kidney, immunostaining was observed in numerous glomeruli and in the endothelium of longitudinal interstitial capillaries of the renal medulla. Diffuse immunostaining

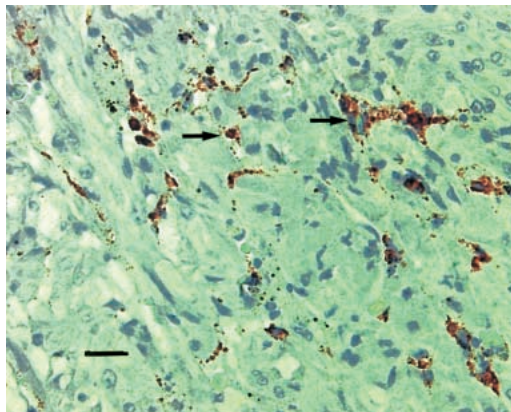


FIGURE 4. An indirect immunoperoxidase (rabbit anti-EHNV and immunoperoxidase) test for EHN virus with positive immunostaining of vascular endothelium (arrows) in myocardium of juvenile green python infected with novel ranavirus. Bar = 33 μ m.

was found in the nasal epithelium and nasal exudate as well as focal immunostaining of the skin and oral mucosa (Fig. 5). Staining was also evident in osteoblasts, but not osteoclasts, of the nasal bones. Specific immunostaining for ranaviruses was not identified in any tissues of snakes that were euthanized including the recovered snake.

Bacteriology

Moderate numbers of *Streptomyces* sp. and *Flavobacterium* sp. were isolated from

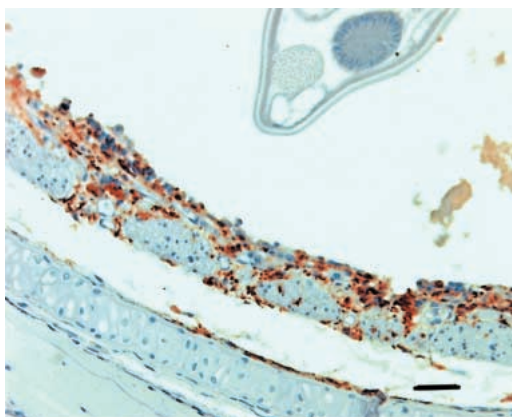


FIGURE 5. An indirect immunoperoxidase test (rabbit anti-EHNV and immunoperoxidase) with positive immunostaining of muscle, inflammatory cells, and residual epithelium in inflamed nasal cavity of juvenile green python infected with novel ranavirus. Note also intranasal nematode. Bar = 50 μ m.

TABLE 3. Cell survival and infectivity at various temperatures of novel ranavirus isolate 980804.

Cells and the temperatures at which they were grown prior to infection	Temperature at which virus was grown (C) ^a					
	10	15	22	30	37	40
Vero (37 C)	–	+/-	+	+	+	+
Virus replication ^b	0	3.05	2.55	6.05	0	0
VH2 (30 C)	–	–	–	+	+	–
Virus repliation	N	N	N	Y	N	N
GL-1 (30 C)	–	–	+	+	+/-	–
Virus replication	N	N	Y	Y	N	N
FHM (22 C)	+	+	+	+/-	–	–
Virus replication	N	Y	Y	Y	N	N
CHSE (15 C)	+	+	+	–	–	–
Virus replication	N	Y	Y	N	N	N

^a Cells grow to confluency (+); cells do not grow to confluency and show signs of stress (+/-); cells do not grow (–).

^b Virus replication (Y = yes, N = no). Titers are expressed as log₁₀ tissue culture infectious doses per ml (TCID₅₀/ml).

the mouth of snake 2 at RT and at 37 C. Small numbers of *Staphylococcus* sp. were isolated from the mouth of snake 3. These isolations were of uncertain diagnostic significance. *Salmonella* spp. were not isolated from the tissues of snakes 1, 2, or 3.

Virus isolation

On first passage, CPE was observed in all cell lines inoculated with tissue homogenates from snake 1 and snake 2. Cytopathic effects were observed at day 2 pi in CHSE and VH2 cells and subsequently developed in the other cells on days 3 and 4 pi. The CPE was most distinct in VH2 and Vero cells and least apparent in BF-2 cells. On second passage, CPE developed on days 2 or 3 pi in all cell lines except BF-2, suggesting that the virus does not adapt well to growth in BF-2 cells. No

CPE was observed in cells inoculated with tissue homogenates from the other snakes. Isolate 980804 replicated in various cell lines incubated at temperatures from 10–30 C (Table 3). The titer of virus from Vero cells incubated from 10–40 C, peaked at 30 C (Table 3).

Antigen capture ELISA

Optical densities on the antigen capture ELISA (Table 4) using viruses from snake 1 and snake 2 were above the positive cut-off level (EHNV standard, 1:500) that gives a sensitivity of 59.9% and a specificity of 99.5%. This indicates that there is antigenic cross-reactivity between EHNV and the green python iridovirus isolates.

Electron microscopy

Enveloped viruses were observed within the supernatant of cell cultures infected with tissue homogenates from snake 1 and 2. The viruses were of complex symmetry depicting a fold or ridge on the surface (Fig. 6). The diameter of the viruses was determined by examination of viruses within ultrathin sections of infected cell cultures and liver tissue from snake 1.

In the liver, icosahedral viruses (143 ± 4 nm, n = 11) and aberrant forms thereof (91 ± 13 nm, n = 4) were identified in necrotic and autolytic cells; these cells were usually in close proximity to red

TABLE 4. Results of the EHNV-antigen capture ELISA using novel ranaviruses isolated from two green pythons. The data are expressed as optical densities (OD). The ODs from the blank wells (no antigen added) have been subtracted. The values represent mean values (n = 4).

Virus	Dilution			
	0	1:10	1:100	1:500
Isolate 980804	1.87	1.40	1.61	NA ^a
Isolate 980814	1.68	1.24	0.97	NA ^a
EHNV (Standard)	1.85	1.52	0.45	0.14

^a NA = Sample not analyzed at this dilution.

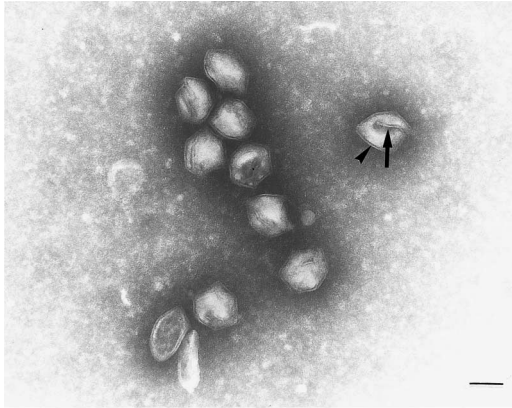


FIGURE 6. Transmission electron micrograph of viruses. Large arrow indicates the "crease" associated with the virus; small arrow, nucleocapsid. Phosphotungstic acid. Bar = 100 nm.

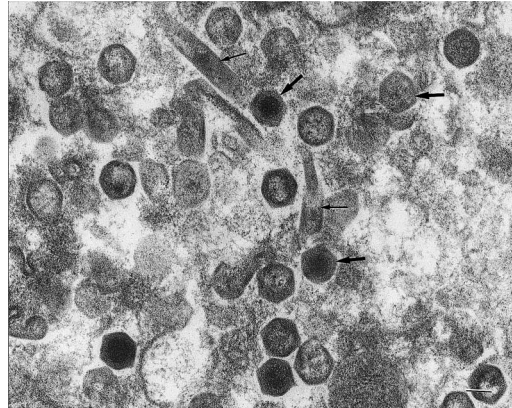


FIGURE 8. Transmission electron micrograph of a section from the affected liver of snake 1. Viral particles (large arrows) and aberrant forms of the virus (thin arrow). Bar = 100 nm.

blood cells. The identity of the infected cells could not be determined. The viruses were observed in various forms of assembly which included complete capsids (containing electron dense forms), incomplete capsids, and capsids associated with electron dense material (Figs. 7, 8). Infected Vero cells also contained intracellular arrays of icosahedral viruses. Viruses within these arrays were measured as 13 ± 4 nm ($n = 24$) (isolate 980804) and 142 ± 4 nm ($n = 24$) (isolate 980914) in diameter. In both host liver cells and cultured cells, viruses were also observed within rarefied

areas of the cytoplasm (virus-inclusion bodies) and budding from the plasma membrane, from which they obtained an outer membrane (Fig. 9). Within these inclusion bodies, viruses were observed in

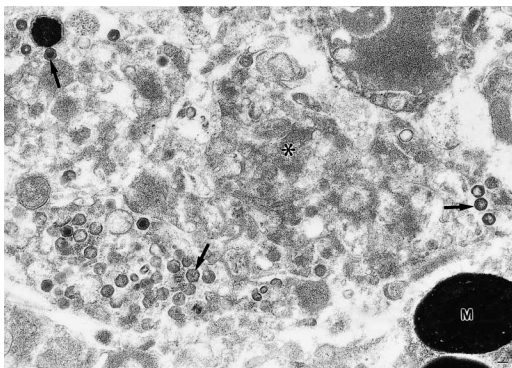


FIGURE 7. Transmission electron micrograph of a section from the affected liver of snake 1. Viruses (arrows) can be observed within the cell debris (*). M, melanin granule. Uranyl acetate and lead citrate. Bar = 100 nm.

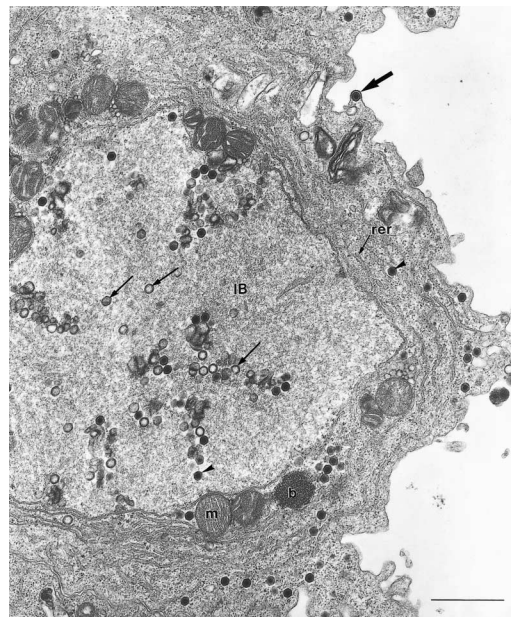


FIGURE 9. Low magnification of FHM cells infected with isolate 980804. Complete (arrow heads) and incomplete nucleocapsids (thin arrows) can be observed within the rarefied areas (inclusion bodies) of the cytoplasm (IB). Large arrow, budding virus; arrowhead, virus; m, mitochondrion; rer, rough endoplasmic reticula. Bar = 2 μ m.

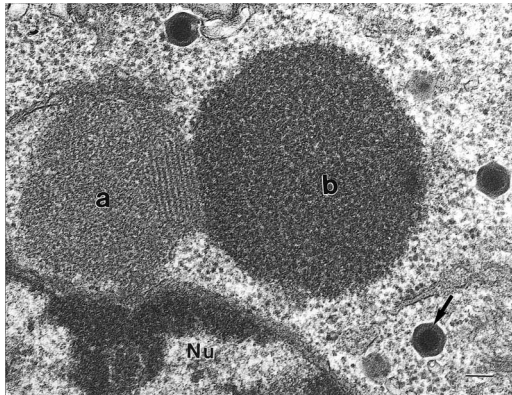


FIGURE 10. Inclusion bodies showing the presence of different phases. Electron lucent (a) and electron dense areas (b) of the inclusion bodies are indicated. Nu, Nucleus; arrow, virus. Uranyl acetate and lead citrate. Bar = 100 nm.

different stages of assembly. An ultrastructural characteristic of the infected tissue culture cells only was the presence of electron dense inclusion bodies. These bodies were frequently bi- or tri-lobed with some lobes being comparatively electron translucent (Fig. 10). No viruses were observed in the nuclei of either cultured or host cells. Immunoelectron microscopy performed on viruses isolated from snake 1 and snake 2 were positively labeled (Fig. 11).

Sodium dodecyl sulphate -poly acrylamide gel electrophoresis (SDS-PAGE)

Radiolabeled proteins from cells infected with isolate 980804 and reference ranaviruses (Table 2) are shown in Figure 12. The first two lanes and lane 5 represent markers and polypeptide profiles from uninfected Vero cells and uninfected CHSE cells respectively. Virus-infected cells possessed a minimum of 20 distinguishable polypeptides ranging from approximately 8 kDa to >120 kDa. All profiles possessed a major 49 kDa polypeptide (major capsid protein) with the exception of EHNV where this polypeptide is approximately 50–51 kDa. The polypeptides of isolate 980804 (infected cells) ranged from approximately eight kDa to greater than 121 kDa. Examination of the profiles indicated

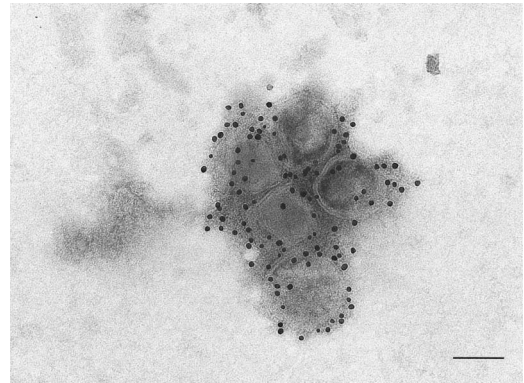


FIGURE 11. Transmission electron micrograph of viruses incubated with antibodies against EHNV and 10 nm protein A gold. Phosphotungstic acid. Bar = 100 nm.

that no specific signature polypeptides exist for isolate 980804. The overall profile of the isolate was similar to the others shown in Figure 12. Whilst there were similarities between the profiles, minor differences could be seen between most isolates.

Restriction endonuclease profiles and hybridization analyses

DNA extracted from isolate 980804 was digested with *MspI* but not *HpaII*. The

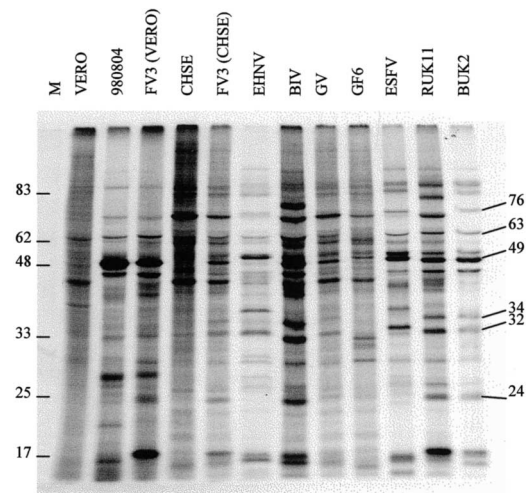


FIGURE 12. Protein synthesis in iridovirus-infected cells. The radiolabelled proteins (^{35}S -methionine) were separated on a 12% SDS-polyacrylamide gel and exposed to autoradiography film. Time post-infection was 36 h. Molecular weight markers (M) and major proteins are indicated (kDa).

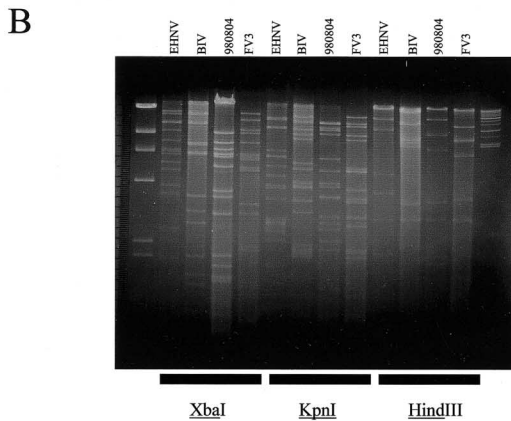
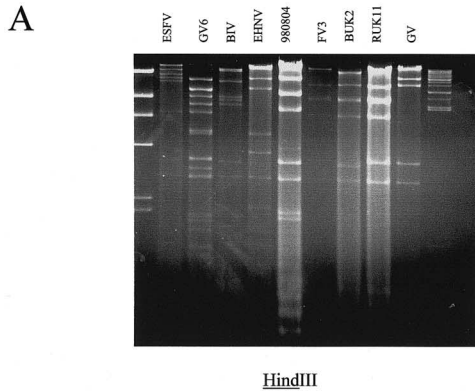


FIGURE 13. Restriction endonuclease digestion profiles. (A) Digestion with *HindIII*. (B) Digestion with *XbaI*, *KpnI* and *HindIII*. Markers were phage λ DNA digested with *HindIII* (23.1, 9.42, 6.68, 4.36, 2.32, and 2.03 kb) and λ high molecular-weight markers (48.5, 38.4, 33.5, 29.9, 24.8, 22.6, 19.4, 17.1, 15.0, 12.2, 10.1, 8.6, and 8.3 kb). Digested DNA was separated on a 0.7% agarose gel and visualized by staining with ethidium bromide.

enzymes identify the sequence CCGG but only *MspI* can cleave this sequence when the internal cytosine is methylated. This indicated that DNA from isolate 980804 was methylated (data not shown). Figure 13A and B show *HindIII* digested DNA from a number of virus isolates. The profile derived for isolate 980804 appeared more similar to that of FV3 (and BUK2 and RUK11) than to any of the other isolates tested, including the two Australian isolates EHNV and BIV. Further digests for comparison of isolate 980804 with

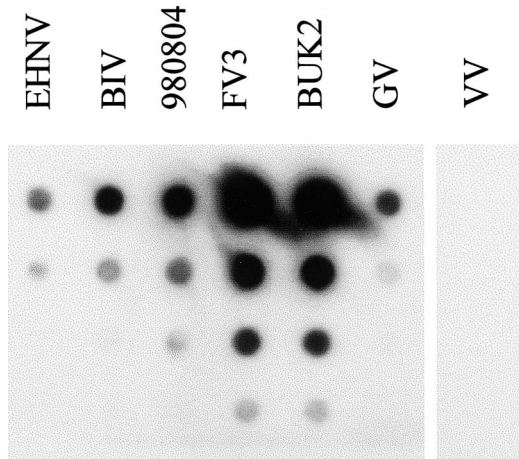


FIGURE 14. Four-fold dilutions of DNA (initial amount added approximately 0.5 μ g) from virus isolates hybridized with 32 P-labelled DNA from FV3. DNA from vaccinia virus (VV) was used as a negative control.

FV3, EHNV, and BIV are shown in Figure 13B where *KpnI* and *XbaI* have been used. These data show that the restriction endonuclease profiles for all four viruses (isolate 980804, FV3, EHNV, and BIV) could be readily distinguished. When DNA prepared from isolate 980814 was compared with that from isolate 980804, the restriction fragment profiles for a range of enzymes were indistinguishable (data not shown).

Results of DNA hybridization using labelled FV3 DNA are shown in Figure 14 and, with the exception of the negative control DNA, all hybridized with labeled FV3 DNA, indicating a high level of sequence homology with FV3. EHNV and 980804 probes gave similar results (data not shown).

Phylogenetic and sequence analyses

Comparison of the 586 nucleotide sequence covering the C-terminus of the coat protein (isolate 980804) and the following non-coding region of the genomic DNA showed that at the nucleotide or amino acid level, isolate 980804 was 97% or 98% homologous (respectively) to FV3. However, the deduced nucleotide se-

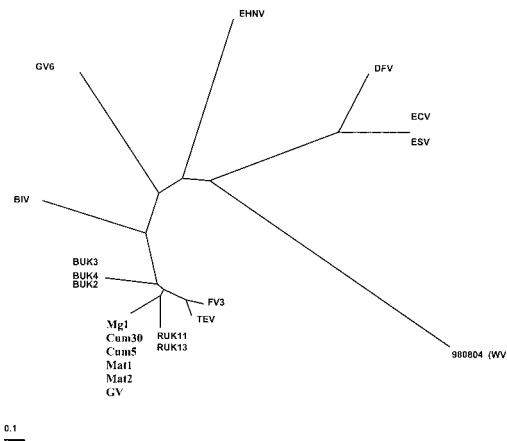


FIGURE 15. Phylogenetic comparison of ranavirus genome sequences. The 586 nucleotides encode the 158 carboxy-termini of iridovirus coat proteins as well as the following 3'-terminal 111 non-coding nucleotides. The scale indicates percent nucleotide differences. Details of the viruses where abbreviations are given can be found in Hyatt et al. (2000).

quence was unique among the ranaviruses sequenced in this laboratory as shown by phylogenetic analyses (Fig. 15). The sequence of the entire major coat protein of isolate 980804 showed that this isolate was 98% homologous with EHNV and BIV and 97% homologous with FV3, at the nucleotide level. At the deduced amino acid level, the homology with EHNV, BIV, and FV3 was 98% (Fig. 16). This represented a total of 10 amino acid changes, four of which are common to BIV and EHNV, and six that are unique to isolate 980804.

DISCUSSION

Of 10 green pythons seized at Cairns International Airport, at least two of the three that subsequently died naturally were infected with a virus that belonged to the family *Iridoviridae* and genus *Ranavirus*. Identity of the virus was confirmed by histopathology, ELISA, immunoelectron microscopy, SDS-PAGE, and restriction endonuclease and hybridization assays. The designation of the virus as a new ranavirus was based upon restriction endonuclease digestion profiles, coat protein sequence, and sequence studies which revealed the isolate to be unique. Compari-

FV3	(1)	MSSVTGSGITSGFDLATYDNLERAMYGGSDATTYFVKEHYVPGWFTKLP
EHNV	(1)	. . P
BIV	(1)
980804	(9)
FV3	(51)	SLAARKMSGNFAFGQQFVSGVFRSGDYILNANLVLKTPVEVLLAANQLGDN
EHNV	(51)
BIV	(51)
980804	(59)
FV3	(101)	GTIRWTKRPMHNIVESVTLSPNDLSAQSFNTAYLDANSEYTMPEAKRTQY
EHNV	(101)
BIV	(101)
980804	(109)
FV3	(151)	YNMIGNTSDLINEFAPATGQD GARVLPKNI VLPLPFPFSDRSLGLALPVVS
EHNV	(151)
BIV	(151)
980804	(159)
FV3	(201)	LPYNEIRITVKLRAIHDLILQHTTGAISPIVASDLAGLDPDTEAVNY
EHNV	(201)
BIV	(201)
980804	(209)
FV3	(251)	MTVALITGDERQAMSSVTRKMMVVEQVQAAPVHMVNPARNATTFTDMRFSH
EHNV	(251)
BIV	(251)
980804	(259)
FV3	(301)	AVKALMPYQNVTHPSVGSNYTCVTPVVGNTVLEPALAVDPVKSASLV
EHNV	(301)
BIV	(301)
980804	(309)
FV3	(351)	YENTTRLPDMGVYYSVLEPHYYATSTPVSTGHHLVSYALSLQDPHPSGS
EHNV	(351)
BIV	(351)
980804	(359)
FV3	(401)	TNYRLTNASLVNLTSAEATTAAGGGNNSGYTTAQRKYLVLAINHNI
EHNV	(401)
BIV	(401)
980804	(409)
FV3	(451)	IRIMNGSMGFPIL
EHNV	(451)
BIV	(451)
980804	(459)

FIGURE 16. Deduced amino acid sequence for the major capsid protein of isolate 980804 is compared with that deduced for FV3, EHNV, and BIV. Sequences were aligned with that deduced for FV3 and identical amino acids are indicated by a (.) while differences are given below the respective FV3 amino acid. Amino acid positions are indicated to the left of the figure in brackets.

sons were based on ranaviruses held within the reference collection at the AAHL. The virus is provisionally named Wamena virus (WV) after the geographic location in Irian Jaya where the snakes were collected.

Positive immunostaining of tissues including liver, kidney, spleen, stomach, small intestine, skin, bone, and nasal and oral epithelium in two of three ill snakes indicated the tissues were infected with a ranavirus. The systemic viscerotropic distribution of infection is similar to fish infected with EHNV (Reddacliff and Whittington, 1996). The infection differed from those described by Cunningham et al (1996), Jancovich et al. (1997), and Bollinger et al. (1999) in that there were no major skin lesions or megalocytosis. Upon ultrastructural examination of one of the in-

ected livers, a range of capsids and putative viral nucleic acid were observed indicating the presence of viral replication. The viruses were smaller than those previously described (Hyatt et al., 2000) and contained unique viral inclusion bodies; the significance of these differences is not known. While transmission studies could not be performed and therefore Koch's postulates could not be fulfilled, the collective clinical, histopathologic, immunohistochemical, and electron microscopic data indicated that the death of at least two of the animals was attributable to ranavirus infection.

Wamena virus appears to be different from other ranaviruses so far described in terms of ultrastructure, genome sequence, and restriction fragment profiles. The growth characteristics were unremarkable in that they did not differ from those reported for GV (Zupanovic et al., 1998) or FV3 (Gravell and Granoff, 1970), having optimum replication temperatures between 24 C and 30 C and no replication above 32 C. The optimum growth temperature differed from that of *Ambystoma tigrinum* virus (ATV) which causes disease and death in salamanders (Jancovich et al., 1997) and which replicates at lower temperatures (19–23 C) and not above 26 C.

The unique restriction fragment patterns also indicated that WV is a newly identified ranavirus, as these differed from those of other ranaviruses (FV3, BIV, and EHNV). Similar analyses performed on isolates of SBV (isolated from a stickleback, *Gasterostelus aculeatus*), TV2 (isolated from a red-legged frog, *Rana aurora*), 276 (isolated from *R. aurora*), TV3 (isolated from a box turtle, *Terrapene carolina carolina*), TV5 (isolated from a tortoise, *Testudo horsfieldi*), and FV3 found that SBV, 276, and TV2 are identical by restriction endonuclease digestion and that SBV, TV2, and FV3 are identical by nucleotide sequence (Mao et al., 1999). In addition, Mao et al. (1997) showed that TV3 and 276 have 100% identity and homology with FV3. Because these viruses were

characterized with a different set of primers than those described in this paper it is not possible to make specific comment on the degree of relatedness of WV to the North American turtle and tortoise isolates. However based on the restriction fragment length profiles and nucleotide comparisons of WV and FV3, the differences suggest that WV is different from the reptilian ranaviruses (TV3 and TV5) described by Mao et al. (1997, 1999).

The known pathogenicity of ranavirus infections in fish (e.g., Langdon et al., 1986), anurans (e.g., Drury et al., 1995; Cunningham et al., 1996; Zupanovich et al., 1998), salamanders (Jancovich et al., 1997), turtles and tortoises (Mao et al., 1997), and snakes indicates that members of this genus pose a threat to the health of piscine and herpetofauna (Daszak et al., 1999). Recently, Mao et al. (1999) isolated identical ranaviruses from a wild three-spine stickleback and a sympatric red-legged frog, indicating natural infection of animals from different taxonomic classes. Transmission trials have not yet been possible with WV, however, in the absence of negative data, we suggest that it is prudent to assume that WV may have the potential to infect and kill Australian herpetofauna and fish.

Illegal trade in wildlife can be a mechanism of pathogen translocation that can threaten the health and welfare of species endemic to the country of importation. Adequate quarantine and support services are required if the threats of such "pathogen pollution" (Daszak et al., 2000) are to be minimized. The case study described in this paper presents, for the first time, the identification, isolation, and characterization of a ranavirus from snakes and illustrates the importance of vigilant quarantine services at international borders. Such services may reduce the risk of introduction of exotic pathogens and, in turn, facilitate the protection of a country's biodiversity.

ACKNOWLEDGEMENTS

We wish to thank R. Amos, S. Daglas, and T. Taylor for their technical assistance.

LITERATURE CITED

- AHNE, W. H. J., H. J. SCHLOTTFELDT, AND I. THOMSEN. 1989. Fish viruses: Isolation of an icosahedral cytoplasmic deoxyribovirus from sheatfish (*Silurus glanis*). *Journal of Veterinary Medicine B* 36: 333–336.
- ANDERSON, I. G., H. C. PRIOR, B. J. RODWELL, AND G. O. HARRIS. 1993. Iridovirus-like virions in imported dwarf gourami (*Colisa lalia*) with systemic amoebiasis *Australian Veterinary Journal* 70: 66–67.
- ASHBURNER, L. D. 1975. Lymphocystis in paradise fish (*Macropodus opercularis*) in Australia. *Australian Veterinary Journal* 51: 448–449.
- BOLLINGER, T. K., J. MAO, D. SCHOCK, M. BRIGHAM, AND V. G. CHINCHAR. 1999. Pathology, isolation, and preliminary molecular characterization of a novel iridovirus from tiger salamanders in Saskatchewan. *Journal of Wildlife Diseases* 35: 413–429.
- COUPAR, B. E. H., T. TEO, AND D. B. BOYLE. 1990. Restriction endonuclease mapping of the fowlpox virus genome. *Virology* 179: 159–167.
- CULLEN, B. R., L. OWENS, AND R. J. WHITTINGTON. 1995. Experimental infection of the Australian anurans (*Limnodynastes terrareginae* and *Litoria latopalmata*) with Bohle iridovirus. *Diseases of Aquatic Organisms* 23: 83–92.
- CUNNINGHAM, A. A., T. E. LANGTON, P. M. BENNETT, J. F. LEWIN, S. E. DRURY, R. E. GOUGH, AND S. K. MACGREGOR. 1996. Pathological and microbiological findings from incidents of unusual mortality of the common frog (*Rana temporaria*). *Philosophical Transactions of the Royal Society of London B Biological Sciences* 351: 1539–1557.
- DALY, J. J., M. MAYHUE, J. H. MENNA, AND C. H. CALHOUN. 1980. Viruslike particles associated with *Pirhemocytion* inclusion bodies in the erythrocytes of a water snake, *Nerodia erythrogaster flavigaster*. *The Journal of Parasitology* 66: 82–87.
- DASZAK, P., L. BERGER, A. A. CUNNINGHAM, A. D. HYATT, D. E. GREEN, AND R. SPEARE. 1999. Emerging infectious diseases and amphibian population declines. *Emerging Infectious Diseases* 5: 735–748.
- , A. A. CUNNINGHAM, AND A. D. HYATT. 2000. Emerging infectious diseases of wildlife—Threats to biodiversity and human health. *Science* 287: 443–449.
- DRURY, S. E. N., R. E. GOUGH, AND A. A. CUNNINGHAM. 1995. Isolation an iridovirus-like agent from common frogs (*Rana temporaria*). *The Veterinary Record* 137: 72–73.
- DURHAM, P. J. K., M. J. ALLANSON, AND W. G. HUTCHINSON. 1996. Lymphocystis disease in snapper (*Pagrus auratus*) from Spencer Gulf, South Australia. *Australian Veterinary Journal* 74: 312–313.
- FELSENSTEIN, J. 1989. Phylogenies from molecular sequences: Inference and reliability. *Annual Review of Genetics* 22: 521–565.
- FRASER, W. A., T. J. KEEFE, AND B. BOLON. 1993. Isolation of an iridovirus from farm raised gouramis (*Trichogaster trichopterus*) with fatal disease. *Journal of Veterinary Diagnostic Investigation* 5: 250–253.
- GOULD, A. R., A. D. HYATT, S. H. HENGSTBERGER, R. J. WHITTINGTON, AND B. E. H. COUPAR. 1995. A polymerase chain reaction (PCR) to detect epizootic haematopoietic necrosis virus and Bohle iridovirus. *Diseases of Aquatic Organisms* 22: 211–215.
- GRANOFF, A., P. E. CAME, AND K. RAFFERTY. 1965. The isolation and properties of viruses from *Rana pipiens*: Their possible relationship to the renal adenocarcinoma of the leopard frog. *Annals of the New York Academy of Sciences* 126: 237–255.
- GRAVELL, M., AND A. GRANOFF. 1970. Viruses and renal adenocarcinoma of *Rana Pipiens*. IX. The influence of temperature and host cell on replication of frog polyhedral cytoplasmic deoxyribovirus (PLDV). *Virology* 41: 596–602.
- HEDRICK, R. P., AND T. S. MCDOWELL. 1995. Properties of iridoviruses from ornamental fish. *Veterinary Research* 26: 423–427.
- HENGSTBERGER, S. G., A. D. HYATT, R. SPEARE, AND B. E. H. COUPAR. 1993. Comparison of epizootic haematopoietic necrosis and Bohle iridoviruses, recently isolated Australian iridoviruses. *Diseases of Aquatic Organisms* 15: 93–107.
- HYATT, A. D. 1992. Immunogold labelling techniques. *In* *Electron microscopy of tissues, cells, and organelles*, J. R. Harris (ed.). Oxford University Press, Oxford, UK, pp. 59–80.
- . 1998. Identification, characterisation and assessment of Venezuelan viruses for potential use as biological control agents against the cane toad (*Bufo marinus*) in Australia. A report to the Federal Government. (Environment Australia and Division of Wildlife & Ecology).
- , AND P. W. SELLECK. 1996. Ultrastructure of equine morbillivirus. *Virus Research* 43: 1–15.
- , B.T. EATON, S. HENGSTBERGER, AND G. RUSSELL. 1991. Epizootic haematopoietic virus: Detection by ELISA, immunohistochemistry and immunoelectron-microscopy. *Journal of Fish Diseases* 14: 605–617.
- , A. R. GOULD, Z. ZUPANOVIC, A. A. CUNNINGHAM, S. HENGSTBERGER, R. J. WHITTINGTON, J. KATTENBELT, AND B. E. H. COUPAR. 2000. Comparative studies of piscine and amphibian iridoviruses. *Archives of Virology* 145: 301–331.
- JANCOVICH, J. K., E. W. DAVIDSON, J. F. MORADO, B. L. JACOBS, AND J. P. COLLINS. 1997. Isolation of lethal virus from the endangered salamander

- Ambystoma tigrinum stebbinsi*. Diseases of Aquatic Organisms 31: 161–167.
- JOHNSRUDE, J. D., R. E. RASKIN, A. Y. A. HOGE, AND G. W. ERDOS. 1997. Intraerythrocytic inclusions associated with iridoviral infection in a Fer de Lance (*Bothrops moojeni*) snake. Veterinary Pathology 34: 235–238.
- LANGDON, J. S., J. D. HUMPHREY, L. M. WILLIAMS, A. D. HYATT, AND H. A. WESTBURY. 1986. First virus isolation from Australian fish: An iridovirus-like pathogen from redbfin perch, *Perca fluviatilis* L. Journal of Fish Diseases 9: 263–268.
- MAO, J., R. P. HEDRICK, AND V. G. CHINCHAR. 1997. Molecular characterization, sequence analysis, and taxonomic position of newly isolated fish iridoviruses. Virology 229: 212–220.
- , D. E. GREEN, G. FELLERS, AND V. G. CHINCHAR. 1999. Molecular characterization of iridoviruses isolated from sympatric amphibians and fish. Virus Research 63: 45–52.
- MARQUARDT, W. C., AND R. G. YAEGER. 1967. Structure and taxonomic status of *Toddia* from the cottonmouth snake *Agkistrodon piscivorus leucostoma*. Journal of Protozoology 14: 726–731.
- MOODY, N. J. G., AND L. OWENS. 1994. Experimental demonstration of the pathogenicity of a frog virus, Bohle iridovirus, for a fish species, barramundi *Lates calcarifer*. Diseases of Aquatic Organisms 18: 265–102.
- OFFICE INTERNATIONAL DES EPIZOOTIES. 2000. Epizootic haematopoietic necrosis virus. In Office of International Epizootics diagnostic manual for aquatic animal diseases, Paris, France, pp. 17–25.
- PEARCE, M., J. D. HUMPHREY, A. D. HYATT, AND L. M. WILLIAMS. 1990. Lymphocystis disease in captive barramundi *Lates calcarifer*. Australian Veterinary Journal 67: 144–145.
- REDDACLIFF, L. A., AND R. J. WHITTINGTON. 1996. Pathology of epizootic haematopoietic necrosis virus (EHNV) infection in rainbow trout (*Oncorhynchus mykiss* Walbaum) and redbfin perch (*Perca fluviatilis* L.). Journal of Comparative Pathology 115: 103–115.
- SCHMIDT, N. J. 1979. Cell culture techniques for diagnostic virology. In Diagnostic procedures for viral, rickettsial and chlamydial infections, 5th Edition, E. H. Lennette and N. J. Schmidt (eds.). American Public Health Association, Washington D.C., pp. 65–139.
- SMITH, T. G., S. S. DESSER, AND H. HONG. 1994. Morphology, ultrastructure, and taxonomic status of *Toddia* sp. in northern water snakes (*Nerodia sipedon*) from Ontario, Canada. Journal of Wildlife Diseases 30: 169–175.
- SPEARE, R., AND J. R. SMITH. 1992. An iridovirus-like agent isolated from the ornate burrowing frog *Limnodynastes ornatus* in northern Australia. Diseases of Aquatic Organisms 14: 51–57.
- VAN REGENMORTEL, M. H. V., C. M. FAUQUET, D. H. L. BISHOP, E. B. CARSTENS, M. K. ESTES, S. M. LEMON, J. MANILOFF, M. A. MAYO, D. J. MCGEOCH, C. R. PRINGLE, AND R. B. WICKNER. 2000. Family *Iridoviridae*. In Virus taxonomy, Seventh report of the international committee on taxonomy of viruses, M. H. V. van Regenmortel, C. M. Fauquet, D. H. L. Bishop, E. B. Carstens, M. K. Estes, S. M. Lemon, J. Maniloff, M. A. Mayo, D. J. McGeoch, C. R. Pringle, and R. B. Wickner (eds.). Academic Press, San Diego, California, pp. 167–182.
- ZUPANOVIC, Z., C. MUSSO, G. LOPEZ, C. L. LOURIERO, A. D. HYATT, S. HENGSTBERGER, AND A. J. ROBINSON. 1998. Isolation and characterization of iridoviruses from the giant toad *Bufo marinus* in Venezuela. Diseases of Aquatic Organisms 33: 1–9.

Received for publication 25 July 2000.