

## **Sarcocystis Meningoencephalitis in a Northern Gannet (*Morus bassanus*)**

Authors: Spalding, Marilyn G., Yowell, Charles A., Lindsay, David S., Greiner, Ellis C., and Dame, John B.

Source: Journal of Wildlife Diseases, 38(2) : 432-437

Published By: Wildlife Disease Association

URL: <https://doi.org/10.7589/0090-3558-38.2.432>

---

The BioOne Digital Library (<https://bioone.org/>) provides worldwide distribution for more than 580 journals and eBooks from BioOne's community of over 150 nonprofit societies, research institutions, and university presses in the biological, ecological, and environmental sciences. The BioOne Digital Library encompasses the flagship aggregation BioOne Complete (<https://bioone.org/subscribe>), the BioOne Complete Archive (<https://bioone.org/archive>), and the BioOne eBooks program offerings ESA eBook Collection (<https://bioone.org/esa-ebooks>) and CSIRO Publishing BioSelect Collection (<https://bioone.org/csiro-ebooks>).

Your use of this PDF, the BioOne Digital Library, and all posted and associated content indicates your acceptance of BioOne's Terms of Use, available at [www.bioone.org/terms-of-use](http://www.bioone.org/terms-of-use).

Usage of BioOne Digital Library content is strictly limited to personal, educational, and non-commercial use. Commercial inquiries or rights and permissions requests should be directed to the individual publisher as copyright holder.

---

BioOne is an innovative nonprofit that sees sustainable scholarly publishing as an inherently collaborative enterprise connecting authors, nonprofit publishers, academic institutions, research libraries, and research funders in the common goal of maximizing access to critical research.

## ***Sarcocystis* Meningoencephalitis in a Northern Gannet (*Morus bassanus*)**

**Marilyn G. Spalding,<sup>1,3</sup> Charles A. Yowell,<sup>1</sup> David S. Lindsay,<sup>2</sup> Ellis C. Greiner,<sup>1</sup> and John B. Dame<sup>1</sup>**  
<sup>1</sup> Department of Pathobiology, Box 110880, College of Veterinary Medicine, University of Florida, Gainesville, Florida 32611, USA; <sup>2</sup> Center for Molecular Medicine and Infectious Diseases, Department of Biomedical Sciences and Pathobiology, Virginia-Maryland College of Veterinary Medicine, Virginia Tech, 1410 Prices Fork Road, Blacksburg, Virginia 24061, USA; <sup>3</sup> Corresponding author (email: rosie@nersp.nerdc.ufl.edu).

**ABSTRACT:** *Sarcocystis* sp. schizonts were found in the cerebellum of a northern gannet (*Morus bassanus*), exhibiting neurologic signs, found on the Florida (USA) east coast. Based upon molecular characterization of DNA isolated from the brain of the gannet, this *Sarcocystis* sp. appeared to be closely related, if not identical, to an unnamed *Sarcocystis* sp. typified by isolates 1085 and 1086 collected from feces of a Virginia opossum (*Didelphis virginiana*) on the east coast of Florida. Because the life cycle of this parasite appears to be land based, urban waste discharge to marine/estuarine environments may be a source of infection for marine species.

**Key words:** Case report, meningoencephalitis, *Morus bassanus*, northern gannet, *Sarcocystis*.

*Sarcocystis*-induced encephalitis has been reported in a wild turkey (*Meleagris gallopavo*) (Teglas et al., 1998), a golden eagle (*Aquila chrysaetos*) (Dubey et al., 1991), and a northern goshawk (*Accipiter gentilis atricapillus*) (Aguilar et al., 1991). In addition, there have been numerous reports of *Sarcocystis*-induced encephalitis in captive birds, including chickens and psittacines (Jacobson et al., 1984; Hillyer et al., 1991; Mutalib et al., 1995). This is the first report of *Sarcocystis*-associated encephalitis in a sea bird.

On 25 March 1998 an adult female northern gannet (*Morus bassanus*) was found recumbent on St. Augustine Beach (29°51'N, 81°16'W), St. Johns county, on the east coast of Florida (USA). It was taken to the St. John's Veterinary Clinic (St. Augustine). The bird was seizing and exhibiting opisthotonos. Because it was covered with chewing lice (*Neottialges bassani*) it was treated with Ivermectin (200 µg/kg, Merck, Rahway, New Jersey, USA). It died the next day.

The bird was severely emaciated upon gross examination. The brain appeared normal; lungs were edematous. There was a gastric ulcer and intestines contained scant black fluid. Culture of the duodenal contents resulted in heavy growth of *Vibrio alginolyticus* with fewer colonies of non-hemolytic *Streptococcus*, *Klebsiella-Enterobacter* sp., *Staphylococcus* sp., *Corynebacterium* sp., and five other enteric Gram-negative rods.

Sections of most tissues were fixed in 10% neutral buffered formalin, embedded in paraffin, sectioned at 5 µm, and stained with hematoxylin and eosin. A sample from the paraffin block corresponding with a cyst in the heart was processed for electron microscopy. Slides were deposited at the Harold W. Manter Laboratory of Parasitology (Lincoln, Nebraska, USA; Accession number HWML-16477).

Severe hepatic atrophy, myodegeneration of both skeletal and cardiac muscle, and severe interstitial pulmonary edema were noted histologically. Intestinal mucosa was too autolytic to characterize. *Sarcocysts* were scattered widely in heart (one cyst per five 100× fields) (Fig. 1) and striated muscle (eight to ten cysts per 100× field). The sarcocyst wall had long villar protrusions that were visible by light and electron microscopy (Fig. 2). The projections had prominent bundles of intermediate filaments running the length of the villi and extending into the ground substance. On cross section, up to nine of these bundles could be seen. The villar structure was similar to those illustrated in experimentally infected (*S. falcatula*) budgerigars (*Melopsittacus undulates*; Neill et al., 1989), boat-tailed grackles (*Quiscalus*

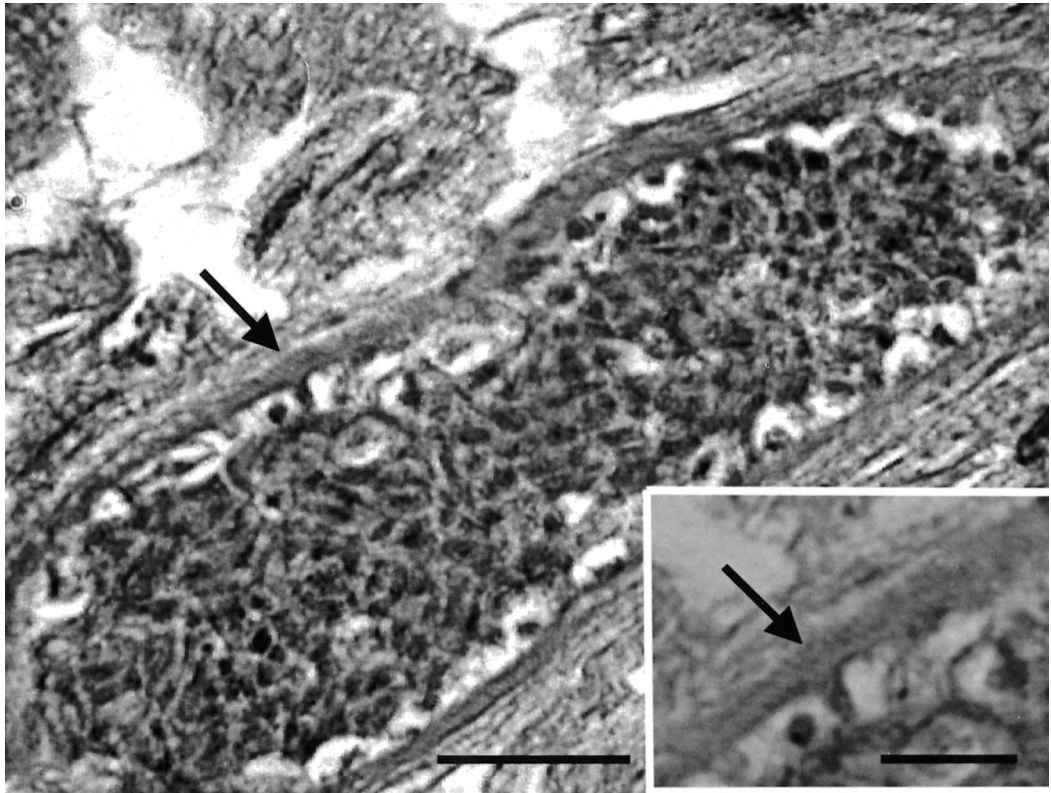


FIGURE 1. Photomicrograph of a sarcocyst in heart muscle of a northern gannet. HE. Bar = 10  $\mu$ m. Inset is a higher magnification of the wall illustrating the villar surface. Bar = 5  $\mu$ m.

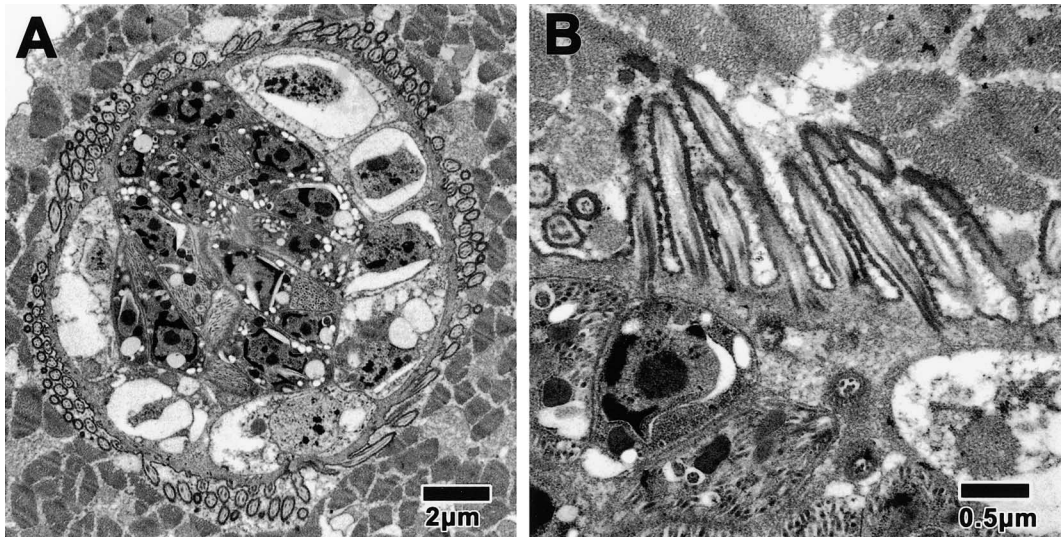


FIGURE 2. Transmission electron micrograph (lead acetate stain) of the cyst wall from the heart of a northern gannet at two powers (A, B). Note both longitudinal and cross sections of the villar projections with hobnail bumps and prominent bundles of intermediate filaments extending into the ground substance.



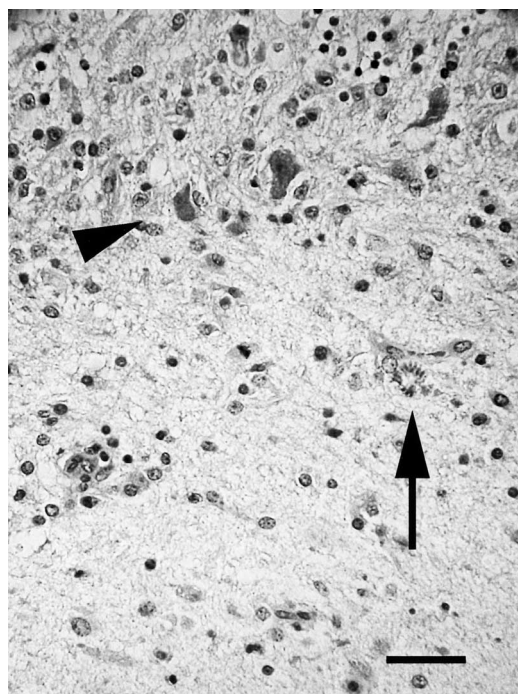


FIGURE 3. Degeneration and loss of Purkinje cell layer (arrowhead), intracellular schizont in rosette formation (arrow), and areas of gliosis in the cerebellum of a northern gannet. HE. Bar = 20  $\mu$ m.

major syn. *Cassidix mexicanus*; Simpson and Forrester, 1973), and brown-headed cowbirds (*Molothrus ater*) from Florida (Dame et al., 1995). They differed from those illustrated from herons and egrets collected in Florida (Spalding et al., 1994), which had broader villi and more diffuse intermediate filaments.

Multifocal to diffuse non-suppurative perivascular cuffing and meningitis was moderate to severe, particularly in the cerebellum. Protozoal schizonts and merozoites were numerous in the gray matter, often associated with necrotic neurons and foci of gliosis. Degenerative Purkinje cells and loss of the Purkinje cell layer in some areas was apparent (Fig. 3). Occasionally, merozoites were within degenerative Purkinje cells. Protozoa were rarely associated with vessels. Thrombi occasionally occluded small vessels both in the gray matter and granular layer of the cerebellum.

Schizonts frequently appeared as intracellular rosettes.

Sections of brain were examined using immunohistochemistry. Rabbit anti-*Toxoplasma gondii* serum (1:500 dilution, a gift from R. A. Cole, National Wildlife Health Research Center, Madison, Wisconsin, USA), rabbit anti-*Neospora caninum* serum (1:250 dilution), and rabbit *Sarcocystis neurona* anti-serum (1:250 dilution) were used as primary antibodies. A section of muscle also was examined using *S. neurona* anti-serum (1:500 dilution, anti *Neospora* and *Sarcocystis* antibodies were gifts from J. P. Dubey, USDA, Beltsville, Maryland, USA). Mouse tissues containing tachyzoites (*T. gondii* or *N. caninum*) or schizonts and merozoites (*S. neurona*) were used as positive controls for immunohistochemical staining. Tissues were deparaffinized and rehydrated in phosphate buffered saline (PBS), endogenous peroxidase was quenched using 3%  $H_2O_2$  in methanol for 30 min, and tissues were blocked in normal goat serum for 20 min and incubated in the appropriate rabbit anti-serum for 30 min. Tissues were washed twice in PBS for 5 min and incubated in peroxidase-labeled goat anti-rabbit serum (1:100 dilution) for 30 min, washed twice in PBS for 5 min, and then incubated in DAB- $H_2O_2$  reagent (Sigma, St. Louis, Missouri, USA) for 4 min. Tissues were washed in water for 5 min, stained with Gill type II hematoxylin, dehydrated, and mounted in Permount (Sigma).

None of the parasites in brain reacted with the anti-sera used in this study. The sarcocysts in muscle did not react with rabbit anti-*S. neurona* serum. Parasites in the positive control tissues reacted positively with their appropriate anti-serum.

Two tissue samples containing lesions were excised from the cerebellum of the northern gannet along with a tissue sample from the cerebellum of a brown pelican (*Pelecanus occidentalis*) as a negative DNA control. DNA was extracted using DNAzol Reagent (Lifetechnologies, Rockville, Mary-

TABLE 1. Restriction endonuclease digestions and resulting fragment sizes (base pairs) used to distinguish PCR products of *Sarcocystis* spp. shed by opossums compared to those in brain of a northern gannet from Florida.

DNA source	PCR primers (product size)					
	25/396 (334)		33/54 (1100)		ITS 1 69/70 (1290)	
	Hind III <sup>a</sup>	Hinf I <sup>a</sup>	Dra I <sup>a</sup>	Hinf I <sup>a</sup>	DraI/PvuII <sup>a</sup>	SpeI/BssHII <sup>a</sup>
<i>Sarcocystis neurona</i>	334	164/108/62	884/216	1100	1290	680/443/167
<i>Sarcocystis falcatula</i>	180/154	170/164	1100	743/355	798/335/157	1290
1085/1086	334	164/108/62	884/216	743/355	1290	680/443/167
Gannet <i>Sarcocystis</i> sp.	334	164/108/62	884/216	743/355	1290	680/443/167

<sup>a</sup> Restriction enzyme.

land) as per protocol. Polymerase chain reaction (PCR) amplification and restriction enzyme digestion were performed as previously described (Tanhauser et al., 1999), using primer pairs JNB 69/JNB 70, JNB 25/JD 396, and JNB 33/JNB 54. Polymerase chain reaction products were sequenced either directly or after cloning into Topo 2.1 PCR cloning vector (Invitrogen, Carlsbad, California, USA) using ABI Big Dye terminator sequencing kit (Applied Biosystems, Foster City, California, USA).

The PCR products were chosen due to their usefulness in distinguishing *S. neurona* from *S. falcatula* (Tanhauser et al., 1999). In Table 1 the results of PCR coupled with diagnostic restriction digests for *S. neurona*, *S. falcatula*, and isolates 1085 and 1086 from a prior study (Tanhauser et al., 1999) are presented with our findings for the northern gannet *Sarcocystis* sp.

The PCR products of 25/396 and 69/70 (ITS-1) from the northern gannet *Sarcocystis* sp. were sequenced and compared to the reported sequence of 25/396 for *S. neurona* (GenBank No. F093158), *S. falcatula* (GenBank No. AF093159), and isolate 1086 (GenBank No. AF323939) and the 69/70 (ITS-1) of *S. neurona*, *S. falcatula*, and isolate 1085 (unpubl. data) (Table 1). The gannet *Sarcocystis* sp. sequence from 25/396 was identical to the 202 bp of reported isolate 1086 sequences versus 97% similar to *S. neurona* and 94% to *S. falcatula*. The 69/70 (ITS-1) sequence of gannet *Sarcocystis* sp. was 99.8% similar

to isolate 1085 versus 98.0% similar to *S. neurona* and 96.7% for *S. falcatula*.

Based on the limited DNA markers used, the species of *Sarcocystis* found in the brain of this northern gannet is either the same species as that typified by isolates 1085 and 1086 from Virginia opossums (*Didelphis virginiana*) or at least more closely related to this isolate than to *S. neurona* or *S. falcatula*. A number of *Sarcocystis* spp. use opossums as a definitive host, including *S. speeri*, *S. falcatula*, and *S. neurona* (Tanhauser et al., 1999; Rosenthal et al., 2001). The intermediate hosts of *S. falcatula* appear to involve a wide variety of birds (Box and Smith, 1982; Box et al., 1984). Markers used in this study to characterize the *Sarcocystis* sp. in the gannet were those described by Tanhauser et al. (1999), who used an isolate of *S. falcatula* derived from sarcocysts in brown-headed cowbirds collected in Marion County, Florida (29°10'N, 82°10'W). In that study a clear distinction was discerned at the molecular level between *S. falcatula* isolates and the species typified by isolates 1085 and 1086. Additional work will be required to evaluate the relative geographic distributions and nature and extent of the biological differences between *S. falcatula* from the cowbird and the species typified by isolates 1085 and 1086, but it appears that both parasites use birds as intermediate hosts and the opossum as a definitive host. The parasite found in the gannet is most similar at the level of the sequence of the 25/379 marker to the species typi-

fied by isolates 1085 and 1086. Of some interest is the fact that a majority of the isolates of this type collected from opossums in Florida, including type isolates 1085 and 1086, were collected in Broward County (26°10'N, 80°10'W) located on the Atlantic coast.

Brain lesions appeared to be severe enough to cause the neurologic signs observed in the gannet. Whether or not that was the initiating cause of the bird's illness, or secondary to other factors, could not be determined. Edema in the lung did not appear to be associated with protozoal organisms, as has been noted with other birds infected with *S. falcatula*. Sarcocysts in skeletal muscle were moderately numerous; however, myodegeneration was not associated with the sarcocysts themselves. Because we did not evaluate muscle cysts using PCR we could not verify that cysts were the same species of *Sarcocysts* as those in the brain. Brain lesions were most severe in the cerebellum, similar to that reported in Pacific harbor seals (*Phoca vitulina richardsi*) (Lapointe et al., 1998). This case is also similar to other cases in seals (Lapointe et al., 1998) and turkeys (Teglas et al., 1998; Dubey et al., 2000), because sarcocysts were also observed in both striated muscle and myocardium. *Sarcocystis falcatula* was ruled out in one of the turkeys without protozoal encephalitis (Dubey et al., 2000) because schizonts were not found in endothelial cells and the organism did not react to anti-*S. falcatula* antibody.

Our case was unusual in that it involved a bird that is considered to be pelagic when not breeding. Northern gannets breed on both sides of the northern Atlantic above 45°N and winter as far south as the equator (Carboneras, 1992). They plunge dive to forage on shoaling pelagic fish. Reports of *Sarcocystis* encephalitis in sea otters (*Ehdydra lutris nereis*) and harbor seals on the west coast of North America (Lapointe et al., 1998; Rosonke et al., 1999; Lindsay et al., 2000) indicate the intermediate host is not necessarily restrict-

ed to non-marine habitats. Harbor seals and sea otters both spend time on land and so could acquire infections there. There is also the possibility that these infections are associated with urban waste disposal in the marine environment. Gannets spend less time associated with terrestrial habitat than do otters and seals, and they consume live fish. This emaciated individual, with evidence of multiple diseases, may have become infected with *Sarcocystis* sp. at a coastal location, especially if it moved there because it was otherwise ill or weak. Alternatively, schools of pelagic fish may spend some time foraging in the mouths of rivers or estuaries and thus transport the parasite to more off-shore locations.

We thank M. Stage and V. Quelch from the St. John's Veterinary Clinic and Scott Terrell for bringing this case to our attention. Electron micrographs were prepared by the Electron Microscopy Core Laboratory of the Interdisciplinary Center for Biotechnology Research at the University of Florida. Comments were received from D. J. Forrester and M. A. Cheadle. This research was supported by the Florida Agricultural Experiment Station and a grant from the Florida Fish and Wildlife Conservation Commission and approved for publication as Journal Series No. R-08460.

#### LITERATURE CITED

- AGUILAR, R. F., D. P. SHAW, J. P. DUBEY, AND P. REDIG. 1991. *Sarcocystis*-associated encephalitis in an immature northern goshawk (*Accipiter gentilis atricapillus*). *Journal of Zoo and Wildlife Medicine* 22: 466–469.
- BOX, E. D., AND J. H. SMITH. 1982. The intermediate host spectrum in a *Sarcocystis* species of birds. *Journal of Parasitology* 68: 668–673.
- , J. L. MEIER, AND J. H. SMITH. 1984. Description of *Sarcocystis falcatula* Stile, 1893, a parasite of birds and opossums. *Journal of Protozoology* 31: 521–524.
- CARBONERAS, C. 1992. Family Sulidae (gannets and boobies). In *Handbook of the birds of the world*, Vol. 1, J. Del Hoyo, A. Elliott and J. Sargatal (eds.). Lynx Edicions, Barcelona, Spain, pp. 312–325.
- DAME, J. B., R. J. MACKAY, C. A. YOWELL, T. J. CUTLER, A. MARSH, AND E. C. GREINER. 1995. *Sar-*

- cocystis falcatula* from passerine and psittacine birds: Synonymy with *Sarcocystis neurona*, agent of equine protozoal myeloencephalitis. *Journal of Parasitology* 81: 930–935.
- DUBEY, J. P., S. L. PORTER, A. L. HATTELL, D. C. KRADEL, M. J. TOPPER, AND L. JOHNSON. 1991. Sarcocystosis-associated clinical encephalitis in a golden eagle (*Aquila chrysaetos*). *Journal of Zoo and Wildlife Medicine* 22: 233–236.
- , C. F. QUIST, AND D. L. FRITZ. 2000. Systemic sarcocystosis in a wild turkey from Georgia. *Journal of Wildlife Diseases* 36: 755–760.
- GENBANK. National Center for Biotechnology Information, National Library of Medicine, National Institutes of Health, [www.ncbi.nlm.nih.gov](http://www.ncbi.nlm.nih.gov).
- HILLYER, E. V., M. P. ANDERSON, E. C. GREINER, C. T. ATKINSON, AND J. K. FRENKEL. 1991. An outbreak of *Sarcocystis* in a collection of psittacines. *Journal of Zoo and Wildlife Medicine* 22: 434–445.
- JACOBSON, E. R., A. NICHOLSON, AND D. C. PAGE. 1984. *Sarcocystis* encephalitis in a cockatiel. *Journal of the American Veterinary Medical Association* 185: 904–906.
- LAPOINTE, J. M., P. J. DUIGNAN, A. E. MARSH, F. M. GULLAND, B. C. BARR, D. K. NAYDAN, D. P. KING, C. A. FARMAN, K. A. HUNTINGDON, AND L. J. LOWENSTINE. 1998. Meningoencephalitis due to a *Sarcocystis neurona*-like protozoan in Pacific harbor seals (*Phoca vitulina richardsi*). *Journal of Parasitology* 84: 1184–1189.
- LINDSAY, D. S., N. J. THOMAS, AND J. P. DUBEY. 2000. Biological characterisation of *Sarcocystis neurona* isolated from a southern sea otter (*Enhydra lutris nereis*). *International Journal for Parasitology* 30: 617–624.
- MUTALIB, A., R. KEIRS, W. MASLIN, M. TIPPER, AND J. P. DUBEY. 1995. *Sarcocystis*-associated encephalitis in chickens. *Avian Diseases* 39: 436–440.
- NEILL, P. J. G., J. H. SMITH, AND E. D. BOX. 1989. Pathogenesis of *Sarcocystis falcatula* (Apicomplexa: Sarcocystidae) in the budgerigar (*Melopsittacus undulatus*). IV. Ultrastructure of developing, mature and degenerating sarcocysts. *Journal of Protozoology* 36: 430–437.
- ROSENTHAL, B. M., D. S. LINDSAY, AND J. P. DUBEY. 2001. Relationships among *Sarcocystis* species transmitted by New World opossums (*Didelphis* spp.). *Veterinary Parasitology* 95: 133–142.
- ROSONKE, B. J., S. R. BROWN, S. J. TORNQUIST, S. P. SNYDER, M. M. GARNER, AND L. L. BLYTHE. 1999. Encephalomyelitis associated with *Sarcocystis neurona*-like organism in a sea otter. *Journal of the American Veterinary Medical Association* 215: 1839–1842.
- SIMPSON, C. F., AND D. J. FORRESTER. 1973. Electron microscopy of *Sarcocystis* sp.: Cyst wall, micropore, rhoptries, and an unidentified body. *International Journal for Parasitology* 3: 467–470.
- SPALDING, M. G., C. T. ATKINSON, AND R. E. CARLETON. 1994. *Sarcocystis* sp. in wading birds (Ciconiiformes) from Florida. *Journal of Wildlife Diseases* 30: 29–35.
- TANHAUSER, S. M., C. A. YOWELL, T. J. CUTLER, E. C. GREINER, R. J. MACKAY, AND J. B. DAME. 1999. Multiple DNA markers differentiate *Sarcocystis neurona* and *Sarcocystis falcatula*. *Journal of Parasitology* 85: 221–228.
- TEGLAS, M. B., S. E. LITTLE, K. S. LATIMER, AND J. P. DUBEY. 1998. *Sarcocystis*-associated encephalitis and myocarditis in a wild turkey (*Meleagris gallopavo*). *Journal of Parasitology* 84: 661–663.

*Received for publication 4 June 2001.*