



PARATUBERCULOSIS IN KEY DEER (ODOCOILEUS VIRGINIANUS CLAVIUM)

Authors: Quist, Charlotte F., Nettles, Victor F., Manning, Elizabeth J. B., Hall, D. Greg, Gaydos, Joseph K., et al.

Source: Journal of Wildlife Diseases, 38(4) : 729-737

Published By: Wildlife Disease Association

URL: <https://doi.org/10.7589/0090-3558-38.4.729>

BioOne Complete (complete.BioOne.org) is a full-text database of 200 subscribed and open-access titles in the biological, ecological, and environmental sciences published by nonprofit societies, associations, museums, institutions, and presses.

Your use of this PDF, the BioOne Complete website, and all posted and associated content indicates your acceptance of BioOne's Terms of Use, available at www.bioone.org/terms-of-use.

Usage of BioOne Complete content is strictly limited to personal, educational, and non - commercial use. Commercial inquiries or rights and permissions requests should be directed to the individual publisher as copyright holder.

BioOne sees sustainable scholarly publishing as an inherently collaborative enterprise connecting authors, nonprofit publishers, academic institutions, research libraries, and research funders in the common goal of maximizing access to critical research.

PARATUBERCULOSIS IN KEY DEER (*ODOCOILEUS VIRGINIANUS CLAVIUM*)

Charlotte F. Quist,^{1,5} Victor F. Nettles,^{1,5,6} Elizabeth J. B. Manning,² D. Greg Hall,³ Joseph K. Gaydos,¹ Tom J. Wilmers,⁴ and Roel R. Lopez⁴

¹ Southeastern Cooperative Wildlife Disease Study, College of Veterinary Medicine, The University of Georgia, Athens, Georgia 30602, USA

² Johne's Testing Center, School of Veterinary Medicine, University of Wisconsin, Madison, Wisconsin 53706, USA

³ Department of Pathology, College of Veterinary Medicine, The University of Georgia, Athens, Georgia 30602, USA

⁴ National Key Deer Refuge, US Fish and Wildlife Service, Big Pine Key, Florida 33043, USA

⁵ Current address: Wildlife Health Associates, Inc., P.O. Box 109, Dillon, Montana 59725, USA

⁶ Corresponding author (email: vn Nettles@3rivers.net)

ABSTRACT: Paratuberculosis was diagnosed in an endangered Key deer (*Odocoileus virginianus clavium*) in November 1996. Between 10 April 1997 and 28 September 2000, the Key deer population was monitored for infection with *Mycobacterium avium* subsp. *paratuberculosis* by necropsy of available carcasses ($n=170$), fecal cultures, and serology. One additional clinically affected Key deer was discovered in July 1998, and *M. avium* subsp. *paratuberculosis* was cultured from the feces of one live, asymptomatic deer. The results of this study provided sufficient evidence to consider the Key deer herd infected with *M. avium* subsp. *paratuberculosis* at very low prevalence.

Key words: Johne's disease, Key deer, *Mycobacterium avium* subsp. *paratuberculosis*, *Odocoileus virginianus clavium*, paratuberculosis.

INTRODUCTION

Paratuberculosis or Johne's disease, caused by infection with the acid-fast bacterium, *Mycobacterium avium* subsp. *paratuberculosis*, results in chronic enteritis, lymphadenitis, and emaciation in numerous free-ranging and domestic ruminant species (Clarke, 1997). Of the native free-ranging ruminant species in North America, clinical paratuberculosis has been reported in Rocky Mountain bighorn sheep (*Ovis canadensis*) (Williams et al., 1979), tule elk (*Cervus elaphus nannodes*; Jessup et al., 1981; Cook et al., 1997), and Rocky Mountain elk (*Cervus elaphus nelsoni*; Manning, unpubl. data). North American deer are known to be susceptible to the organism based on experimental infections of captive mule (*Odocoileus hemionus*) and white-tailed deer (*O. virginianus*) (Williams et al., 1983a,b). Natural infection has been reported in farmed elk (Manning et al., 1998). Additionally, presumptive diagnosis of paratuberculosis based on histopathology was reported in a 5 mo old captive white-tailed deer fawn that was taken from the wild at 3 days of age (Libke and Walton, 1975). However,

culture-confirmed infection in free-ranging white-tailed deer has been reported only once. Chiodini and Van Kruiningen (1983) cultured *M. avium* subsp. *paratuberculosis* from two of 10 free-ranging white-tailed deer that were present on a known infected cattle farm in Connecticut. These deer did not have lesions.

The Key deer (*Odocoileus virginianus clavium*) is an endangered subspecies of white-tailed deer present only on several islands known as "keys" in extreme southern Florida (USA). Hunting pressures in the early 1900s reduced the herd to an estimated 25–30 animals before the deer were protected by establishment of the National Key Deer Refuge (NKDR; 24°44', 81°20'W) in 1957 and the Endangered Species Act in 1967. By the 1980s, the herd increased to an estimated 250–300 animals. Population numbers continued to increase, and by the early 1970s there were an estimated 350–400 deer (Silvy, 1975; Klimstra et al., 1978).

As part of the comprehensive recovery program for Key deer, the US Fish and Wildlife Service has increased health monitoring of this species. In 1996, a diagnosis

of paratuberculosis was made in a Key deer (described herein). This article presents two field cases of clinical paratuberculosis in Key deer along with results of the ensuing epidemiologic investigation, including serologic and fecal culture data found in the Key deer herd from 10 April 1997 to 28 September 2000.

MATERIALS AND METHODS

Diagnostic investigations

Discovery of a probable case of paratuberculosis in a Key deer in 1996 caused increased vigilance for *M. avium* subsp. *paratuberculosis* infection through necropsy of Key deer killed by vehicles, euthanized because of terminal injuries or conditions, or found dead. Veterinarians and biologists with the Southeastern Cooperative Wildlife Disease Study (SCWDS; Athens, Georgia, USA) made eight site visits to the NKDR from 10 April 1997 to 28 September 2000, and necropsies were performed on 170 Key deer to determine causes of morbidity and mortality (Nettles et al., 2002). Because almost all Key deer carcasses were held frozen prior to examination, quality of these animals for *M. avium* subsp. *paratuberculosis* culture was marginal at best. Nevertheless, culture attempts were made on selected animals when emaciation, diarrhea, or both, were apparent. Routine bacterial cultures were conducted as previously reported (Nettles et al., 2002). Histopathology, including examination of slides stained with Kinyoun's acid-fast stain, was performed on sections of terminal ileum, ileocecal lymph node, and mesenteric lymph node of selected animals. All Key deer were examined on site except two dead deer that were shipped refrigerated to SCWDS.

If a suspect deer had acid-fast organisms within enteric tissues, the tissue was tested by IS900 polymerase chain reaction (PCR) test for *M. avium* subsp. *paratuberculosis* DNA. Genomic DNA was purified from fresh or formalin-fixed intestine and lymph node using the QIAamp tissue kit (QIAGEN Inc., Chatsworth, California, USA) and the manufacturer's suggested protocol. Briefly, 50 mg of finely minced tissue was transferred to 320 μ l of Qiagen lysis buffered AL with 720 μ g of proteinase K and incubated 2 hr at 55 C. This mixture was vortexed frequently. After 2 hr, 400 μ l of buffered AL was added and each sample incubated an additional 10 min at 70 C. Following three freeze-thaw cycles caused by immersion in liquid nitrogen, 430 μ l of 100% ethanol was added, the samples were vortexed, applied to

QIAamp spin columns, and DNA was eluted following the manufacturer's instructions. Quantities of genomic DNA eluted from spin columns were estimated by comparing the fluorescence of 1 μ l spots of purified DNA to that of DNA standards on 1% agarose gels containing 0.5 μ g/ml ethidium bromide (Sambrook et al., 1989).

For the diagnostic PCR, a 400 bp fragment of the *M. avium* subsp. *paratuberculosis* IS900 gene was amplified as previously described (Moss et al., 1992) with slight modifications to prevent carry-over contamination. Briefly, 50 μ l reactions were prepared in *Taq* polymerase buffer (50 mM KCl, 10 mM Tris-HCl pH 9.0, 0.1% Triton X-100, and 3.3 mM MgCl₂) with 0.6 mM P90 primer (5'-GAAGGGTGTTCGG-GGCCGTCGCTTAGG-3'); 0.6 μ M of 5'-biotinylated P91 primer (5'-GGCGTTGAGTTC-GATCGCCCACGTGAC-3'); 200 μ M each of dATP, dGTP, dCTP, and dTTP; 600 μ M dUTP; 250 μ g/ml bovine serum albumen (BSA); 1 unit uracil DNA glycosylase (UDG) (Boehringer-Mannheim Corporation, Indianapolis, Indiana, USA); and 2.5 units *Taq* DNA polymerase. Reactions were incubated 10 min at room temperature to allow UDG to degrade uracil-containing carry-over amplicons that might have contaminated the mix, then 3 min at 96 C for UDG inactivation followed by 40 thermal cycles (95 C for 1 min, 58 C for 1 min, and 72 C for 3 min) and a final 10 min incubation at 72 C. Ten μ l of amplification product were analyzed by agarose gel electrophoresis and ethidium bromide staining to demonstrate the presence or absence of the 500 bp IS900 amplicon.

Survey for infection by culture

Fecal samples were obtained from live-captured Key deer and, on a few occasions, Key deer carcasses. Additionally, fresh fecal samples were taken from the ground in areas where numerous Key deer were concentrated because of artificial feeding. These samples were submitted to the John's Testing Center, School of Veterinary Medicine, University of Wisconsin (Madison, Wisconsin, USA). Culture for *M. avium* subsp. *paratuberculosis* from feces or tissues (ileocecal lymph node, terminal ileum, or mesenteric lymph node) was conducted by a radiometric (BACTEC) technique described previously (Collins et al., 1990). The identities of mycobacterial isolates made through this technique were confirmed by both IS900 DNA PCR probe and mycobactin-dependent growth patterns.

Survey for infection by serology

Serum samples, obtained from the live captured Key deer were submitted to the Johne's Testing Center for testing by an adaptation of the *M. avium* subsp. *paratuberculosis* enzyme-linked immunosorbent assay (ELISA; IDEXX, Portland, Maine, USA) plus the agar gel immunodiffusion (AGID) test (ImmuCell Corp., Portland, Maine, USA). The AGID test and ELISA have been validated for cattle only; the ELISA conducted in this study was considered a prototype procedure for cervids. In a previous pilot study with the ELISA, it was determined that the ELISA's protein G based conjugate demonstrated binding characteristics for purified and concentrated serum IgG from elk comparable to that observed with purified and concentrated bovine IgG (Manning and Collins, 1999). Based on titration trials with elk serum, the Key deer serum was diluted 1:8 instead of 1:20 as outlined in the ELISA test kit instructions for bovine serum. Optical densities were obtained following manufacturer's instructions, and all samples were tested in duplicate. Enzyme-linked immunosorbent optical densities were assessed using the manufacturer's sample-to-positive (S/P) ratio interpretation method based on cervid serum controls. The positive control was a pool of serum with a high optical density from three ELISA and AGID positive adult elk in which infection had been confirmed by compatible clinical signs, histopathology, and isolation of *M. avium* subsp. *paratuberculosis* from multiple tissues. The negative control serum was a pool of low-density sera from free-ranging elk populations from the northwestern United States that had minimal contact with domestic livestock. Positive and negative bovine control sera were also run on each plate as assay validity controls.

RESULTS

Diagnostic investigations

Of 170 Key deer examined by necropsy, 21 were ranked in poor body condition (Stockle et al., 1978). However, health problems other than paratuberculosis were diagnosed in 19 of these animals as follows: haemonchosis ($n=6$); chronic purulent infections ($n=8$); malnutrition of fawns ($n=3$); enteric salmonellosis ($n=1$); and toxicosis ($n=1$).

The following two cases of paratuberculosis were diagnosed, one of which also had enteric salmonellosis:

Case 1: In November of 1996, a thin, 3-

4 yr old female Key deer was observed for several days in the yard of a residence on Big Pine Key, Florida. The landowner contacted NKDR officials and the doe was captured and transported to a local veterinarian for examination. Rectal body temperature was 38.3 C. The doe was emaciated, anemic, and had submandibular edema. The veterinarian initially suspected malnutrition, but radiographs suggested a possible obstruction of the digestive tract. The animal was treated with intravenous fluids for several hours but died before additional treatment could be initiated.

A field necropsy verified the submandibular edema and absence of body fat. Ascites and a pleural effusion also were present. No apparent intestinal blockage was found; however, the intestinal tract was dilated and an enlarged ileocecal lymph node was found. A presumptive diagnosis of haemonchosis was suggested based on information provided and previous health information from the deer herd. The abomasum was collected intact and frozen for later parasitologic examination. Sections of the distal small intestine, proximal colon, and ileocecal lymph nodes were placed in 10% buffered formalin and shipped to SCWDS for examination.

Haemonchus contortus parasites were not found in the abomasal contents of this doe. Grossly, formalin-fixed sections of intestine had mild patchy thickening of the mucosa. Sections of formalin-fixed lymph node and intestine were embedded in paraffin, sectioned at 5 μ m, and stained with hematoxylin and eosin. Histologically, the lymph node was effaced by sheets of epithelioid macrophages and numerous Langhans-type multinucleated cells. Several small mineralized foci also were present. Sections of intestine were autolyzed, but epithelioid macrophages were noted within the lamina propria and extending into the submucosa. Kinyoun's acid-fast stain revealed many intracellular acid-fast bacteria within numerous macrophages in the lymph node and intestine. A preliminary

diagnosis of paratuberculosis was made. Fresh tissues were not available from this animal for culture, but the 400 bp fragment of the IS900 gene sequence specific for *M. avium* subsp. *paratuberculosis* gene was amplified from formalin-fixed tissues by PCR, substantiating the diagnosis of paratuberculosis.

Case 2: In late May of 1998, a 2.5 yr old doe in poor body condition was seen at the same premises as Case 1. This deer was thin and had diarrhea. It was captured on 27 May 1998, fitted with a radiotelemetry unit; and a rectal swab, feces and blood sample were collected. The rectal swab yielded *Salmonella enterica* serotype *weltevreden* (group E-1). Radiometric culture of the feces was negative for *M. avium* subsp. *paratuberculosis*. Serum from the blood sample was AGID test negative for antibodies to *M. avium* subsp. *paratuberculosis*. The ELISA revealed an elevated S/P value (2.32). The animal's condition worsened and it was recaptured on 16 July 1998 and taken to a local veterinarian. Because of its progressively deteriorating condition, it was euthanized on 20 July 1998 and the carcass was shipped refrigerated to SCWDS for necropsy.

At necropsy, the deer was extremely emaciated with muscle wasting over the spine and pelvis. Dried fecal material stained the perineal area. The small intestine contained mucoid material throughout, and fibrin and necrotic debris were adhered to the jejunal mucosa. No appreciable thickening of the mucosa or enlargement of lymph nodes was noted. Fecal material in the small intestine, cecum, and rectum was watery.

Histologically, sections of small intestine showed expansion of the lamina propria by epithelioid macrophages interspersed with multifocal aggregates of lymphocytes and plasma cells. Eosinophils and giant cells were rare. Mesenteric lymph node contained sheets of epithelioid macrophages in afferent lymphatics and cortical sinuses. Acid-fast stains revealed a myriad of bacteria within the cytoplasm of macrophages

in the lymph node and in the lamina propria of the intestine. As in Case 1, PCR identified the organism as *M. avium* subsp. *paratuberculosis*. In addition, *S. enterica* serotype *kralendyl* was isolated at necropsy.

Serum, taken before euthanasia, and fresh tissues were submitted to the Johnes Testing Center for radiometric culture and serologic analysis. *Mycobacterium avium* subsp. *paratuberculosis* was cultured from ileocecal and mesenteric lymph nodes taken at necropsy though not from the ileum. Serum samples taken from this animal at its death were negative for antibodies to *M. avium* subsp. *paratuberculosis* using the AGID, but the ELISA again produced a high S/P result (2.78).

Survey of deer herd by culture

Isolation of *M. avium* subsp. *paratuberculosis* was attempted from feces collected per rectum at capture from 96 live Key deer, from feces collected at necropsy from the rectum from two dead Key deer (in addition to Case 2 described above), and from 44 fresh fecal samples obtained from the ground. Of the live Key deer surveyed, 95% were older than 1 yr. Cultures of 89 of the 96 fecal samples obtained from live Key deer were negative. Five samples were inconclusive due to contamination with other bacteria, *Mycobacterium scrofulaceum* was isolated from one, and one yielded *M. avium* subsp. *paratuberculosis*. Cultures of the feces from the two dead Key deer and 44 fecal samples from the ground were negative for *M. avium* subsp. *paratuberculosis*.

The Key deer from which *M. avium* subsp. *paratuberculosis* was cultured was an older adult male from approximately 10.5 km from where the two cases of paratuberculosis were found. The adult male was positive on culture from a fecal sample taken on 3 December 1999, but two subsequent fecal cultures (12 March and 8 May 2000) were negative. This deer was observed during the period and was alive but thin in March 2001.

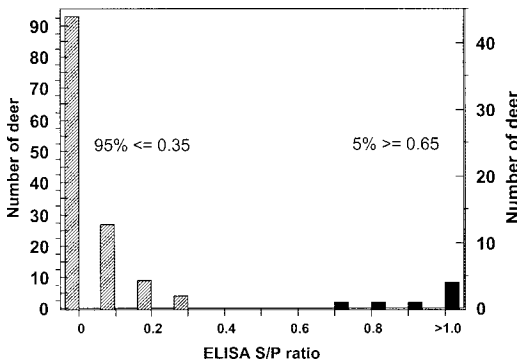


FIGURE 1. Results of prototype cervid ELISA performed on Key deer sera ($n=141$). The S/P ratios obtained by the prototype ELISA were bimodally distributed.

Survey of deer herd by serology

Agar gel immunodiffusion and ELISA tests were conducted on 145 samples that were believed to represent 142 different Key deer. There is a small possibility that a few deer captured before December 1998 might have been bled twice, because animals were not individually identified prior to release before that time. Of the Key deer bled, 82% were older than 1 yr. All AGID tests were negative. The S/P ratios obtained by the prototype cervid ELISA were bimodally distributed (Fig. 1). Ninety-three percent (132 serum samples) fell at or below an S/P ratio of 0.25 (the S/P cut-off ratio for cattle per kit instructions). Three (2%) deer had slightly higher S/P ratios between 0.28 and 0.32, and the remaining seven deer (5%) had S/P ratios ranging from 0.66 to 2.73. The highest S/P ratio was obtained from sera taken from Case 2. When first captured on 27 May 1988, this deer had an S/P ratio of 2.32; when euthanasia on 20 July 1998, the S/P ratio was 2.78. All seven deer with high S/P ratios were older than 1 yr, and six were older than 2 yr. The adult buck that was culture positive had a low S/P ratio (≤ 0.3) at all three bleedings.

In addition to the known infected deer, 18 other Key deer were sampled from the site where both clinically affected deer were discovered; all had S/P ratios < 0.25 .

Seventeen deer from the site where the adult buck was found were tested serologically. The three highest S/P ratios in these 17 deer were 0.28, 0.66, and 1.45, and each of these animals was fecal culture-negative at the time of bleeding. The deer infected with *M. scrofulaceum* had a low S/P ratio of 0.05.

DISCUSSION

The debilitated condition and gross lesions in the initial Key deer case were classic for paratuberculosis in ruminants, but the disease was considered unlikely at first because of the rarity of the infection in white-tailed deer. In contrast, paratuberculosis was suspected in the second case upon first presentation in May 1998. However, early diagnosis was confounded because the fecal culture and immunodiffusion tests for *M. avium* subsp. *paratuberculosis* were negative, and the recovery of *S. enterica* offered a plausible alternate explanation. Only high reactivity on the ELISA suggested paratuberculosis. However, in the brief period between 27 May and 20 July 1998, the disease progressed rapidly and multiple diagnostic tests were positive at necropsy. The presence of concurrent *Salmonella* infection in this deer probably contributed to the animal's rapid deterioration; however, post-mortem findings were typical for paratuberculosis.

Lesions of paratuberculosis in Key deer were comparable with cases of natural infection in red deer (*Cervus elaphus*) and previous experimental studies in white-tailed and mule deer (Williams et al., 1983a, b; Mackintosh et al., 1999). As was reported with the experimentally infected white-tailed deer, grossly visible thickening of the intestinal tract was not a prominent feature in our two naturally occurring cases of paratuberculosis in Key deer. While the lesions of paratuberculosis can vary among species, the relative mild intestinal thickening seen in these Key deer and experimentally infected mule and white-tailed deer resembles the lesions most commonly seen in sheep and goats, but is

in contrast to the marked intestinal thickening that has been seen with paratuberculosis in naturally infected elk (Manning et al., 1998), fallow deer (*Dama dama*; Stehman et al., 1995), and cattle (Barker et al., 1993). In the experimental infections conducted by Williams et al. (1983b) and as noted in this report, histologic sections of the lymph nodes and intestinal tract contained numerous acid-fast bacteria. Upon necropsy of experimentally infected deer, *M. avium* subsp. *paratuberculosis* was grown from multiple tissues (Williams et al., 1983a). Although there was only one Key deer case where fresh tissues were available, the organism was grown from both mesenteric and ileocecal lymph nodes but not from the ileum or fecal pellets taken from the rectum.

Based on limited observations, it appears that fecal shedding of *M. avium* subsp. *paratuberculosis* may be sporadic in North American deer and elk. This intermittent shedding pattern has been noted in most, if not all, infected ruminant species, especially in early phases of the disease (Manning and Collins, 2001). Only four of 55 deer fecal samples (species not given; Williams et al., 1985) and none of seven white-tailed deer fecal samples (Williams et al., 1983b) from experimentally infected animals were culture-positive, and the researchers concluded that fecal cultures were ineffective in detecting infection in deer. Only four of 95 fresh fecal samples from a known infected elk herd in California yielded positive cultures (Cook et al., 1997). Eight of 89 fecal samples from exotic axis deer (*Axis axis*) and fallow deer taken from a location near the elk were positive (Riemann et al., 1979). Unfortunately, fecal cultures were not done in the survey of 10 normal-appearing white-tailed deer in Connecticut where cultures were obtained from tissues of two animals (Chiodini and Van Kruiningen, 1983). However, in two naturally infected game-farmed elk herds with multiple clinical cases, heavy shedding (both frequency

and high numbers of organisms) was detected (Manning, unpubl. data).

The results of our fecal culture monitoring in Key deer indicated that environmental contamination with *M. avium* subsp. *paratuberculosis* was not occurring on a large scale. The most intensive culture sampling was done on the small herd of Key deer associated with the two clinical cases and no cultures were positive. Elsewhere on the Key, only one positive sample was obtained from a live Key deer, and two subsequent cultures on this animal were negative. Furthermore, this animal's health has not declined dramatically to date, although the deer has lost condition at a rate attributable to its increasing age. The positive culture from this deer could be interpreted in several ways. The animal could be truly infected, but an intermittent shedder, as is common in pre-clinical cases of Johne's disease in most species. Alternately, the organism cultured could have been ingested by the deer and passed through the alimentary tract (Collins, 1996). A third possibility is inadvertent contamination of the specimen in the field or at the laboratory.

The serologic data lend credence to the hypothesis that *M. avium* subsp. *paratuberculosis* is established in the Key deer population. The serology results cluster into two distinct groups with the largest sample (95%; 134) falling at or below an S/P value of 0.35. This S/P value represents the upper limit of S/P values for two wild cervid populations ($n=370$) believed to be free of exposure to *M. avium* subsp. *paratuberculosis* (Manning, unpubl. data). The other seven (5.0%) Key deer samples provided distinctly different results with S/P results greater than 0.65, two standard deviations from the mean.

Although informative for the sampled population, the serologic results cannot be interpreted as providing a certain diagnosis of Johne's disease for an individual animal. This is true for several reasons, one being that an ELISA interpretation cut-off (the sample-to-positive value that divides

test-positive from test-negative samples) has yet to be established for this species. Because an extensive evaluation of the infection status of both test-positive and test-negative Key deer has not been and may never be made, it is not possible to determine the cut-off and thus not possible to determine the antibody assay's sensitivity and specificity for these Key deer serum samples. Another caveat is the possibility of infection by another organism eliciting antibody that cross-reacts with the solid phase *M. avium* subsp. *paratuberculosis* antigens in an ELISA. This outcome has been reported for *M. avium* infection in red deer (Mackintosh et al., 1999) and for *Corynebacterium pseudotuberculosis* infection (i.e. caseous lymphadenitis) in goats (Stehman, 1996). However, none of the lesions in Key deer to date have given any indication of the presence of either infection, and, in general, *M. avium* and *C. pseudotuberculosis* are very rare in white-tailed deer (SCWDS, unpubl. data).

The AGID is believed to be less sensitive than ELISA in cattle (Sockette et al., 1992); thus, the fact that none of the deer serum samples were positive on the AGID is not surprising. The AGID assays have performed at least comparably if not with better specificity than the ELISA in sheep and goats (Stehman, 1996).

The combined data from this multifaceted approach of necropsy studies, culture, and serology have provided sufficient evidence for us to consider the Key deer herd infected with *M. avium* subsp. *paratuberculosis* at a low prevalence. Diagnostic procedures for paratuberculosis in cattle, which have been studied far more extensively than deer, are not highly sensitive in early phases of the infection (Collins, 1996). Furthermore, it has been suggested that for every clinical case of Johne's disease in dairy cattle managed under close contact husbandry protocols, as many as 25 additional cattle are infected (Whitlock and Buergelt, 1996). Whether such a guideline is appropriate for Key deer is unknown, but eventually it may be learned

that a smoldering infection without many cases of clinical disease could be a more typical scenario for paratuberculosis in cervids under free-ranging conditions. For example, subclinical infection was documented in tule elk 6 yr after the last clinical case was observed (Cook et al., 1997).

In domestic animals, transmission of *M. avium* subsp. *paratuberculosis* is enhanced by factors such as concentration of animals with resultant exposure of susceptible calves to contaminated feces, contaminated milk and water, low dietary intake, acid soils, stressors such as transport, parturition, lactation and, and immunosuppression (Thoen and Baum, 1988; Clarke, 1997). Essentially all published reports of clinical paratuberculosis in North American deer, elk, or moose (*Alces alces*) indicate the presence of factors such as confinement, high population density, close association with infected cattle, or nutritional stress (Soltys et al., 1967; Libke and Walton, 1975; Jessup et al., 1981; Gogan and Barrett, 1987; Manning and Collins, 1999). Equivalent risk factors of high deer population density, low nutritional quality of native habitat, and over-concentration of deer at artificial feeding sites were present in the Key deer population when clinical paratuberculosis was diagnosed. It also may be significant that both clinical cases were adult females that probably had been stressed by previous pregnancies. Furthermore, the two affected does were from the same small band.

The origin of the infection in these Key deer is enigmatic. No commercial livestock operations currently exist on the islands, though cattle were present in the early and mid-1900s. Feral swine occasionally are seen on outlying Keys and horses are present on the islands. Goats may be the most likely source of infection. A goat herd existed in the 1950s approximately 5 km from the location of the index case and horse owners occasionally maintain goats as stable companions. Conversation with a local veterinary practitioner revealed an observation of a "poor-doing" Nubian goat

on Ramrod Key in 1996. However, Ramrod Key is 7 km from the known infected Key deer, and Key deer are not found on Ramrod Key. Other wildlife also should be considered in the epidemiology as indicated by a recent study in Scotland where seven wild carnivorous mammal and three wild bird species were found to be infected (Beard et al., 2001). Endangered marsh rabbits (*Sylvilagus palustris hefneri*) are present in low numbers on Key deer habitat, but its status in regard to *M. avium* subsp. *paratuberculosis* is unstudied. Infection has been detected in wild European rabbits (*Oryctolagus cuniculus*) on farms with infected cattle in Scotland (Greig et al., 1997).

The presence of paratuberculosis in the Key deer herd, although unfortunate, could provide some interesting information on the epidemiology of *M. avium* subsp. *paratuberculosis* in regard to wild deer. Cattle are not present on the Lower Florida Keys, and much can be learned through continued monitoring about the capability of white-tailed deer to maintain *M. avium* subsp. *paratuberculosis* independent of cattle. This information could be important as control or eradication measures are increased on sympatric cattle and free-ranging deer herds in the United States.

ACKNOWLEDGMENTS

Support for this project was provided by a variety of sources including gifts from the Arcadia Wildlife Preserve, Inc.; US Fish and Wildlife Service, USDI, Cost-Share Challenge Grant 1448-40181-00-G-002; Biological Resources Division, USGS, USDI Grant Agreement 1445-GT09-96-0002; Cooperative Agreement Nos. 1998, 1999, 2000-9613-0032-CA, Veterinary Services, APHIS, USDA; and sponsorship of SCWDS by the fish and wildlife agencies of AL, AR, FL, GA, KY, LA, MD, MO, MS, PR, NC, SC, TN, VA, and WV. Our appreciation is offered to the former NKDR Managers, B. Steiglitz and J. Halpin, for their strong interest in Key deer health issues. In addition, we wish to thank the many biologists and technicians of both the NKDR and SCWDS for their valuable assistance.

LITERATURE CITED

- BARKER, I. K., A. A. VAN DREUMEL, AND N. PALMER. 1993. Mycobacterial enteritis: Paratuberculosis (Johne's disease). *In Pathology of domestic animals*, Vol. 2, 4th Edition, K. V. F. Judd, P. C. Kennedy and N. C. Palmer (eds.). Academic Press, Inc, San Diego, California, pp. 247-252.
- BEARD, P. M., M. J. DANIELS, D. HENDERSON, A. PIRIE, K. RUDGE, D. BUXTON, S. RHIND, A. GREIG, M. R. HUTCHINGS, I. MCKENDRICK, K. STEVENSON, AND J. M. SHARP. 2001. Paratuberculosis infection in nonruminant wildlife in Scotland. *Journal of Clinical Microbiology* 39: 1517-1521.
- CHIODINI, R. J., AND H. J. VAN KRUINGEN. 1983. Eastern white-tailed deer as a reservoir of ruminant paratuberculosis. *Journal of the American Veterinary Medical Association* 182: 168-169.
- CLARKE, C. J. 1997. The pathology and pathogenesis of paratuberculosis in ruminants and other species. *Journal of Comparative Pathology* 116: 217-261.
- COLLINS, M. T. 1996. Diagnosis of paratuberculosis. *Veterinary Clinics of North America: Food Animal Practice* 12: 357-371.
- , K. B. KENEFECK, D. C. SOCKETT, R. S. LAMBRECHT, J. McDONALD, AND J. B. JORGENSEN. 1990. Enhanced radiometric detection of *Mycobacterium paratuberculosis* using filter-concentrated bovine fecal specimens. *Journal of Clinical Microbiology* 28: 2514-2519.
- COOK, W. E., T. E. CORNISH, S. SHIDELER, B. LASLEY, AND M. T. COLLINS. 1997. Radiometric culture of *Mycobacterium avium paratuberculosis* from feces of Tule elk. *Journal of Wildlife Diseases* 33: 635-637.
- GOGAN, J. P., AND R. H. BARRETT. 1987. Comparative dynamics of introduced Tule elk populations. *Journal of Wildlife Management* 51: 20-27.
- GREIG, A., K. STEVENSON, V. PEREZ, A. A. PIRIE, J. M. GRANT, AND J. M. SHARP. 1997. Paratuberculosis in wild rabbits (*Oryctolagus cuniculus*). *The Veterinary Record* 140: 141-143.
- JESSUP, D. A., B. ABBAS, D. BEHYMER, AND P. GOGAN. 1981. Paratuberculosis in Tule elk in California. *Journal of the American Veterinary Medical Association* 179: 1252-1254.
- KLIMSTRA, W. D., J. W. HARDIN, AND N. J. SILVY. 1978. Population ecology of the Key deer. *In Research reports*, 1969, P. H. Oehser and J. S. Lea (eds.). National Geographic Society, Washington, D.C., pp 313-321.
- LIBKE, K. G., AND A. M. WALTON. 1975. Presumptive paratuberculosis in a Virginia white-tailed deer. *Journal of Wildlife Diseases* 11: 552-553.
- MACKINTOSH, C. G., M. P. REICHEL, J. F. T. GRIFFIN, H. MONTGOMERY, AND G. W. DELISLE. 1999. Paratuberculosis and avian tuberculosis in red deer in New Zealand: Clinical syndromes and diagnostic tests. *In Proceedings of the sixth inter-*

- national colloquium on paratuberculosis, E. J. B. Manning and M. T. Collins (eds.). International Association for Paratuberculosis, Madison, Wisconsin, pp. 449–457.
- MANNING, E. J. B., AND M. T. COLLINS. 1999. Johne's disease diagnosis for non-domestic hoofstock. Proceedings of the sixth international colloquium on paratuberculosis, E. J. B. Manning and M. T. Collins (eds.). International Association for Paratuberculosis, Madison, Wisconsin, pp. 458–461.
- , AND ———. 2001. *Mycobacterium avium* subspecies *paratuberculosis*: Pathogen, pathogenesis and diagnosis. In *Mycobacterial infections in domestic and wild animals*. Scientific and Technical Review 20: 133–150.
- , H. STEINBERG, K. ROSSOW, G. R. RUTH, AND M. T. COLLINS. 1998. Epizootic of paratuberculosis in farmed elk. *Journal of the American Veterinary Medical Association* 213: 1320–1322.
- MOSS, M. T., J. D. SANDERSON, M. L. V. TIZARD, J. HERMON-TAYLOR, F. A. K. EL-ZAATARI, C. D. MARKESICH, AND D. Y. GRAHAM. 1992. Polymerase chain reaction detection of *Mycobacterium paratuberculosis* and *Mycobacterium avium* subspecies *silvaticum* in long term cultures from Crohn's disease and control tissues. *Gut* 33: 1209–1213.
- NETTLES, V. F., C. F. QUIST, R. R. LOPEZ, T. J. WILMERS, P. FRANK, W. ROBERTS, S. CHITWOOD, AND W. R. DAVIDSON. 2002. Morbidity and mortality factors in Key deer, *Odocoileus virginianus clavium*. *Journal of Wildlife Diseases* 38: 685–692.
- RIEMANN, H., M. R. ZAMAN, R. RUPPANNER, O. AALUND, J. B. JORGENSEN, H. WORSAAE, AND D. BEHYMER. 1979. Paratuberculosis in cattle and free-living exotic deer. *Journal of the American Veterinary Medical Association* 174: 841–843.
- SAMBROOK, J., E. F. FRITSCH, AND T. MANIATIS. 1989. Appendix E. Commonly used techniques in molecular cloning. In *Molecular cloning. A laboratory manual*, 2nd Edition, J. Sambrook, E. F. Fritsch and T. Maniatis (eds.). Cold Spring Harbor Laboratory Press, New York, New York, pp. E.5–E.7.
- SILVY, N. J. 1975. Population density, movements, and habitat utilization of Key deer, *Odocoileus virginianus clavium*. Ph.D. Thesis, Southern Illinois University, Carbondale. Illinois, 152 pp.
- SOCKETT, D. C., T. A. CONRAD, C. B. THOMAS, AND M. T. COLLINS. 1992. Evaluation of four serological tests for bovine paratuberculosis. *Journal of Clinical Microbiology* 30: 1134–1139.
- SOLTYS, M. A., C. E. ANDRESS, AND A. L. FLETCH. 1967. Johne's disease in a moose (*Alces alces*). *Bulletin of the Wildlife Disease Association* 3: 183–184.
- STEHMAN, S. 1996. Paratuberculosis in small ruminants, deer, and South American camelids. *Veterinary Clinics of North America: Food Animal Practice* 12: 441–455.
- , S. M., C. R. ROSSITER, S. SHIN, AND D. H. LEIN. 1995. Severe paratuberculosis in a farmed fallow deer herd. Proceedings 38th annual meeting of the American Association of Veterinary Laboratory Diagnosticians, Sparks, Nevada. p. 44.
- STOCKLE, A. W., G. L. DOSTER, AND W. R. DAVIDSON. 1978. Endogenous fat as an indicator of physical condition of southeastern white-tailed deer. Proceedings Southeastern Association Fish and Wildlife Agencies 32: 269–279.
- THOEN, C. O., AND K. H. BAUM. 1988. Current knowledge on paratuberculosis. *Journal of the American Veterinary Medical Association* 11: 1609–1611.
- WHITLOCK, R. H., AND C. BUERGELT. 1996. Preclinical and clinical manifestations of paratuberculosis (including pathology). *Veterinary Clinics of North America: Food Animal Practice* 12: 345–356.
- WILLIAMS, E. S., J. C. DEMARTINI, AND S. P. SNYDER. 1985. Lymphocytes blastogenesis, complement fixation, and fecal culture as diagnostic tests for Paratuberculosis in North American wild ruminants and domestic sheep. *American Journal of Veterinary Research* 46: 2317–2321.
- , S. P. SNYDER, AND K. L. MARTIN. 1983a. Experimental infection of some North American wild ruminants and domestic sheep with *Mycobacterium paratuberculosis*: Clinical and bacteriological findings. *Journal of Wildlife Diseases* 19: 185–191.
- , ———, AND ———. 1983b. Pathology of spontaneous and experimental infection of North American wild ruminants with *Mycobacterium paratuberculosis*. *Veterinary Pathology* 20: 274–291.
- , T. R. SPRAKER, AND G. G. SCHOONVELD. 1979. Paratuberculosis (Johne's disease) in high-orn sheep and a Rocky Mountain goat in Colorado. *Journal of Wildlife Diseases* 15: 221–227.

Received for publication 30 October 2001.